

ORIGINAL ARTICLE

Physiologic [¹⁸F]fluorodeoxyglucose uptake of floor of mouth muscles in PET/CT imaging: a problem of body position during FDG uptake?

Stephan K. Haerle^a, Thomas F. Hany^b, Nader Ahmad^a, Irene Burger^b, Gerhard F. Huber^a, Daniel T. Schmid^b

^aDepartment of Otorhinolaryngology, Head and Neck Surgery, University Hospital Zurich, Frauenklinikstrasse 24, 8091 Zurich, Switzerland; ^bDepartment of Nuclear Medicine, University Hospital Zurich, Raemistrasse 100, 8091 Zurich, Switzerland

Corresponding address: Stephan K. Haerle, MD, Department of Otorhinolaryngology, Head and Neck Surgery, Frauenklinikstrasse 24, University Hospital Zurich, CH-8091 Zurich, Switzerland.

Email: stephan.haerle@usz.ch

Date accepted for publication 1 November 2013

Abstract

Objective: Assess the influence of 2 different patient positions during [¹⁸F]fluorodeoxyglucose (FDG) uptake phase on physiologic FDG accumulation of the floor of mouth (FOM) muscles. **Study design:** A prospective study design was used. **Methods:** Two hundred prospectively enrolled patients were included in the study: (a) head and neck cancer (HNC) patients in supine or (b) sitting position, (c) patients with other malignant tumours in supine or (d) sitting position. An intra-individual analysis was done on patients (b) and (d) when such scans were available. Maximum standardized uptake values without correction and corrected for blood pool activity were assessed. **Results:** The inter-individual analysis (sitting vs supine) revealed no significant differences ($P=0.17$ and $P=0.56$). The subgroup analysis on the patients with HNC ($P=0.56$ and $P=0.15$) and in patients with other malignancies ($P=0.14$ and $P=0.08$) revealed no significant difference; neither did the intra-individual analysis. **Conclusions:** The supine or sitting position during the uptake phase for FDG-positron emission tomography/computed tomography has no effect on the amount and distribution of physiologic FDG activity in the muscles of the FOM.

Keywords: ¹⁸F-FDG-PET/CT; body position; physiologic uptake; head and neck cancer; staging.

Introduction

The use of [¹⁸F]fluoro-2-deoxy-D-glucose (FDG)-positron emission tomography (PET)/computed tomography (CT) in the staging of head and neck cancer (HNC) has been widely described in the literature^[1–3]. Interpretation of FDG-PET/CT in the head and neck region can be quite challenging due to considerable variations in physiologic FDG uptake^[4]. Both physiologic and inflammatory uptake of the tonsils and of the lymphatic tissue of the Waldeyer ring are common findings. As far as we know, there is no trick to avoid or reduce this kind of potentially disturbing FDG uptake. In addition, it was our subjective impression that there would be increased physiologic uptake in the floor of mouth (FOM) muscles which could render difficulties

in interpreting FDG-PET/CT examinations in patients with malignant tumours of the head and neck.

The physiologic distribution of FDG of the FOM muscles and its variations needs to be known for adequate interpretation of FDG-PET/CT images. False-positive findings in cases of misinterpretation could reduce the cost-effectiveness of FDG-PET/CT and cause additional burden to the patients undergoing numerous diagnostic procedures to verify these findings. Combined FDG-PET/CT imaging compared with FDG-PET alone has already facilitated discrimination of physiologic and pathologic FDG uptake by allowing accurate anatomic localization of the FDG uptake^[5].

FDG uptake of skeletal muscles can be increased by physical stress after injection of FDG. One example is increased FDG uptake of the masseter muscle in patients

secondary to chewing gum^[6]. It is also accepted that the activity of intrinsic tongue muscles induced by chewing is considerable^[7], therefore the patients are urged not to chew during the FDG uptake phase. Furthermore, the direct correlation between muscular activity and increase in FDG uptake has been shown for the larynx after talking^[8]. To avoid unwanted FDG uptake of skeletal muscles, patients typically rest quietly in a supine position on a flat bed during the tracer uptake phase of 60 min as recommended in the European Association of Nuclear Medicine (EANM) guidelines for FDG-PET/CT imaging in HNC and other malignant tumours^[9]. Despite these measures, it is often not possible to avoid FOM muscle uptake. Our hypothesis was that the body position either has an impact on the overall forces or their relative distribution among the FOM muscles during deglutition and that this could potentially affect the amount of FDG accumulation in the FOM muscles. There are no published studies available investigating the influence of patient positioning (e.g. supine vs sitting) on the physiologic FDG uptake of the FOM muscles. Therefore, the aim of this study was to investigate the influence of 2 different patient positioning schemes on physiologic FDG uptake of the FOM before FDG-PET/CT scanning in patients with HNC and other malignancies.

Materials and methods

Patients

A total of 200 patients were enrolled in this prospective study. All patients referred for FDG-PET/CT for staging/restaging of HNC and other malignant tumours between June 2009 and March 2010 were asked to participate in this study. Each patient was assigned to 1 of 4 subgroups of 50 patients: (a) HNC with FDG uptake in supine position, (b) HNC with FDG uptake in sitting position, (c) other malignant tumour with FDG uptake in supine position and (d) other malignant tumour with FDG uptake in sitting position. Patients were asked before the FDG injection which position they preferred and were assigned to 1 of the 4 subgroups accordingly until the total number of patients in this group was reached. Patients were thereafter only included if they were willing to sit during FDG uptake to complete the number of patients in the remaining subgroups. The study protocol was approved by the local ethics committee and written informed consent was obtained from all patients before study entry.

The patient cohort in this study does not represent a consecutive group of all patients diagnosed with a particular malignancy within the given time frame because not all tumour stages qualify for FDG-PET/CT imaging at our institution.

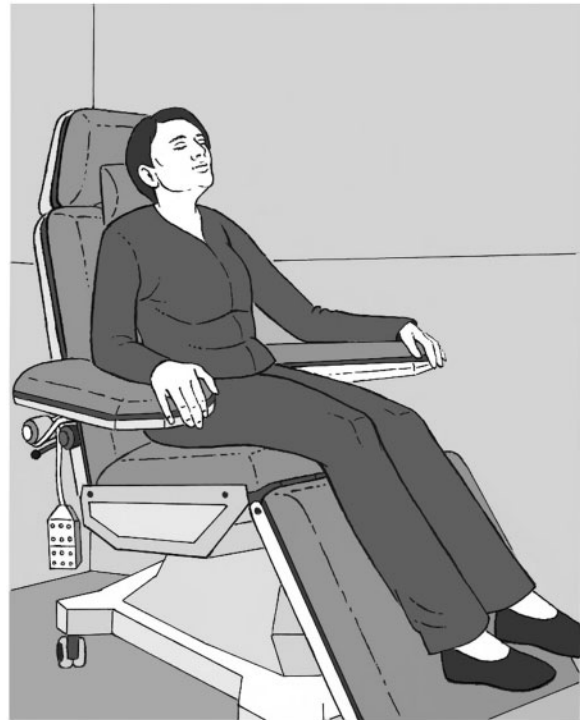

Figure 1 Sitting position on an armchair.

FDG injection and tracer uptake phase

Patients fasted for at least 4 h before the injection of a standard dose of approximately 350 MBq of FDG. An oral CT contrast agent (Micropaque Scanner, Guerbet AG, Aulnay-sous-bois, France) was given 15 min before FDG injection. Immediately after the injection, patients were transferred to a calm resting room with dimmed light. Each patient was either positioned in a sitting position on a comfortable armchair or in a supine position on a flat bed for 60 min (Figs. 1 and 2). Study patients were placed in specially set up uptake rooms just adjacent to the scanner room and repeatedly instructed and surveyed by the study physician. All patients were asked not to talk or chew during that time period.

FDG-PET/CT imaging protocol

All patients were examined on 1 of 2 combined PET/CT inline systems (Discovery STE or Discovery RX, GE Healthcare). First, a low-dose CT scan was acquired from the head to the pelvic floor using the following parameters: 140 kV, 40 mAs, 0.5 s/tube rotation, slice thickness of 4.25 mm. The CT scan was acquired during a breath hold in a normal expiratory position. Immediately after the CT acquisition, the PET emission scan was acquired covering the same scan range with either 180 s (Discovery STE, 3D mode) or 120 s (Discovery RX, 3D mode) emission time per cradle position with 7-slice overlap (matrix 128 × 128). A total of 7–9 cradle positions were scanned resulting in a total PET acquisition time of 14–21 min. The CT data were

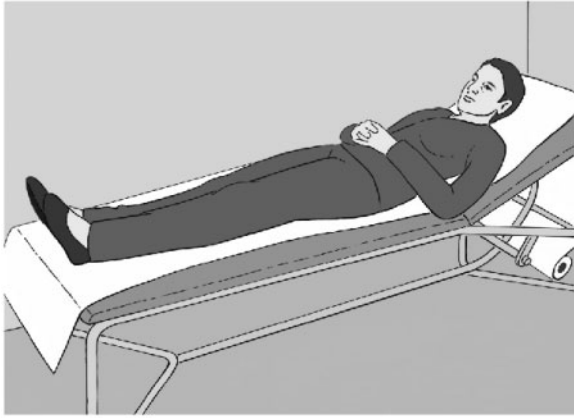


Figure 2 Supine position on a flat bed.

used for the attenuation correction and the images were reconstructed using a standard iterative algorithm (ordered subset expectation maximization).

Image analysis

All FDG-PET/CT images were analysed using a dedicated workstation (Advantage Workstation, version 4.4, GE Healthcare). FOM muscle uptake was assessed for the mylohyoid, digastric and geniohyoid muscles. In addition, the anterior part of the genioglossus muscle near its mandibular insertion was also evaluated. This extrinsic muscle of the tongue does not belong to the FOM muscle complex. However, the anterior/mandibular aspect is in close relation to the FOM muscles and FDG uptake to this part of the muscle can typically be distinguished from intrinsic muscle uptake of the tongue. Standardized uptake values (SUV_{max}) were assessed using volumes of interest (VOI). Individual VOIs were defined for each FDG-PET/CT scan for the FOM muscles. The hottest voxel was identified in the VOIs. Anatomic assignment of muscle uptake was obtained from the superimposed CT images. The muscle corresponding to the hottest voxel in the VOI of the FOM was determined. Average blood pool activity determined in a VOI in the descending aorta was subtracted from the SUV_{max} value for blood pool normalization (SUV_{cor}). SUV measurements of FOM muscles were assessed by one reader with board certification in both nuclear medicine and radiology and 8 years of experience in reading FDG-PET/CT (D.S.). The reader was blinded to the type of tumour and to the clinical history of the patient (e.g. previous surgery or radiotherapy). Both the corrected (SUV_{cor}) and uncorrected (SUV_{max}) values were used for statistical analysis. An intra-individual comparison with either a previous or a follow-up FDG-PET/CT scan acquired after FDG uptake in supine position (default protocol at our institution) was performed for patients examined after FDG uptake in sitting position. Such a scan was not available in all patients because this was not an inclusion criterion for this study.

Statistical analysis

Recorded data included patient positioning during uptake (sitting or supine), and SUV_{max} and SUV_{cor} of FOM muscles. Differences in measured SUV between the groups of patients examined after FDG uptake in sitting and supine positions were calculated by unpaired (inter-individual comparison) or paired (intra-individual comparison) The Student *t* test *P* values of less than 0.05 were considered significant. Bland–Altman plots were used to illustrate the differences in SUV (uptake in supine vs sitting position) in the intra-individual comparison. All statistical analyses were performed using SPSS 19 (SPSS Inc., Chicago, IL).

Results

Patients

A total of 200 patients were enrolled in this prospective study between June 2009 and March 2010. The female (59) to male (141) ratio was 1:2.4. The mean age was 59.3 years (range 18.1–88.8 years). In the HNC cohort, a total of 25 female and 75 male patients with a mean age of 61.4 years (range 22.3–88.8 years) were included. The cohort of patients with tumours other than HNC consisted of 34 women and 66 men with a mean age of 57.3 years (range 18.1–80.1 years).

Tumour characteristics

A total of 100 patients had HNC. These tumours were located in the oropharynx ($n = 49$), in the nose/sinuses/nasopharynx ($n = 12$), in the hypopharynx ($n = 9$), in the larynx ($n = 9$) or in the oral cavity ($n = 5$). Eight patients had primary tumours of the skin in the head and neck area, 6 had lymphoma, and 2 had malignant tumours of the major salivary glands. 23/100 patients were referred for initial tumour staging and 77/100 patients were referred for restaging. 24/100 HNC patients underwent either surgery or radiation affecting the floor of the mouth or tongue before the FDG-PET/CT examination.

The group of patients with non-HNC malignancies consisted of patients with malignant melanoma ($n = 32$), lung cancer ($n = 15$), breast cancer ($n = 11$), colon cancer ($n = 9$), lymphoma ($n = 9$), oesophageal cancer ($n = 7$), malignancies of the genitourinary system ($n = 6$), rectal cancer ($n = 3$), pleural mesothelioma ($n = 3$), primary malignant liver tumours ($n = 2$), stomach cancer ($n = 2$), and pancreatic cancer ($n = 1$). 27/100 patients were referred for initial tumour staging and 73/100 patients were referred for restaging. None of the non-HNC malignancies showed any metastases to the head and neck area, in particular to the FOM area.

Table 1 Inter-individual comparison of FDG uptake of the FOM muscles after tracer uptake phase in supine and sitting positions

Group	Parameter	Supine	Sitting	P value
All patients (<i>n</i> = 200)	SUV _{cor} (mean ± SD)	1.89 ± 1.32 ^a	1.98 ± 1.08 ^a	0.56*
	SUV _{max} (mean ± SD)	3.24 ± 1.35 ^a	3.48 ± 1.09 ^a	0.17*
HNC patients (<i>n</i> = 100)	SUV _{cor} (mean ± SD)	1.89 ± 1.33 ^b	1.99 ± 1.03 ^b	0.56*
	SUV _{max} (mean ± SD)	3.23 ± 1.41 ^b	3.49 ± 1.09 ^b	0.15*
Patients with non-HNC malignancies (<i>n</i> = 100)	SUV _{cor} (mean ± SD)	1.86 ± 1.32 ^b	2.21 ± 1.04 ^b	0.14*
	SUV _{max} (mean ± SD)	3.27 ± 1.30 ^b	3.70 ± 1.19 ^b	0.08*

SD, standard deviation.

^aRepresents a subgroup of 100 patients.

^bRepresents a subgroup of 50 patients.

*Unpaired Student *t* test, *P* values < 0.05 were considered significant.

Table 2 Intra-individual comparison of FDG uptake of the FOM muscles after tracer uptake phase in supine and sitting positions

Group	Parameter	Supine	Sitting	P value
All patients (<i>n</i> = 57)	SUV _{cor} (mean ± SD)	2.11 ± 1.29	2.08 ± 1.10	0.89*
	SUV _{max} (mean ± SD)	3.52 ± 1.31	3.59 ± 1.16	0.71*
HNC patients (<i>n</i> = 32)	SUV _{cor} (mean ± SD)	1.90 ± 1.30	1.79 ± 1.06	0.66*
	SUV _{max} (mean ± SD)	3.36 ± 1.27	3.25 ± 1.08	0.64*
Patients with non-HNC malignancies (<i>n</i> = 25)	SUV _{cor} (mean ± SD)	2.38 ± 1.27	2.464 ± 1.05	0.74*
	SUV _{max} (mean ± SD)	3.72 ± 1.36	4.03 ± 1.12	0.33*

*Paired Student *t* test, *P* values < 0.05 were considered significant.

SUV_{max} and SUV_{cor} characteristics

The inter-individual comparison of SUV_{cor} and SUV_{max} of the FOM muscles between the subgroups of patients examined after tracer uptake in the supine and sitting position, respectively did not reveal any statistically significant differences (Table 1).

In 57/100 patients examined after tracer uptake in the sitting position, an intra-individual comparison of SUV_{cor} and SUV_{max} with the most recent previous or follow-up FDG-PET/CT examination was performed. All examinations used for comparison were acquired after uptake in supine position according to the standard protocol at our institution. The median interval between the 2 examinations was 27 weeks (standard deviation ± 38 weeks, range 5–199 weeks). There were no significant differences found in these comparisons (Table 2).

Intra-individual differences in SUV_{cor} and SUV_{max} of the FOM muscles measured after tracer uptake in supine and sitting position, respectively, ranged from −3.1 to +3.8 (SUV_{cor}) and from −3.5 to +4.2 (SUV_{max}), respectively. Bland–Altman plots (Fig. 3) illustrate the distribution of the differences against the mean SUV. The differences in SUV_{max} between the examinations were within the upper and lower limits of 95% agreement in 48/57 patients (84.2%) with 5/57 (8.8%) above and 4/57 (7.0%) below the 95% agreement limits. Using SUV_{cor}, the values were 50/57 (87.7%), 4/57 (7.0%) and 3/57 (5.3%), respectively.

The analysis of distribution of the most intense FDG uptake among the different FOM muscles showed no

significant differences between the patients examined after uptake in supine and sitting positions, respectively (Table 3).

Discussion

In this study, we demonstrated that the maximum amount of physiologic FDG uptake of the FOM muscles does not differ between patients spending their tracer uptake phase in a quiet supine body position from those in a quiet sitting position.

In an intra-individual comparison of patients examined after tracer uptake in the sitting position with either a previous or follow-up FDG-PET/CT scan acquired after tracer uptake in the supine position, we demonstrated that there is no significant tendency towards higher or lower uptake rates. Anatomic structures with avid physiologic FDG uptake are more likely to hamper PET image interpretation than those with only mild uptake in daily practice. Therefore, one could ask whether such intense uptake could be affected by simple non-invasive factors such as different body positioning during the tracer uptake phase. Our results showed differences of more than 2 standard deviations from the mean SUV from the 2 examinations in 12–16% of patients. Even with a relatively low absolute number of such outliers (9 and 7, respectively), their distribution was similar, often above or below the upper and lower 95% agreement limits (Fig. 3). That points in the same direction as the other results that FOM muscle uptake cannot be affected by different body positioning.

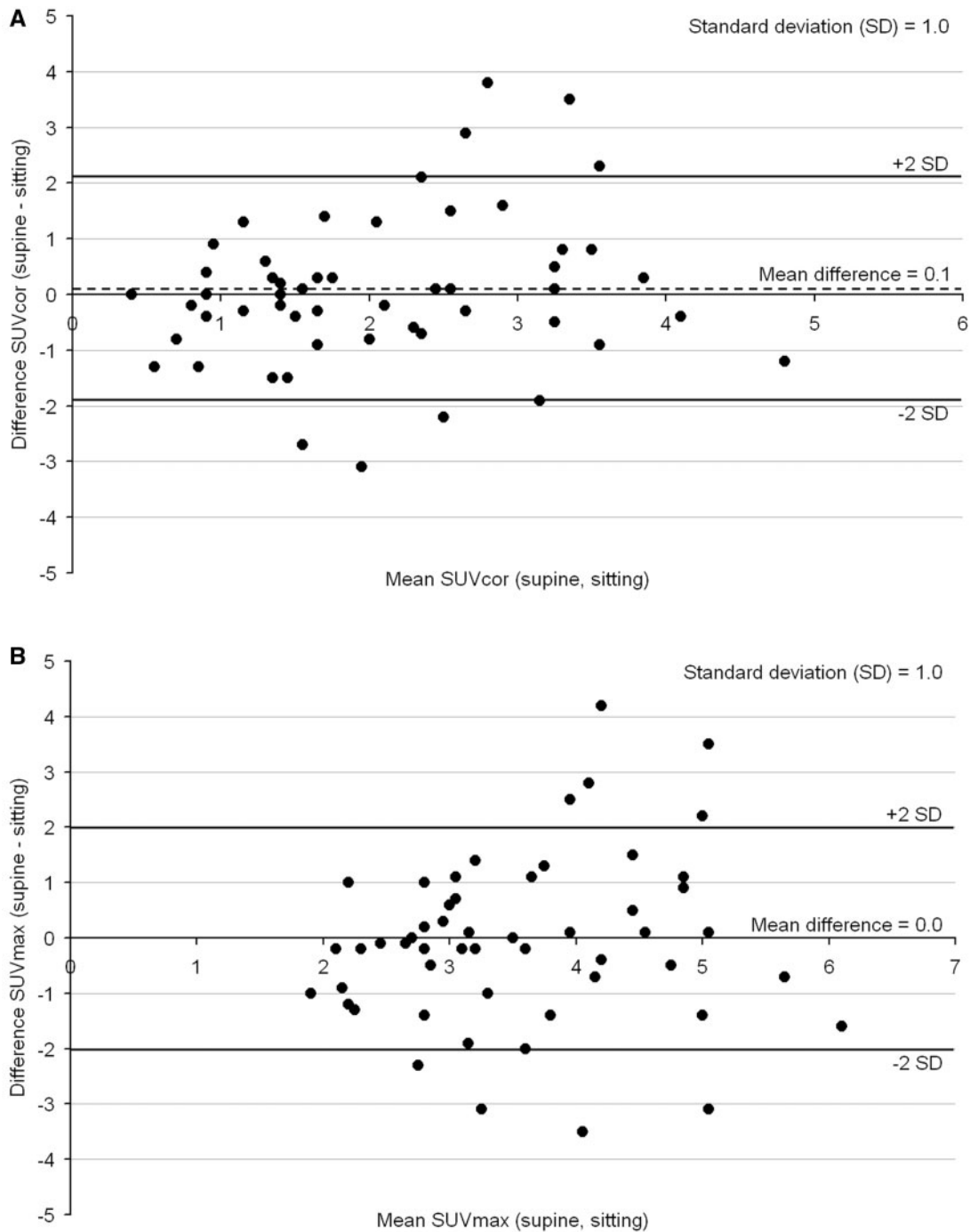


Figure 3 Bland–Altman plots for intra-individual agreement of SUV_{cor} (A) and SUV_{max} (B) of the FOM muscles after FDG uptake phase in supine and sitting positions. Differences between SUV after uptake in sitting and supine positions (vertical axis) are plotted against their mean (horizontal axis).

Furthermore, we showed that there is no significant difference regarding the distribution of the most intense uptake among the different muscles of the FOM after a tracer uptake phase in the supine or sitting position (Table 3).

Earlier published series reported on increased physiologic FDG uptake when chewing^[7], when using inadequate patient positioning^[10], or under local inflammatory

conditions^[11]. Usually the uptake phase is in supine position as recommended in the *EANM Procedure Guidelines for Tumor PET Imaging* [9]. Imaging studies using this approach have reported so-called physiologic uptake in the FOM and other muscles involving the head and neck region^[12,13]. In the worst case, this uptake can interfere with tumour-related FDG uptake and could potentially lead to an overestimation of the real tumour extent.

Table 3 Distribution of the most intense FDG uptake among the FOM muscles after tracer uptake phase in supine and sitting positions

Group	Parameter	Supine, <i>n</i> (%)	Sitting, <i>n</i> (%)	<i>P</i> value
All patients (<i>n</i> = 200)	M. digastricus	0 (0) ^a	1 (1) ^a	0.606*
	M. mylohyoideus	92 (92) ^a	94 (94) ^a	
	M. geniohyoideus	1 (1) ^a	1 (1) ^a	
	M. genioglossus ^c	7 (7) ^a	4 (4) ^a	
HNC patients (<i>n</i> = 100)	M. digastricus	0 (0) ^b	1 (2) ^b	0.064*
	M. mylohyoideus	44 (88) ^b	49 (98) ^b	
	M. geniohyoideus	1 (2) ^b	0 (0) ^b	
	M. genioglossus ^c	5 (10) ^b	0 (0) ^b	
Patients with non-HNC malignancies (<i>n</i> = 100)	M. digastricus	0 (0) ^b	0 (0) ^b	0.414*
	M. mylohyoideus	48 (96) ^b	45 (90) ^b	
	M. geniohyoideus	0 (0) ^b	1 (2) ^b	
	M. genioglossus ^c	2 (4) ^b	4 (8) ^b	

^aRepresents subgroup of 100 patients.

^bRepresents a subgroup of 50 patients.

^cOnly the anterior part of the muscle, close to the mandibular insertion (extrinsic muscle of the tongue).

*Chi-square test, *P* values < 0.05 were considered significant.

Therefore, reduction of physiologic uptake should intrinsically lead to improved diagnostic accuracy. Muscle uptake secondary to chewing or speaking during FDG uptake can be easily avoided in most cases by asking the patients not to chew or talk. However, these factors do not affect FOM muscle uptake as illustrated in this study.

We studied a different patient positioning setup for the FDG uptake phase. In general, the functional complex of FOM muscles is not likely to show major variations in FDG uptake among individual patients that could be explained by physical activity because these muscles are mainly used for phonation and swallowing. However, some anatomic variations, such as retrognathia or tooth prosthesis could potentially lead to a change in muscle interaction. Thus, we performed an intra-individual comparison between patients undergoing FDG-PET/CT imaging on 2 occasions (once after uptake in the supine position and once after uptake in the sitting position) to detect possible individual uptake patterns independent of positioning.

In patients with HNC, the FOM muscle activity may be disturbed either because of a tumour infiltrating the FOM or secondary to treatment of such tumours. 24% of patients with HNC underwent either surgery or radiation affecting the FOM or tongue before the FDG-PET/CT examination. One could argue that these patients should not be evaluated in a study focusing on physiologic FDG uptake to FOM muscles. Yet in this group of patients, knowledge of the amount and distribution of FOM muscle uptake is of particular interest. This is why we decided to include 50% of patients suffering from tumours of the head and neck. To take possible differences into account, these patients were evaluated both as a separate group and together with the other patients. All results from the patients with HNC are in line with the results of patients with other malignant tumours.

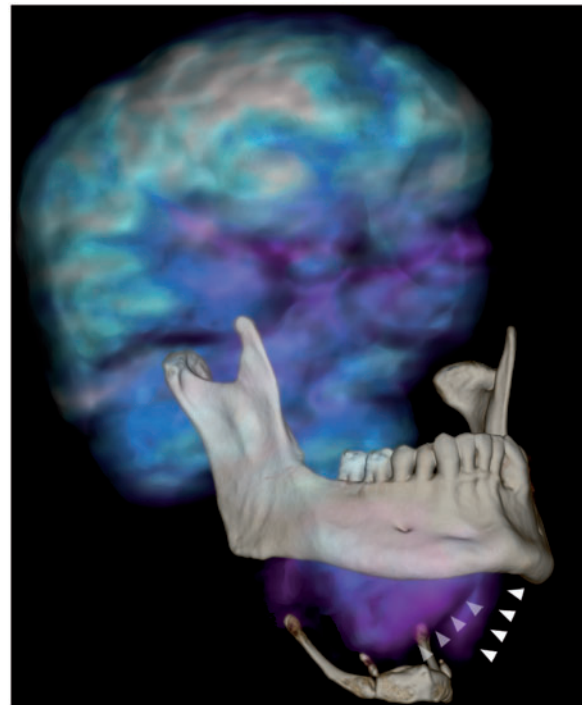


Figure 4 Combined three-dimensional volume rendering of FDG-PET and CT data illustrating bilateral, substantial physiologic uptake of the mylohyoid muscle (arrowheads).

Overall, the mylohyoid muscle was by far the most often affected muscle with physiologic FDG avidity in the FOM (92%/94%; supine/sitting) with similar frequencies in patients with HNC (88%/98%) and patients with other malignant tumours (90%/96%). The mylohyoid muscle plays an important role in the act of deglutition by elevating the hyoid bone (Fig. 4). Different from chewing or talking, the typically involuntary act of deglutition has to be continued during the FDG uptake phase. This is the most likely explanation for FDG accumulation

in the FOM muscles. Our hypothesis that the body position either has an impact on the overall forces or their relative distribution among the FOM muscles during deglutition was not reflected by the maximum amount of muscular FDG uptake in this study.

Conclusions

Supine or sitting patient positioning during the tracer uptake phase in FDG-PET/CT imaging has no impact on the amount and distribution of physiologic FDG activity in the muscles of the FOM. Therefore, if patients are not comfortable with the supine position for medical or functional reasons, a sitting position can be offered as an alternative. A sitting position during FDG uptake may be more convenient in particular for patients with difficulties in swallowing.

Acknowledgements

We are grateful to Ms M. Pirker for creating the drawings and to Josephine Trinckauf, Sabine Knoefel, Verena Weichselbaumer and Raji Kanagasabi for their excellent technical support.

Conflict of interest

The authors have no conflicts of interest to disclose.

References

- [1] Stoeckli SJ, Haerle SK, Strobel K, Haile SR, Hany TF, Schuknecht B. Initial staging of the neck in head and neck squamous cell carcinoma: a comparison of CT, PET/CT and ultrasound-guided fine-needle aspiration cytology. *Head Neck* 2012; 34: 469–476. doi:10.1002/hed.21764. PMID:21604319.
- [2] Strobel K, Haerle SK, Stoeckli SJ, et al. Head and neck squamous cell carcinoma (HNSCC) - detection of synchronous primaries with (18)F-FDG-PET/CT. *Eur J Nucl Med Mol Imaging* 2009; 36: 919–927. doi:10.1007/s00259-009-1064-6. PMID:19205699.
- [3] Hustinx R, Lucignani G. PET/CT in head and neck cancer: an update. *Eur J Nucl Med Mol Imaging* 2010; 37: 645–651. doi:10.1007/s00259-009-1365-9. PMID:20187296.
- [4] Nakamoto Y, Tatsumi M, Hammoud D, et al. Normal FDG distribution patterns in the head and neck: PET/CT evaluation. *Radiology* 2005; 234: 879–885. doi:10.1148/radiol.2343030301. PMID:15734938.
- [5] Bar-Shalom R, Gaitini D, Keidar Z, et al. Non-malignant FDG uptake in infradiaphragmatic adipose tissue: a new site of physiological tracer biodistribution characterised by PET/CT. *Eur J Nucl Med Mol Imaging* 2004; 31: 1105–1113. PMID:15007566.
- [6] Jackson RS, Schlarman TC, Hubble WL, Osman MM. Prevalence and patterns of physiologic muscle uptake detected with whole-body ¹⁸F-FDG PET. *J Nucl Med Technol* 2006; 34: 29–33. PMID:16517966.
- [7] Rikimaru H, Kikuchi M, Itoh M, et al. Mapping energy metabolism in jaw and tongue muscles during chewing. *J Dent Res* 2001; 80: 1849–1853. PMID:11926246.
- [8] Kamel EM, Goerres GW, Burger C, von Schulthess GK, Steinert HC. Recurrent laryngeal nerve palsy in patients with lung cancer: detection with PET-CT image fusion – report of six cases. *Radiology* 2002; 224: 153–156. doi:10.1148/radiol.2241011254. PMID:12091675.
- [9] Boellaard R, O'Doherty MJ, Weber WA, et al. FDG PET and PET/CT: EANM procedure guidelines for tumour PET imaging: version 1.0. *Eur J Nucl Med Mol Imaging* 2010; 37: 181–200. doi:10.1007/s00259-009-1297-4. PMID:19915839.
- [10] Beyer T, Tellmann L, Nickel I, et al. On the use of positioning aids to reduce misregistration in the head and neck in whole-body PET/CT studies. *J Nucl Med* 2005; 46: 596–602. PMID:15809481.
- [11] Wong RJ, Lin DT, Schöder H, et al. Diagnostic and prognostic value of [(18)F]fluorodeoxyglucose positron emission tomography for recurrent head and neck squamous cell carcinoma. *J Clin Oncol* 2002; 20: 4199–4208. doi:10.1200/JCO.2002.02.590. PMID:12377963.
- [12] Cohade C, Osman MM, Pannu HK, Wahl RL. Uptake in supraclavicular area fat (“USA-fat”): description on ¹⁸F-FDG PET/CT. *J Nucl Med* 2003; 44: 170–176. PMID:12571205.
- [13] Jackson RS, Schlarman TC, Hubble WL, Osman MM. Prevalence and patterns of physiologic muscle uptake detected with whole-body ¹⁸F-FDG PET. *J Nucl Med Technol* 2006; 34: 29–33. PMID:16517966.