

Demographic, Clinical Profile and Management Outcomes of Ocular Chemical Injuries in Saudi Children

Huda Al-Ghadeer¹, Mohammed Al Amry¹, Khalid A Aldihan²,
Omar S Alobaidan², Ghadah Mohammed S AlQahtani², Rajiv Khandekar³

¹Emergency Department, King Khaled Eye Specialist Hospital, Riyadh, Saudi Arabia; ²Ophthalmology Department, King Khaled Eye Specialist Hospital, Riyadh, Saudi Arabia; ³Research Department, King Khaled Eye Specialist Hospital, Riyadh, Saudi Arabia

Correspondence: Huda Al-Ghadeer, Emergency Department, King Khaled Eye Specialist Hospital, PO Box 7191, Riyadh, 11462, Saudi Arabia, Tel +966 1 4821234 ext. 2500, Email hghadeer@kkkesh.med.sa



Background: Eye injuries in children due to chemicals constitute a medical emergency since they result in severe ocular damage.

Objective: To determine the factors and management outcomes of chemical burns in the eyes of Saudi children. The study was performed at a tertiary eye center in the Kingdom of Saudi Arabia.

Methods: Children aged 16 years and under who had ocular chemical burns from 2009 to 2021 were enrolled in a single-armed cohort study. Data collection was done on patient demographics, injury type, and previous treatment. A modified Roper-Hall classification was used to grade the ocular injuries. The research study revealed the outcome to be best-corrected visual acuity (BCVA), one year after presentation and management.

Results: This study included 185 eyes from 147 children with chemical burns. The main profile of this study comprised the following categories: male (72.1%), grade 4 injury (27.6%), injury by acid (57.1%), burns at home (66%), and first aid was given to (35.4%) of the children. One year after treatment, there were 58 (31.4%) eyes with BCVA from 20/20 to 20/60, 31 cases (16.8%) with BCVA from 20/60 to 20/200, and 86 (46.5%) cases with severe visual impairment (SVI). Treatments included the release of symblepharon in 34 (18.4%) eyes and amniotic membrane transplantation (AMT) in 27 (14.6%) eyes. Poor visual outcomes were correlated with chemical burn severity (RR = 1.45, $P=0.04$). First aid administration ($P = 0.86$) and type of chemical (acid vs non-acid) ($P = 0.83$) did not differ significantly in association with SVI at the one-year follow-up.

Conclusion: Visual outcomes of chemical burns in children were not promising even after one year of treatment. Public health initiatives are critical to prevent chemical burns in mitigating the poor visual prognosis.

Keywords: burns, chemical, child, cornea, eye, injuries, stem cell

Introduction

Ocular emergencies due to chemical burns require immediate treatment.¹⁻³ It may have a catastrophic effect on a person's and quality of life.^{4,5} Its incidence varies from 1.25% to 4.4% in developing regions.^{6,7} These injuries account for 0.1–15% of all ophthalmic emergency visits.⁸ Jolly et al reported around 2397 visits to the children's trauma department, with 508 cases of eye injuries with incidents estimated at 21.1% (95% CI: 19.5–22.7%), in a duration of one year. Out of the 508 children with injuries to the eye, 52 cases reported were of chemical origin.⁹ Limbal stem cell deficiency (LSCD) is characterized by a loss or deficiency of the stem cells in the limbus that are essential for maintaining the function of the limbus barrier and for repopulating the corneal epithelium. The corneal epithelium cannot repair and regenerate itself when these stem cells are lost. This leads to epithelial breakdown and persistent epithelial defects, corneal conjunctivalization along with neovascularization, and scars in the cornea.¹⁰ Complications may arise due to chemical eye injuries,

including symblepharon and deformities of lid margin.^{1,3} Severe chemical burns can have irreversible consequences of vision loss and, in rare cases, loss of the whole eye. When ocular chemical injuries are treated immediately with irrigation and particle removal, it improves visual outcomes and decreases complications.^{11,12} Haring et al¹¹ reported a substantially higher risk of incurring chemical eye damage in patients with age one-two years than in patients in other ranges of age. In comparison to adults, chemical eye burns are more challenging in children due to the difficulties in early detection and adequate care of sequelae.^{13,14}

Although the epidemiology of ocular chemical burns in adults is well described, there are limited peer-reviewed publications on the presentations and management outcomes in children.^{15,16}

We describe the profile, etiology, and outcome of ocular chemical burns in children treated at a tertiary eye care center in central Saudi Arabia.

Materials and Methods

A one-armed retrospective cohort study was conducted in 2021–22. The research was approved by the Research Ethics Committee of the hospital. The study criteria included patients aged 16 years or under who were treated for chemical burns and sequelae between September 2009 and September 2021 at King Khaled Eye Specialist Hospital (KKESH), Riyadh, Saudi Arabia. KKESH is the leading referral center for ophthalmic specialties and sub-specialties in the Middle East.

All parents/guardians of the participants were provided with written informed consent with permission to publish. All participants' data were gathered, including age, sex, laterality (right, left, or both eyes), etiologies of chemical burns, accident location, and complications throughout follow-up. A thorough ocular examination was performed during the presentation and follow-up visits. A modified Roper-Hall classification scheme was used for grading ocular burns.¹³

In the acute stage, normal saline was used to clean the injured eye and remove any particles. For the first two to four weeks of treatment, patients with grade I and II ocular burns received topical antibiotics, corticosteroids, and cycloplegic eye drops. Additionally, preservative-free artificial eye drops were given in every one to two hours.

For grade III and IV burns, additional use of sodium ascorbate (10%) and sodium citrate (10%) ocular drops were given twice in one hour. Also, vitamin C was given orally, one to two grams each day, divided into four equal dosages for two to four weeks. Antiglaucoma drugs such as topical timolol maleate 0.5% eye drops and oral acetazolamide were also administered as needed. To expedite the epithelialization, amniotic membrane transplantation (AMT) was done with a cryopreserved amniotic membrane in acute stages using the overlay approach.¹⁷ If required, surgery was conducted for symblepharon release, allograft or autograft stem cell transplantation, and keratoplasty.

The Snellen chart or counting fingers was used to measure the uncorrected and best-corrected visual acuity (UCVA / BCVA), respectively at first presentation and during subsequent therapy.

A (BCVA) of 20/200 indicated a poor visual result, whereas a (BCVA) of 20/400 indicated unilateral blindness in the afflicted eye.

In our research, we used the vision impairment grades of the World Health Organization.¹⁸

Data were collected using Microsoft Office Excel 2010. The Statistical Package for Social Sciences (SPSS 25; IBM Corp., Armonk, NY, USA) was used to perform the univariate analysis. Normally distributed quantitative variables were used as the mean \pm standard deviation (SD). Qualitative variables were described in frequencies and percentage proportions. Student's *t*-test was performed with a two-sided *p*-value for subgroup analysis validation of continuous variables. *p*<0.05 was considered as statistically significant. The relative risk ratios (RR) with a 95% confidence interval (CI) were considered to be justified.

Results

The research investigated 185 eyes from 147 participants who were, on average, six years old (interquartile range 3.0; 11.0) (minimum one year and maximum 16 years). There were 106 (72.1%) males. Thirty-six (24.5%) patients experienced bilateral chemical burns.

Ocular burns due to acid were found in 84 (57.1%) patients, while alkalis and other chemicals were responsible for ocular burns in 63 (42.9%) patients.

Table 1 presents the details of causative agents, location of the ocular burn, and treatment prior to presenting at our institution. Two-thirds of patients had chemical burns at home. First aid was given at the site of the accident to one-third

Table 1 Chemicals Causing Ocular Burns and Treatment Before Arriving at Our Institution

		Number	Percentage
Cause of Ocular Chemical burns	Acids		
	Sulfurous acid [H ₂ SO ₃]	44	30
	Acetic acid [CH ₃ COOH]	17	11.5
	Hydrofluoric acid [HF]	12	8.2
	Sulfuric acid [H ₂ SO ₄]	9	6.1
	Hydrochloric acid [HCl]	2	1.4
Alkali	Lye [NaOH]	33	22.4
	Magnesium hydroxide [Mg(OH) ₂]	15	10.2
	Lime [Ca(OH) ₂]	10	6.8
	Potassium hydroxide [KOH]	5	3.4
Accident site	Home	97	66.0
	School	1	0.7
	Others	23	15.6
	Not documented	26	17.7
First aid given at site of accident	Yes	52	35.4
	No	89	60.5
	Not documented	6	4.1
Treated by ophthalmologist before referring	Yes	53	36
	No	88	59.9
	Not documented	6	4.1

of the patients. Ophthalmologists treated only 36% of patients before referring them to our institution. Figure 1 represents the proportion of eyes with different grades of chemical burns. Sixty percent of cases had eyes with grade I and II chemical burns. Table 2 presents the complications occurring one year after management. Corneal opacities, limbal stem

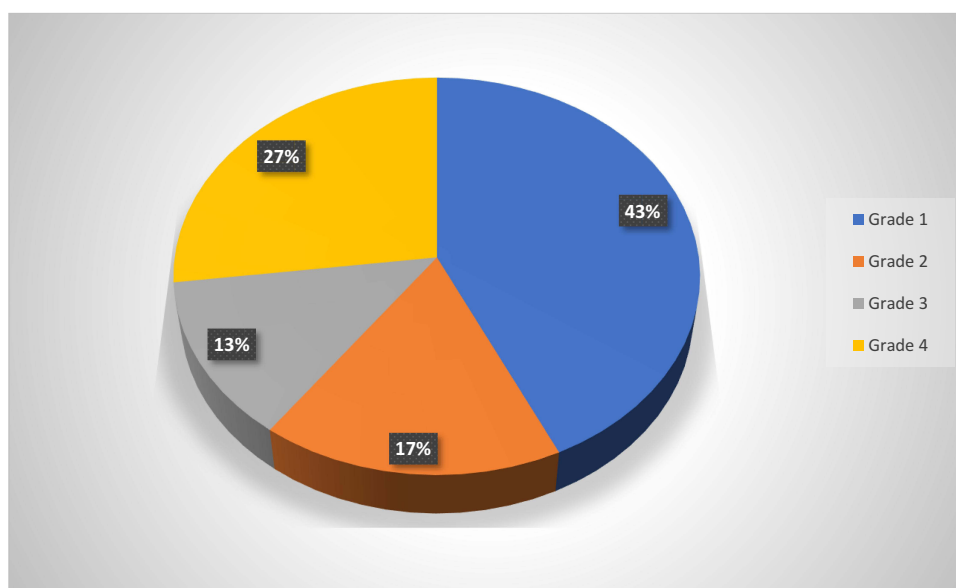
**Figure 1** Distribution of children with differing grades of ocular chemical burns (modified Roper-Hall classification) at presentation.

Table 2 Complications of Ocular Chemical Burns in Saudi Children

Complication	Number (%)
Corneal opacification	53 (28.7)
Limbal stem cell deficiency	41 (22.2)
Symblepharon	34 (18.4)
Entropion	13 (7.0)
Glaucoma	10 (5.4)
Phthisis bulbi	6 (3.2)

cell deficiency, and symblepharon were the main sequelae after chemical burns. [Figure 2](#). The surgical treatment of patients with chemical burns is summarized in [Table 3](#).

Symblepharon release and (AMT) were the most common procedures performed on the eyes with chemical burns. [Figure 3](#). [Table 4](#) compares the (BCVA) at presentation and one year after managing chemical burns in 185 eyes. The proportion of eyes with vision less than 20/400 reduced significantly after the one-year treatment of chemical burns.

Of the 110 eyes with grade I and II burns, 52 (47.3%) eyes were not blind, and 51 (46.4%) were blind. There were 75 eyes with grade III and IV chemical burns, where 24 (32%) eyes were not blind, and 45 (60%) were blind. The risk of blindness (BCVA) less than 20/200 after one year of management in eyes with grade III and IV burns was significantly higher than those with grades I and II burns. [RR = 1.45, (95% CI 1.0; 2.1) $P = 0.04$].

Among 120 eyes with acid burns, 55 (45.8%) had no severe visual impairment (SVI), while 61 (50.8%) had (SVI). Alkali burn cases were found in 58 eyes, out of which 20 (34.5%) had (SVI), and 24 (41.4%) were diagnosed with (SVI). Data on visual impairment were missing for four eyes in each group. One year after treating acid and non-acid burns, there was no difference in the risk of (SVI) [RR=0.94 (95% CI 0.57: 1.57) $P = 0.83$].

First aid received at the site of a chemical burn accident included 58 eyes, out of which 25 did not have (SVI), and 33 had (SVI) after one year. Of the 110 eyes that did not receive first aid in the burn accident, 49 did not have (SVI), and 61 had (SVI). One year after treatment, the risk of (SVI) was not significantly different between those who received first aid at the scene of the accident and those who did not [RR = 0.96, (95% CI 0.6; 1.5) $P = 0.86$].

Discussion

Our research study focussed on outcomes of ocular chemical burns in children over 12 years at a tertiary eye hospital. We observed that chemical burns occurred mainly at home. The main complications were corneal opacities, (LSCD), and symblepharon. The most common surgical procedures conducted were symblepharon release and (AMT). The outcomes of our study showed a decrease in the proportion of eyes with (SVI) after chemical burns, one year after management. The visual outcomes could be predicted by grading the chemical burns.

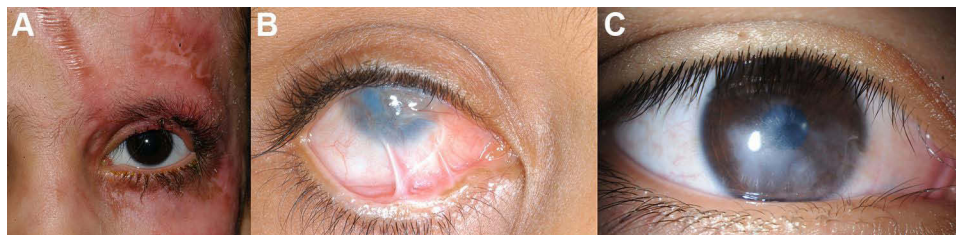

Figure 2 (A) External photo showing left side skin burn of a child as a result of a chemical burn. (B) Slit-lamp photo showing limbal stem deficiency with symblepharon formation secondary to a chemical burn. (C) Slit-lamp photo of the right eye revealing corneal opacity secondary to a chemical burn.

Table 3 Surgical Interventions in Saudi Children with Ocular Chemical Burns

Surgical Interventions	Number (%)
Symblepharon release	34 (18.4)
Amniotic membrane transplantation	27 (14.6)
Keratoplasty	23 (12.4)
Limbal stem cell transplantation	13 (7.0)

The study reported 12 children per year affected with chemical burns. The incidence ranges from 5.1 to 50 per 100,000 populations per year in the US.⁸ Most of the current research found in the literature involved either a small series of cases managed by specific surgical interventions such as (AMT),^{19,20} limbal epithelial transplant,^{21,22} or secondary keratoplasty.^{23,24} There were other studies reported which described the outcomes of burns caused by chemical agents.^{25,26}

Our study found a median age of six years. This contradicts to previous research that reported the majority of chemical eye burns in children aged one to three years.^{11,27}

Out of all cases, boys were accounted for 72.1%. According to data obtained from the USA²⁷ males were 58.8% of total patients who presented to the Emergency department (ED) after being injured by domestic cleaning chemicals. These conclusions were correlated to a more aggressive play among young boys.

Binocular injuries were recorded in 24.5% of patients in our study. Radosavljevic et al²⁸ found that binocular injuries occurred in 36.5% of patients, while Saini et al²⁹ reported 42.1% of patients with bilateral damage.

One of the most crucial reasons for grading chemical eye injuries is to predict the prognosis. Our cohort was graded using a modified Roper-Hall classification.¹³

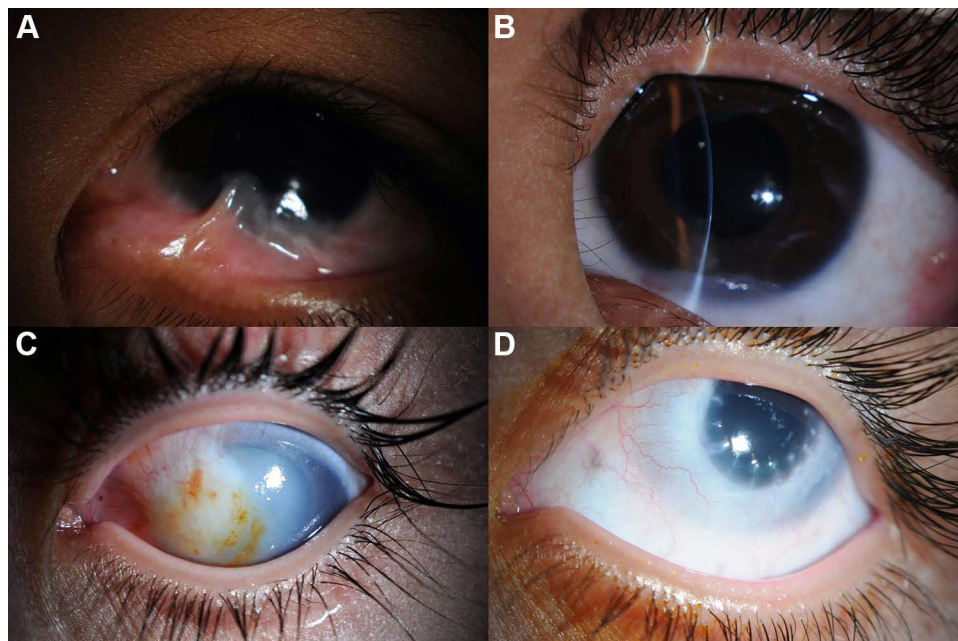


Figure 3 Slit-lamp photography showing (A) Symblepharon formation secondary to a chemical burn. (B) Following the release of symblepharon. (C) Diffuse corneal opacity following a chemical burn. (D) After limbal stem cell transplantation followed by penetrating keratoplasty with amniotic membrane transplant.

Table 4 Visual Impairment at Presentation and One Year After Managing Chemical Burns in Saudi Children

BCVA	At Presentation		One Year After Management		Validation
	Number	Percentage	Number	Percentage	
20/20 to 20/60	45	24.3	58	31.3	Chi-square = 5 Degree of freedom = 3 P = 0.02
20/60 to 20/200	25	13.5	31	16.8	
20/200 to 20/400	9	4.9	9	4.9	
Less than 20/400	100	54.1	77	41.6	
Missing	6	3.2	10	5.4	

Abbreviation: BCVA, best-corrected visual acuity.

In our study, a large number of cases with a mild and moderate grade of chemical burn reflected an impact of initial treatment in minimizing sequelae. We found that 40% of all chemical injuries were severe (grade III and IV) injuries, compared to 60.8% in one study.²⁸

In our study, the majority (66%) of chemical burns occurred at home. Similarly, a study from the United States reported 84.4% of chemical burns occurred at home.³⁰ Health education and advocating urgent action by caregivers need to be promoted through mass media and social media. Ocular burns require immediate attention as it is an emergent situation and the protocols for urgent care at primary eye care, ophthalmic units, and ocular surface departments should be standardized. Implementation of strict laws should be taken care for dispensing chemicals for home and school use with warnings and accountability in case of mishandling and carelessness. Acids cause tissue proteins to precipitate, that forms a barrier for further eye penetration.²⁸ The exceptions include sulphuric acid, hydrofluoric acid, and heavy metal acids. Acids have damaging properties to the eye, which includes inducing corneal scarring and vascularization, resulting in impaired vision.²⁸ Alternately, alkaline substances immediately react with the cellular lipids as they enter the cornea and form soaps.²⁸ They penetrate the anterior chamber and damage the tissues of the eye for several days. The penetration rate depends on the base type: ammonium hydroxide is the quickest base to penetrate the tissues; followed by, sodium hydroxide, potassium hydroxide, and calcium hydroxide.²⁸

Our study found acids in 57% of cases, with sulfurous acid being the most common cause of ocular chemical injuries. According to a large epidemiological study conducted in the United States, domestic cleaning agents are the most common chemical agents that causes ocular damage in children¹¹ The current study found no difference in the outcomes of chemical burns from acidic and non-acidic substances. In general, alkaline eye burns are often more severe than acidic burns.^{31,32}

Separate protocols for primary management, referral, and tertiary eye care management has been recommended based on the type of chemical. Irrigation of the eye is a crucial step in the treatment of chemical injuries. It significantly reduces the severity of chemical burns and also lowers the requirement for surgical treatment while improving final visual acuity.³³ Consequently, 60% of the children did not receive timely treatment at the injury time. Approximately one-third of the participants were given an immediate rinse at the time of the accident. Hence, a delayed onset was accounted due to the severity of the burn in our patients. Inclusion of the benefits of eye irrigation as an emergency procedure is recommended, both at Primary Health centers and nursing schools. Treatment for severe ocular chemical damage often takes time to restore visual acuity.

Chemical ocular burns can result in blindness due to corneal scar, which is difficult to treat with standard corneal grafts because of the significant limbal ischemia.^{4,20-24}

In our study, 52.4% of the patients needed surgical intervention. This is related to the extent of damage from chemical burns, which made it worse due to the delayed initial presentation. The most common surgical treatments in the current study were symblepharon release, (AMT), limbal stem cell transplantation (LSCT), and keratoplasty.

The complications found after one year of treatment in our research were corneal opacities, (LSCD), symblepharon, entropion, and high intraocular pressure. These outcomes are similar with Chinese, Indian and French studies.^{12,34,35}

Almost half of the eyes in our cohort had (SVI) one year after the management of chemical burns. Additionally, 5% of cases were lost to follow-up. This suggested a need for proactive follow-up of cases, proper counseling for long-term treatment, and more resources for future management and rehabilitation.

Our study showed a significantly higher risk of (SVI) in eyes with severe and moderate grades of chemical ocular burns. This again emphasized the role of grading in anticipating visual outcomes described in the literature.^{13,36}

In the current study, outcomes were assessed one year after management. We recommended long-term and even lifelong follow-up of these patients. Hence, risk factors and factors for visual prognosis could be assessed in the same cohort after 5 and 10 years of management.

However, this study had some limitations, including the retrospective nature of data analysis. Missing data from first assessment and cases lost to follow-up could have influenced the study's outcomes. Although a comparison study was conducted for outcomes among the subgroups of the type of chemical injury and the provision of first aid, the sample size was not calculated for this purpose. Hence, subgroup risk should be determined, with caution, and confirmed with studies having a larger sample of subgroups. Although the Roper-Hall classification defines a classic method, there are reports for using DUA³² or even the use of fluorescein and/or indocyanine green angiography, in addition to angio-OCT.^{37,38} Therefore, there is a need of more recent classifications to evaluate the outcomes of the current study, before comparing it with present literature.

Conclusions

Damage to ocular surface in children caused by chemical burns has long-term effects. Despite standard management, short-term visual outcomes are not encouraging. This leads to disappointment among patients and caregivers. Primary preventative measures to reduce the risk of ocular chemical damage in children involve the implementation of child-safe containers located in protected or out-of-reach drawers. It would minimize the severity of the injury and possibility of major sequelae.

Abbreviations

BCVA, Best Corrected Visual Acuity; SVI, Severe Visual Impairment; AMT, Amniotic Membrane Transplantation; LSCD, Limbal Stem Cell Deficiency; UCVA, Uncorrected Visual Acuity; SPSS, Statistical Package for Social Sciences; ED, Emergency Department; LSCT, Limbal Stem Cell Transplantation.

Ethical Statement

The study was authorized by the King Khaled Eye Specialist Hospital's local ethical board and followed the Helsinki Declaration's tenets. All participants' parents/guardians have provided written informed consent for their children to participate in this study.

Acknowledgment

We would like to thank Muneera Fahad Al Futais, the Clinical Research Coordinator, for her contribution to this research.

Author Contributions

All authors made a significant contribution to the work reported, whether that is in the conception, study design, execution, acquisition of data, analysis, and interpretation, or in all these areas; took part in drafting, revising or critically reviewing the article; gave final approval of the version to be published; have agreed on the journal to which the article has been submitted; and agree to be accountable for all aspects of the work.

Funding

This manuscript received no funding.

Disclosure

The authors declared no conflicts of interest in relation to this work and no financial interests in the submitted work have been reported by any of the authors.

References

- Sharma N, Kaur M, Agarwal T, et al. Treatment of acute ocular chemical burns. *Surv Ophthalmol*. 2018;63(2):214–235.
- Arnljots T, Samolov B. Kemiska ögonfrätskador – akut diagnostik och behandling - Omedelbar spolning är avgörande för att begränsa skadan [Emergency management of chemical eye burns]. *Lakartidningen*. 2018;115:FALM.
- Baradaran-Rafii A, Eslani M, Haq Z, et al. Current and upcoming therapies for ocular surface chemical injuries. *Ocul Surf*. 2017;15(1):48–64. doi:10.1016/j.jtos.2016.09.002
- Soleimani M, Naderan M. Management strategies of ocular chemical burns: current perspectives. *Clin Ophthalmol*. 2020;14:2687–2699.
- Singh P, Tyagi M, Kumar Y, et al. Ocular chemical injuries and their management. *Oman J Ophthalmol*. 2013;6(2):83–86. doi:10.4103/0974-620X.116624
- Le Q, Chen Y, Wang X, et al. Vision-related quality of life in patients with ocular chemical burns. *Invest Ophthalmol Vis Sci*. 2011;52(12):8951–8956.
- Xie Y, Tan Y, Tang S. Epidemiology of 377 patients with chemical burns in Guangdong province. *Burns*. 2004;30(6):569–572. doi:10.1016/j.burns.2004.01.028
- Ahmed AA, Ting DSJ, Figueiredo FC. Epidemiology, economic and humanistic burdens of ocular surface chemical injury: a narrative review. *Ocul Surf*. 2021;20:199–211. doi:10.1016/j.jtos.2021.02.006
- Jolly R, Arjunan M, Theodorou M, et al. Eye injuries in children—incidence and outcomes: an observational study at a dedicated children's eye casualty. *Eur J Ophthalmol*. 2019;29(5):499–503. doi:10.1177/1120672118803512
- Sangwan VS. Limbal stem cells in health and disease. *Biosci Rep*. 2001;21(4):385–405. doi:10.1023/A:1017935624867
- Haring RS, Sheffield ID, Channa R, et al. Epidemiologic trends of chemical ocular burns in the United States. *JAMA Ophthalmol*. 2016;134(10):1119–1124. doi:10.1001/jamaophthalmol.2016.2645
- Vajpayee RB, Shekhar H, Sharma N, et al. Demographic and clinical profile of ocular chemical injuries in the pediatric age group. *Ophthalmology*. 2014;121(1):377–380. doi:10.1016/j.ophtha.2013.06.044
- Bizrah M, Yusuf A, Ahmad S. An update on chemical eye burns. *Eye*. 2019;33(9):1362–1377. doi:10.1038/s41433-019-0456-5
- Lurati A. Occupational-related chemical injuries: a review of the literature. *Workplace Health Saf*. 2015;63(7):284–287. doi:10.1177/2165079915576924
- Merle H, Gérard M, Schrage N. Brûlures oculaires [Ocular burns]. *J Fr Ophtalmol*. 2008;31(7):723–734. doi:10.1016/S0181-5512(08)74391-2
- Ratnapalan S, Das L. Causes of eye burns in children. *Pediatr Emerg Care*. 2011;27(2):151–156. doi:10.1097/PEC.0b013e318209f08c
- Jirsova K, Jones GLA. Amniotic membrane in ophthalmology: properties, preparation, storage and indications for grafting—a review. *Cell Tissue Bank*. 2017;18(2):193–204. doi:10.1007/s10561-017-9618-5
- World Health Organization. International statistical classification of diseases and related health problems: tenth revision. Geneva; 1992.
- Dogan C, Arslan OS, Ozdamar A, et al. Efficacy of fixation of the amniotic membrane on a symblepharon ring with continuous suturing in acute ocular chemical burn patients. *Int Ophthalmol*. 2019;39(9):2103–2109. doi:10.1007/s10792-018-1049-1
- Eslani M, Baradaran-Rafii A, Cheung AY, et al. Amniotic membrane transplantation in acute severe ocular chemical injury: a randomized clinical trial. *Am J Ophthalmol*. 2019;199:209–215. doi:10.1016/j.ajo.2018.11.001
- Gupta N, Joshi J, Farooqui JH, et al. Results of simple limbal epithelial transplantation in unilateral ocular surface burn. *Indian J Ophthalmol*. 2018;66(1):45–52. doi:10.4103/ijo.IJO_602_17
- Agarwal S, Srinivasan B, Gupta R, et al. Allogenic simple limbal epithelial transplantation versus amniotic membrane grafting in the early management of severe-grade ocular chemical injuries—A retrospective comparative study. *Am J Ophthalmol*. 2020;217:297–304. doi:10.1016/j.ajo.2020.05.001
- Gupta N, Farooqui JH, Patel N, et al. Early results of penetrating keratoplasty in patients with unilateral chemical injury after simple limbal epithelial transplantation. *Cornea*. 2018;37(10):1249–1254. doi:10.1097/ICO.0000000000001681
- Singh D, Vanathi M, Gupta C, et al. Outcomes of deep anterior lamellar keratoplasty following autologous simple limbal epithelial transplant in pediatric unilateral severe chemical injury. *Indian J Ophthalmol*. 2017;65(3):217–222. doi:10.4103/ijo.IJO_880_16
- Wiesner N, Dutescu RM, Uthoff D, et al. First aid therapy for corrosive chemical eye burns: results of a 30-year longitudinal study with two different decontamination concepts. *Graefes Arch Clin Exp Ophthalmol*. 2019;257(8):1795–1803. doi:10.1007/s00417-019-04350-x
- Breazzano MP, Day HR Jr, Tanaka S, et al. Prospective analysis of pediatric ocular chemical burns: laundry detergent pods. *J AAPOS*. 2018;22(6):426–428. doi:10.1016/j.jaapos.2018.07.349
- D'Souza AL, Nelson NG, McKenzie LB. Pediatric burn injuries treated in US emergency departments between 1990 and 2006. *Pediatrics*. 2009;124(5):1424–1430. doi:10.1542/peds.2008-2802
- Radosavljević A, Kalezić T, Golubović S. The frequency of chemical injuries of the eye in a tertiary referral centre. *Srp Arh Celok Lek*. 2013;141(9–10):592–596. doi:10.2298/SARH1310592R
- Saini JS, Sharma A. Ocular chemical burns – clinical and demographic profile. *Burns*. 1993;19(1):67–69. doi:10.1016/0305-4179(93)90104-G
- Kersjes MP, Reifler DM, Maurer JR, et al. A review of chemical eye burns referred to the Blodgett regional poison center. *Vet Hum Toxicol*. 1987;29(6):453–455.
- Rao NK, Goldstein MH. Acid and alkali burns. In: *Ophthalmology E-Book*. Vol. 9. 2018:293.
- Said DG, Dua HS. Chemical burns acid or alkali, what's the difference? *Eye*. 2020;34(8):1299–1300. doi:10.1038/s41433-019-0735-1
- Kuckelkorn R, Kottek A, Schrage N, et al. Poor prognosis of severe chemical and thermal eye burns: the need for adequate emergency care and primary prevention. *Int Arch Occup Environ Health*. 1995;67(4):281–284. doi:10.1007/BF00409410
- Hong J, Qiu T, Wei A, et al. Clinical characteristics and visual outcome of severe ocular chemical injuries in Shanghai. *Ophthalmology*. 2010;117(12):2268–2272. doi:10.1016/j.ophtha.2010.03.050

35. Abayi DA, Mengome EM. Chemical eyelid and facial burn in a child: clinical course. *J Fr Ophthalmol.* 2020;43(9):974–978. doi:10.1016/j.jfo.2019.10.032
36. Wang F, Cheng J, Zhai H, et al. Correlation analysis of the clinical features and prognosis of acute ocular burns—exploration of a new classification scheme. *Graefes Arch Clin Exp Ophthalmol.* 2020;258(1):147–155. doi:10.1007/s00417-019-04525-6
37. Ang M, Foo V, Ke M, et al. Role of anterior segment optical coherence tomography angiography in assessing limbal vasculature in acute chemical injury of the eye. *Br J Ophthalmol.* 2022;106(9):1212–1216. doi:10.1136/bjophthalmol-2021-318847
38. Tey KY, Gan J, Foo V, et al. Role of anterior segment optical coherence tomography angiography in the assessment of acute chemical ocular injury: a pilot animal model study. *Sci Rep.* 2021;11(1):1–7. doi:10.1038/s41598-021-96086-0

Clinical Ophthalmology

Dovepress

Publish your work in this journal

Clinical Ophthalmology is an international, peer-reviewed journal covering all subspecialties within ophthalmology. Key topics include: Optometry; Visual science; Pharmacology and drug therapy in eye diseases; Basic Sciences; Primary and Secondary eye care; Patient Safety and Quality of Care Improvements. This journal is indexed on PubMed Central and CAS, and is the official journal of The Society of Clinical Ophthalmology (SCO). The manuscript management system is completely online and includes a very quick and fair peer-review system, which is all easy to use. Visit <http://www.dovepress.com/testimonials.php> to read real quotes from published authors.

Submit your manuscript here: <https://www.dovepress.com/clinical-ophthalmology-journal>