

Case report

Prolonged viral shedding in an immunocompetent patient with COVID-19

Anthony Michael McKie, Timothy Peter Wynne Jones , Catriona Sykes

Infectious Diseases, Monklands Hospital, Airdrie, UK

Correspondence to

Dr Anthony Michael McKie;
anthony.mckie@nhs.net

Accepted 14 September 2020

SUMMARY

We present a case of COVID-19 in an immunocompetent patient with risk factors for severe disease who recovered after prolonged swab positivity of 61 days postsymptom onset without significant respiratory and organ dysfunction. We discuss the reasons behind her prolonged swab positivity in the context of current SARS-CoV-2 knowledge, document the trend in her inflammatory response and swab results, and discuss the implications swab positivity had on her isolation and recovery.

BACKGROUND

The emergence of COVID-19 has become a significant public health concern for most nations. The isolation of infected and infective patients has been central to the response, but the duration of viral shedding remains unclear. Early data suggest that throat swab PCR may remain positive for 20 days,¹ however there is increasing evidence that some patients shed for significantly longer periods, particularly in faeces.² We present a case of a patient with no underlying immunosuppression due to illness or therapy, who remained throat swab positive after 61 days of symptoms.

CASE PRESENTATION

A 78-year-old white woman was hospitalised for increasing breathlessness and purulent sputum from her tracheostomy site over the preceding 14 days. Her medical history included hypertension, type 2 diabetes mellitus, tracheostomy following complications of thyroidectomy 23 years ago, atrial fibrillation, peripheral vascular disease and myocardial infarction treated with coronary bypass graft. She does not drink alcohol and is an ex-smoker from 23 years ago. On admission her body mass index was 34.2. Prior to admission she lived alone with home care and family support. She used walking aids around her own home but required a wheelchair for going outside.

On day 14 after symptom onset, the patient was admitted with a positive PCR test for SARS-CoV-2 on nasopharyngeal swab specimen. Her white cell count revealed a lymphopenia ($0.7 \times 10^9/L$), normal C reactive protein ($<6 \text{ mg/L}$) and normal lactate and lactate dehydrogenase levels. Her thyroid function was within normal range. A chest radiograph

revealed left-sided consolidation. She was given oral antibiotic therapy and treated on a further two occasions for hospital-acquired pneumonia although sputum, blood and urine cultures were negative throughout her admission. Complement and immunoglobulin levels were normal, and she had a negative serology for HIV. Chest radiographs completed on days 5, 12, 21, 36 and 53 of admission all displayed bilateral basal air space shadowing. Supplemental oxygen to maintain adequate saturations was administered per tracheostomy mask and never exceeded 8 L/min, and she did not require positive pressure ventilation or intubation. She was treated with regular sodium chloride nebulisers and carbocysteine for tracheostomy secretion clearance. Antibiotic therapy during her admission did not appear to significantly improve her clinical picture. She obtained no immunomodulatory therapies or experimental/trial therapies. She was anticoagulated for her atrial fibrillation and did not receive heparin treatment. The course of her inflammatory response, antibiotic therapy and SARS-CoV-2 results are documented in [figure 1](#).

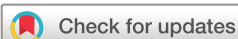On the sixty-first day after symptom onset she tested negative for SARS-CoV-2 and remained so on two repeat swabs. This allowed enhanced social contact with limited family visitation and coincided with marked improvement.

TREATMENT

Our patient required frequent tracheal suctioning necessitating the use of full personal protective equipment (PPE) throughout her period of SARS-CoV-2 positivity. She was treated for presumed hospital-acquired infection on two occasions. Her isolation precipitated significant psychological decline and detriment to her nutrition—she lost 15% of her body weight during admission. Her mobility and belief in her recovery declined despite no observable deterioration in physiological parameters or organ function. Her condition was affected by a mild fluctuating delirium, leading to an inability to use video communications and to recognise visiting family members dressed in full PPE.

OUTCOME AND FOLLOW-UP

She was subsequently discharged 55 days after her initial presentation. A follow-up telephone call 1 week following discharge revealed the patient was physically recovering but experiencing



© BMJ Publishing Group Limited 2020. No commercial re-use. See rights and permissions. Published by BMJ.

To cite: McKie AM, Jones TPW, Sykes C. *BMJ Case Rep* 2020;**13**:e237357. doi:10.1136/bcr-2020-237357

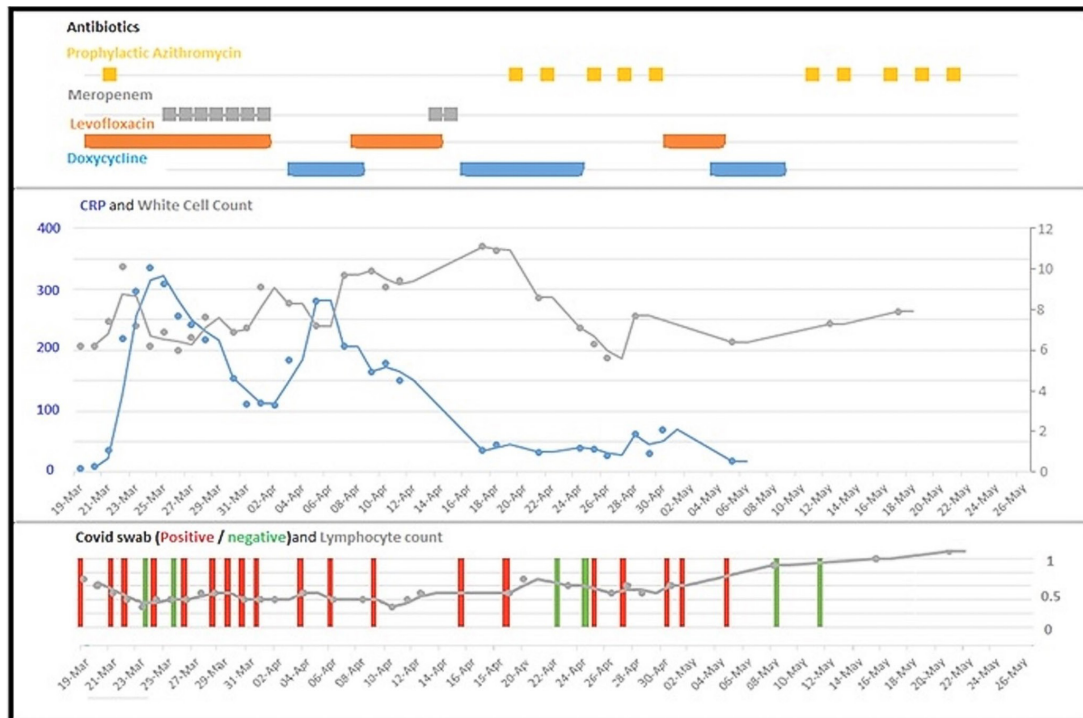


Figure 1 Timeline of antibiotic therapy, inflammatory markers, lymphocyte count and COVID-19 swab results. CRP, C reactive protein.

significant emotional distress. She described poor sleep, nightmares, hallucinations of ‘people in masks’, with significant anxiety if left alone, and had become apathetic towards her previously independent tracheostomy care. Three weeks postdischarge she was readmitted with difficulties in her self-care and is being assessed for placement in a residential care home.

DISCUSSION

To our knowledge this case is the longest reported duration of viral shedding in COVID-19 in an immunocompetent patient. While the majority of patients infected with SARS-CoV-2 suffer only a mild illness, a significant proportion of patients require admission for supplementary oxygen therapy. Of those hospitalised, 17% become critically unwell and have a mean duration of viral shedding of 20 days.³ Patients who are immunocompromised or immunodeficient experience a prolonged period of viral shedding in other respiratory viral infections^{4,5} but experience in COVID-19 is more limited. A recent case series in renal transplant suggest that this is also the case in SARS-CoV-2,^{6,7} and other individual case reports have detailed patients with a prolonged viral shedding.^{8,9} These cases have been complicated by treatment with immunomodulatory agents during the acute infection. At the time of admission of our patient, the role of steroids in the acute treatment of COVID-19 remained controversial as there were concerns about the effect of such medications on the duration of viral shedding.¹⁰ It remains possible therefore that these early treatments adversely affected shedding time. Our patient received no immunosuppressive medications at any point in her illness. Preliminary findings from the Recovery Trial have shown a proven benefit in hospitalised patients with COVID-19 that require supplementary oxygen or mechanical ventilatory support, with a lowering of 28-day mortality, and lowering of duration of hospital admission.¹¹ This was not known at the time of the patient’s

treatment and would have formed the standard of care. We could find no clear reason to explain the prolonged period of viral shedding in this patient. Although the presence of a tracheostomy was unusual, we found no published evidence of an increased duration for COVID-19 or other viral infections in the literature. The immune response to SARS-CoV-2 remains poorly understood, it remains credible that differing host immunotypes may play a part in the wide spectrum and duration of disease seen in cases of COVID-19.¹²

It is well understood that positive PCR tests do not necessarily equate to evidence of viable virus, but the relationship between prolonged shedding and infectiousness remains unclear. Recent cohort studies on nasopharyngeal samples in SARS-CoV-2 suggest the highest viral load is found in the presymptomatic period of infection, peaking at 0.7 days prior to symptom onset and significantly reducing by day 7.¹³ Viral culture studies found that viable virus is not present in throat swabs beyond day 8 of symptoms despite high viral PCR loads on swabs.^{14–16} These are small sample studies of well middle-aged individuals and it is difficult to interpret if this is true in all populations.

Our patient’s case was complicated by the presence of her tracheostomy from which viral swabs were taken. It is not clear whether viral shedding in COVID-19 is prolonged in patients with tracheostomy, however such samples are likely to constitute sampling from deeper parts of respiratory tract where samples are more likely to be PCR-positive than nasopharyngeal swabs.^{15,17} The use of such data on interpretation of infectivity of a patient remains difficult. Issues with sensitivity of viral culture processes as well as an understanding that the number of viable virions needed for infection *in vivo* is likely to be lower than *in vitro* has hampered the interpretation of duration of infectivity.¹⁸

Prolonged swab positivity in our patient and repeated suctioning of her tracheal secretions had significant implications on our patient’s care. Due to the limited data available at

Patient's perspective

- ▶ The 10 weeks our mum was in hospital was really hard for us all as a family, we felt helpless not getting in to see mum for ourselves even just to hold her hand and tell her we loved her. We will be forever grateful that we were allowed in for an hour a day for 2 weeks near the end of her stay as the difference in her general mood and state of confusion definitely improved once our visits started as did her eating which had been a huge concern. Mum felt she was in a prison with no means of escape from a nightmare situation and she had terrible nightmares and hallucinations which she still remembers and is still struggling with.
- ▶ The isolation room that was necessary due to mum testing positive for so long has had a very severe long-lasting effect on our mum's state of mind and mental health. We understand the reasons behind it of course but in all honesty we were totally unprepared for the terrible toll it had taken on our mum and we all struggled really badly when we got mum home to try and get her to feel safe and secure in her house and this in the end proved to be something we were unable to.
- ▶ We feel testing negative for COVID-19 was just the start of mum's battle with this disease; what has been left behind is going to take a long long time for her and us as a family to recover from. Much more needs to be looked into regarding rehabilitation for patients with long-term COVID-19 and their families.

the time surrounding the infectiousness of this patient, it was felt necessary for staff to wear full PPE to enter her negative pressure room. Prolonged isolation and limited contact with the healthcare team, and isolation from her family significantly impacted her mood, nutrition, mobility and psychological well-being. Greater certainty on the viability of viral material in patients with prolonged shedding would have mitigated many challenges in our patient's care. Relaxation of her isolation and reduced PPE requirements of attending staff and even visiting family would have facilitated earlier and enhanced multidisciplinary care.

Delirium in the context of COVID-19 is well documented and there is a need for realistic solutions that optimise patient care, while mitigating against the risk of transmission.¹⁹ Traditional approaches to delirium management were severely impaired by the limitations enforced by full PPE usage for tracheostomy care.

Our patient also reported significant ongoing psychological distress after discharge. There are currently limited data on the psychological impact for patients of the COVID-19 pandemic, but experience from similar coronavirus outbreaks seen with Severe Acute Respiratory Syndrome (SARS) in SARS-CoV-1 virus and Middle East Respiratory Syndrome (MERS) in MERS-CoV virus suggest significantly increased rates of anxiety and depression in survivors,^{20 21} while a significant proportion of patients develop post-traumatic stress disorder (PTSD).²² Isolation during the epidemics alone was also associated with PTSD and anxiety, with increased duration of isolation increasing risk.²³ There is a complex interplay between COVID-19 disease, isolation and mental health, and we need to better understand causation and mitigate its effect.

We report a case of prolonged viral shedding in a patient with COVID-19. This case provides evidence that immunocompetent individuals may have a prolonged period of viral shedding. There is a need to understand the risk of transmission in such patients, as this has significant implications on an individual's mental health and the wider public health advice. We demonstrate the complexities of managing patients isolated for prolonged periods and the need for emergent strategies to minimise their impact of current and future mental health.

Learning points

- ▶ Some immunocompetent patients shed COVID-19 for significantly prolonged periods. Factors contributing to this, and the contagiousness of these patients is unclear. As the pandemic progresses, establishing sensible management strategies that balance infectivity risk against the consequences of isolation to patients' well-being is critical to successful management.
- ▶ The management of patients with delirium and COVID-19 is challenging, for which realistic solutions are needed. Involvement of family in a safe manner was critical to the psychological well-being and recovery of our patient.
- ▶ Patients requiring prolonged periods of isolation are at risk of significant deterioration in their mental health, and even after discharge from hospital, the trauma of isolation can provoke ongoing psychological distress. A clearer understanding of the causes for this and ways to mitigate decline in mental health during isolation is imperative and follow-up of patients is necessary to understand the long-term impacts of the COVID-19 pandemic on mental health.

Acknowledgements The authors thank the patient and their family for support in the publication of this case report.

Contributors AMM and TPWJ provided equal contributorship in the research, documentation and authorship of this case report. CS provided educational oversight and support throughout the authorship.

Funding The authors have not declared a specific grant for this research from any funding agency in the public, commercial or not-for-profit sectors.

Competing interests None declared.

Patient consent for publication Obtained.

Provenance and peer review Not commissioned; externally peer reviewed.

ORCID iD

Timothy Peter Wynne Jones <http://orcid.org/0000-0001-6147-6748>

REFERENCES

- 1 Zhou F, Yu T, Du R, *et al.* Clinical course and risk factors for mortality of adult inpatients with COVID-19 in Wuhan, China: a retrospective cohort study. *Lancet* 2020;395:1054–62.
- 2 Wu Y, Guo C, Tang L, *et al.* Prolonged presence of SARS-CoV-2 viral RNA in faecal samples. *Lancet Gastroenterol Hepatol* 2020;5:434–5.
- 3 Docherty AB, Harrison EM, Green CA, *et al.* Features of 20 133 UK patients in hospital with covid-19 using the ISARIC WHO Clinical Characterisation Protocol: prospective observational cohort study. *BMJ* 2020;369:m1985.
- 4 Jones TPW, Buckland M, Breuer J, *et al.* Viral infection in primary antibody deficiency syndromes. *Rev Med Virol* 2019;29:e2049.
- 5 van der Vries E, Stittelaar KJ, van Amerongen G, *et al.* Prolonged influenza virus shedding and emergence of antiviral resistance in immunocompromised patients and ferrets. *PLoS Pathog* 2013;9:e1003343.
- 6 Lee Y-L, Liao C-H, Liu P-Y, *et al.* Dynamics of anti-SARS-Cov-2 IgM and IgG antibodies among COVID-19 patients. *J Infect* 2020;81:30230–9.
- 7 Zhu L, Gong N, Liu B, *et al.* Coronavirus disease 2019 pneumonia in immunosuppressed renal transplant recipients: a summary of 10 confirmed cases in Wuhan, China. *Eur Urol* 2020;77:748–54.

- 8 Liu W-D, Chang S-Y, Wang J-T, *et al.* Prolonged virus shedding even after seroconversion in a patient with COVID-19. *J Infect* 2020;81:318–56.
- 9 Li J, Zhang L, Liu B, *et al.* Case report: viral shedding for 60 days in a woman with novel coronavirus disease (COVID-19). *Am J Trop Med Hyg* 2020;102:1210–3.
- 10 Xu X, Chen Y, Yuan J, *et al.* Factors associated with prolonged viral RNA shedding in patients with coronavirus disease 2019 (COVID-19). *Clin Infect Dis* 2020;71:799–806.
- 11 Dexamethasone in hospitalized patients with Covid-19 — preliminary report. *New England Journal of Medicine* 2020.
- 12 Mathew D, Giles JR, Baxter AE, *et al.* Deep immune profiling of COVID-19 patients reveals distinct immunotypes with therapeutic implications. *Science* 2020;369:eabc8511.
- 13 He X, EHY L, Wu P, *et al.* Temporal dynamics in viral shedding and transmissibility of COVID-19. *Nat Med* 2020;26:672–5.
- 14 Bullard J, Dust K, Funk D, *et al.* Predicting infectious SARS-CoV-2 from diagnostic samples. *Clin Infect Dis* 2020. doi:10.1093/cid/ciaa638. [Epub ahead of print: 22 May 2020].
- 15 Wang W, Xu Y, Gao R, *et al.* Detection of SARS-CoV-2 in different types of clinical specimens. *JAMA* 2020;323:1843–4.
- 16 Wölfel R, Corman VM, Guggemos W, *et al.* Virological assessment of hospitalized patients with COVID-2019. *Nature* 2020;581:465–9.
- 17 Lin C, Xiang J, Yan M, *et al.* Comparison of throat swabs and sputum specimens for viral nucleic acid detection in 52 cases of novel coronavirus (SARS-CoV-2)-infected pneumonia (COVID-19). 2020;58:1089–94.
- 18 Walsh KA, Jordan K, Clyne B, *et al.* SARS-CoV-2 detection, viral load and infectivity over the course of an infection. *J Infect* 2020;81:357–71.
- 19 O’Hanlon S, Inouye SK. Delirium: a missing piece in the COVID-19 pandemic puzzle. *Age Ageing* 2020;49:497–8.
- 20 Lee AM, Wong JGWS, McAlonan GM, *et al.* Stress and psychological distress among SARS survivors 1 year after the outbreak. *Can J Psychiatry* 2007;52:233–40.
- 21 Jeong H, Yim HW, Song Y-J, *et al.* Mental health status of people isolated due to middle East respiratory syndrome. *Epidemiol Health* 2016;38:e2016048.
- 22 Mak IWC, Chu CM, Pan PC, *et al.* Long-term psychiatric morbidities among SARS survivors. *Gen Hosp Psychiatry* 2009;31:318–26.
- 23 Hawryluck L, Gold WL, Robinson S, *et al.* SARS control and psychological effects of quarantine, Toronto, Canada. *Emerg Infect Dis* 2004;10:1206–12.

Copyright 2020 BMJ Publishing Group. All rights reserved. For permission to reuse any of this content visit <https://www.bmj.com/company/products-services/rights-and-licensing/permissions/>
 BMJ Case Report Fellows may re-use this article for personal use and teaching without any further permission.

Become a Fellow of BMJ Case Reports today and you can:

- ▶ Submit as many cases as you like
- ▶ Enjoy fast sympathetic peer review and rapid publication of accepted articles
- ▶ Access all the published articles
- ▶ Re-use any of the published material for personal use and teaching without further permission

Customer Service

If you have any further queries about your subscription, please contact our customer services team on +44 (0) 207111 1105 or via email at support@bmj.com.

Visit casereports.bmj.com for more articles like this and to become a Fellow