



# Cerebrospinal Fluid Leakage from Scrotum Secondary to Ventriculoperitoneal Shunt Migration

Gregory Topp<sup>1</sup> Pouya Entezami<sup>1</sup> Shashikanth Ambati<sup>2</sup> Benjamin Szewczyk<sup>1</sup> Matthew A. Adamo<sup>1</sup>

<sup>1</sup>Department of Neurosurgery, Albany Medical Center, Albany, New York, United States

<sup>2</sup>Department of Paediatrics, Albany Medical Center, Albany, New York, United States

Address for correspondence Pouya Entezami, MD, Department of Neurosurgery, Albany Medical Center, 43 New Scotland Ave, MC10 A3 Clinic, Albany, NY 12208, United States (e-mail: entezap@amc.edu).

AJNS 2023;18:333–335.

## Abstract

Ventriculoperitoneal (VP) shunts are a common neurosurgical procedure used to treat hydrocephalus. Despite their efficacy, many shunts fail and require revisions. The most common causes of shunt failure include obstruction, infection, migration, and perforation. Extraperitoneal migrations require urgent attention. We present a case of migration to the scrotum, a unique complication that may be present in young patients due to the presence of a patent processus vaginalis. Here, we discuss a case of a 16-month-old male patient with a VP shunt presenting with cerebrospinal fluid (CSF) drainage from his scrotum after an indirect hernia repair. This case represents an important reminder for physicians about the sequelae associated with VP shunt complications, particularly extraperitoneal migration, and brings awareness to the underlying factors that may increase this risk.

## Keywords

- ▶ cerebrospinal fluid leak
- ▶ hydrocephalus
- ▶ ventriculoperitoneal shunt

## Introduction

Ventriculoperitoneal (VP) shunt placement is a common neurosurgical procedure used to treat hydrocephalus by removing excess cerebrospinal fluid (CSF) from the ventricles to facilitate resorption by the peritoneum. In the United States, data from the Healthcare Cost and Utilization Project Kids' Inpatient Database (KID) indicates that between 2,500 and 3,300 VP shunts are placed in the pediatric population aged 0 to 18 years every year.<sup>1,2</sup> However, despite their efficacy in treating hydrocephalus, 30 to 40% of pediatric shunts fail within the first year, with most requiring a revision in their lifetime.<sup>3</sup> Overall, the most common causes of shunt failure include mechanical obstruction due to blockage, catheter breakage or migration (including extra-

peritoneal perforations), followed by infections.<sup>4,5</sup> In the pediatric population specifically, ventricular catheter obstruction with tissue, commonly either from glial tissue or the choroid plexus, has been reported to cause over 50% of shunt failures.<sup>6</sup>

## Case Presentation

We present a 16-month-old fraternal twin male born at 35 weeks and 5 days gestational age via cesarean section. He was born with a myelomeningocele and associated Chiari II malformation and underwent surgical repair of the former immediately after birth. His infancy was complicated by hydrocephalus, which was treated by VP shunt placement at age 6 days. Fifteen months after the shunt was placed, he

article published online  
April 11, 2023

DOI <https://doi.org/10.1055/s-0043-1763521>.  
ISSN 2248-9614.

© 2023. Asian Congress of Neurological Surgeons. All rights reserved.

This is an open access article published by Thieme under the terms of the Creative Commons Attribution-NonDerivative-NonCommercial-License, permitting copying and reproduction so long as the original work is given appropriate credit. Contents may not be used for commercial purposes, or adapted, remixed, transformed or built upon. (<https://creativecommons.org/licenses/by-nc-nd/4.0/>)

Thieme Medical and Scientific Publishers Pvt. Ltd., A-12, 2nd Floor, Sector 2, Noida-201301 UP, India

presented to the emergency department with a 2-day history of clear fluid draining from the scrotal sac with acute onset of emesis and progressive lethargy. One week prior to this admission, the patient had undergone a right orchiopexy for an undescended testes and indirect inguinal hernia repair, made challenging by testicular adhesions to the abdominal wall and scarring in the inguinal canal secondary to irritation and inflammation from the VP shunt. In the emergency department, he was found to have leukocytosis and anion gap acidosis. On physical examination, vital signs were stable and clear fluid was dripping from the right scrotal incision.

CSF from the shunt reservoir was sent for analysis. Given the high concern for CSF leak and VP shunt infection, he was started on empiric antibiotics for meningitis by the emergency department. Computed tomography (CT) demonstrated an intact right VP shunt with the catheter tip in the right lateral abdomen without obstruction or mechanical failure. Ultrasound of the abdomen and scrotum showed fluid collection within the right scrotal sac. Computed tomography (CT) of the abdomen and pelvis demonstrated the distal VP shunt catheter within the right inguinal canal, draining CSF into the scrotum via a patent processus vaginalis (→Fig. 1).

Given these radiographic findings, decision was made to externalize the shunt and repair the scrotal dehiscence. The procedures were performed without issue and the patient was monitored postoperatively in the pediatric intensive care unit. Drain output was continuously monitored and remained stable. Eleven days later, it was determined that the scrotal dehiscence and urological interventions to close the patent processus vaginalis had healed enough to re-internalize the shunt. CSF cultures (including the original

samples from the VP shunt reservoir) remained negative. The distal catheter was re-internalized into the patient's abdomen without complication. The patient was discharged home on postoperative day 3. The patient has been doing well without return of symptoms or other postoperative concerns at 12-months follow-up.

## Discussion

Despite their efficacy, VP shunt failure and revision rates remain high. Mechanical failures such as obstruction, disconnections, and migrations are the most common cause of revisions, followed by infections.<sup>4,5</sup> In pediatric populations, cranial obstructions, usually of the ventricular catheter, and hardware misplacement comprise most complications.<sup>6,7</sup> While less common, migrations have the potential to cause significant distress to patients due to improper drainage resulting in a recurrence of hydrocephalus, fluid accumulations in areas that cannot sufficiently resorb CSF, bowel perforations and obstructions, or, in rare cases, extraperitoneal perforations.

While uncommon, extraperitoneal migrations have been reported in the literature occurring at various locations, most commonly the bowel and genitourinary tract.<sup>8</sup> Distal portions of VP shunts have been found in the vagina, pericardium, lung, bladder, and scrotum.<sup>9-13</sup> Shunt migrations have been found to occur mainly within the first year of placement, are more common in children than adults, and when exposure to the external environment occurs, are associated with a greater than 50% chance of infection.<sup>8</sup>

Scrotal migrations usually occur in infants with a patent processus vaginalis although a few adult cases have been reported.<sup>14,15</sup> Scrotal migration is theorized to occur during infancy and the first few years of life as a result of the increased intraperitoneal pressure created by the VP shunt and the resultant maintained patency of the processus vaginalis, usually present on the right side.<sup>16,17</sup> Our patient's case was complicated by recent urological surgery on that side. In most cases, migration results in hydroceles that are treated via surgical repositioning or removal of the shunt with subsequent obliteration of the processus vaginalis.<sup>14-16,18,19</sup> Rarely these migrations may cause scrotal perforations and greatly increase the risk of infection.<sup>20,21</sup>

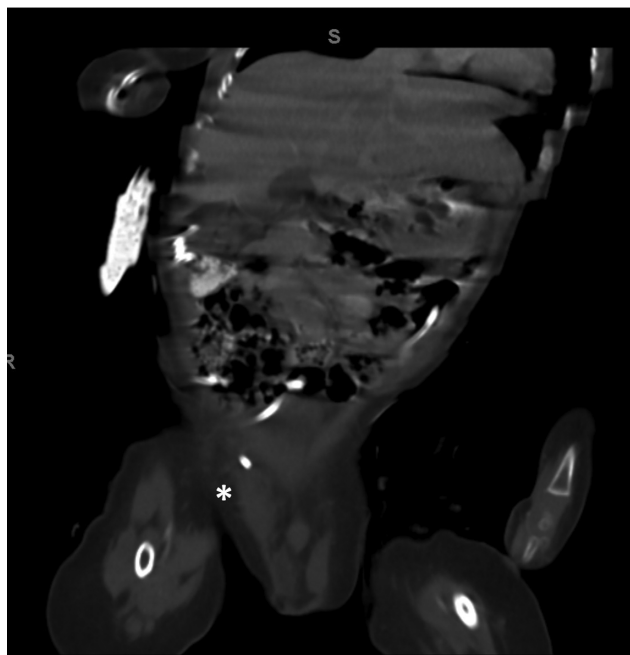
This case represents a unique presentation of CSF leak secondary to scrotal migration, which nearly went undiagnosed due to its rarity. Repair of the underlying embryological condition via scrotal or inguinal canal surgery may serve as an entryway for VP shunt infection. Thus, surgeons and other clinicians should take extra caution to avoid this risk.

### Conflict of Interest

None declared.

## References

- Berry JG, Lieu TA, Forbes PW, Goldmann DA. Hospital volumes for common pediatric specialty operations. *Arch Pediatr Adolesc Med* 2007;161(01):38-43



**Fig. 1** Coronally oriented CT demonstrating malpositioned tip of the distal shunt within the right inguinal canal with a patent processus vaginalis and CSF within the right scrotal sac (white asterisk).

- 2 Lam SK, Srinivasan VM, Luerssen TG, Pan IW. Cerebrospinal fluid shunt placement in the pediatric population: a model of hospitalization cost. *Neurosurg Focus* 2014;37(05):E5
- 3 McGirt MJ, Zaas A, Fuchs HE, George TM, Kaye K, Sexton DJ. Risk factors for pediatric ventriculoperitoneal shunt infection and predictors of infectious pathogens. *Clin Infect Dis* 2003;36(07):858–862
- 4 Merkler AE, Ch'ang J, Parker WE, Murthy SB, Kamel H. The rate of complications after ventriculoperitoneal shunt surgery. *World Neurosurg* 2017;98:654–658
- 5 Feletti A, d'Avella D, Wikkelsø C, et al. Ventriculoperitoneal shunt complications in the European Idiopathic Normal Pressure Hydrocephalus Multicenter Study. *Oper Neurosurg (Hagerstown)* 2019;17(01):97–102
- 6 Hanak BW, Bonow RH, Harris CA, Browd SR. Cerebrospinal fluid shunting complications in children. *Pediatr Neurosurg* 2017;52(06):381–400
- 7 Mansoor N, Solheim O, Fredriksli OA, Gulati S. Shunt complications and revisions in children: a retrospective single institution study. *Brain Behav* 2021;11(11):e2390
- 8 Harischandra LS, Sharma A, Chatterjee S. Shunt migration in ventriculoperitoneal shunting: a comprehensive review of literature. *Neurol India* 2019;67(01):85–99
- 9 Shankar B, Narayanan R, Paruthikunnan SM, Kulkarni CD. Scrotal migration of ventriculoperitoneal shunt. *BMJ Case Rep* 2014;2014:x
- 10 Lotfinia I, Tubbs S, Mahdkhah A. Vaginal extrusion of a ventriculoperitoneal shunt: a case report and review of literature. *J Pediatr Adolesc Gynecol* 2017;30(01):e23–e25
- 11 Wiwattanadittakul N, Katanyuwong K, Jetjumnong C, Sittiwangkul R, Makonkawkeyoon K. Pericardial effusion and cardiac tamponade after ventriculoperitoneal shunt placement: a case report. *Acta Neurochir (Wien)* 2016;158(10):2019–2021
- 12 Yang X, Liang R, Zhang Y. An unusual complication of ventriculoperitoneal shunt with bladder perforation and extrusion through the urethra orifice in an adult male patient. *Int J Neurosci* 2019;129(01):101–102
- 13 Ruiz Johnson A, Jaimovich SG, Reusmann A, Álvarez M, Lubieniecki FJ, Mantese BE. Lung destruction secondary to intrapulmonary migration of a ventriculoperitoneal shunt catheter: report of an unusual case and literature review. *Childs Nerv Syst* 2021;37(03):989–993
- 14 Oktem IS, Akdemir H, Koç K, et al. Migration of abdominal catheter of ventriculoperitoneal shunt into the scrotum. *Acta Neurochir (Wien)* 1998;140(02):167–170
- 15 Lee BS, Vadera S, Gonzalez-Martinez JA. Rare complication of ventriculoperitoneal shunt. Early onset of distal catheter migration into scrotum in an adult male: case report and literature review. *Int J Surg Case Rep* 2015;6C:198–202
- 16 Mohammadi A, Hedayatiasl A, Ghasemi-Rad M. Scrotal migration of a ventriculoperitoneal shunt: a case report and review of literature. *Med Ultrason* 2012;14(02):158–160
- 17 Shahizon AM, Hanafiah M, Hing EY, Julian MR. Migration of a fractured ventriculoperitoneal shunt into the scrotum: a rare complication. *BMJ Case Rep* 2013;2013:x
- 18 Karaosmanoglu D, Metin Y, Akata D, Haliloglu M. An unusual cause of hydrocele: malpositioned ventriculoperitoneal shunt in the scrotum. *J Ultrasound Med* 2008;27(01):159–160
- 19 Paterson A, Ferch R. Infant with recurrent ventriculoperitoneal shunt migration to right scrotum. *J Clin Neurosci* 2018;51:65–66
- 20 de Aquino HB, Carelli EF, Borges Neto AG, Pereira CU. Nonfunctional abdominal complications of the distal catheter on the treatment of hydrocephalus: an inflammatory hypothesis? Experience with six cases. *Childs Nerv Syst* 2006;22(10):1225–1230
- 21 Rehm A, Bannister CM, Victoratos G. Scrotal perforation by a ventriculoperitoneal shunt. *Br J Neurosurg* 1997;11(05):443–444