

Extracorporeal Membrane Oxygenation Support for Incessant Tachyarrhythmia-Induced Severe Cardiogenic Shock

Zhi-Ping Zhang, Xi Su, Jiang-You Wang, Cheng-Wei Liu

Department of Cardiology, Wuhan Asia Heart Hospital, Affiliated to Wuhan University of Science and Technology, Wuhan, Hubei 430022, China

To the Editor: Junctional ectopic tachycardia is uncommon; however, it is one of the most serious incessant supraventricular tachycardia. This tachyarrhythmia has a high association with tachycardia-induced cardiomyopathy or myocardial depressant. It is often refractory to conventional medical therapy and is not usually responsive to direct current cardioversion. Due to the fact that antiarrhythmic medications are associated with the adverse effects of proarrhythmic or refractory hypotension, the use of these agents may further deteriorate the condition of patients with tachyarrhythmias. In such instances, it often requires other alternatives to conventional therapy to prevent hemodynamic deterioration. Extracorporeal life support such as extracorporeal membrane oxygenation (ECMO) can be used in such cases and may be lifesaving. It may allow time for satisfactory control of dysrhythmias while awaiting recovery of myocardial and other organ functions. Herein, we described the use of venoarterial ECMO in a patient with severe cardiogenic shock because of incessant junctional ectopic tachycardia with no response to conventional therapy.

A 17-year-old girl with perimembranous ventricular septal defect (VSD) underwent a transcatheter closure of VSD. She had no other history of disease before the procedure. Electrocardiography (ECG) showed sinus rhythm and did not show any abnormalities. Transthoracic echocardiography (TTE) revealed a defect of 6 mm in the perimembranous ventricular septum. The tricuspid regurgitation was severe with an ejection fraction of 60%. The defect was closed through a standard method with waist diameter of 10 mm membranous VSD occluder device without any complication during the procedure. After the operation, TTE showed that the defect was totally closed and that tricuspid regurgitation was minor. There was no rhythm or conduction abnormality in the following days. The patient was discharged with oral aspirin.

Nine days after the operation, the patient returned to the hospital due to palpitations and amaurosis. The ECG showed narrow QRS wave tachycardia with heart rate of 210 beats/min [Figure 1]. An esophageal electrocardiogram showed spontaneous narrow QRS wave tachycardia and auriculoventricular dissociation which could not be terminated by transesophageal overdrive pacing and was not responsive to direct current cardioversion. A variety of antiarrhythmic medications (adenosine, amiodarone, verapamil, and metoprolol) also failed to control the tachyarrhythmia.

Unfortunately, the conditions of the patient further deteriorate as a result of undesirable adverse effects of these antiarrhythmic medications.

The cardiac rhythm accelerated to 220–270 beats/min, and she developed to a severe cardiogenic shock with severe pulmonary vascular congestion and pulmonary edema, contributed to her persistent hypoxemia. The patient's profound hemodynamic instability persisted despite administration of catecholamine medications such as dopamine, intravenous epinephrine. In this critical situation, a venoarterial ECMO system was inserted to provide hemodynamic support via the left femoral artery and vein. Immediate pre-ECMO arterial blood analysis revealed a pH of 6.84 and a base excess of <-20 mmol/L. Initiation of ECMO (a flow rate of 3 L/min) led to immediate hemodynamic stability, and no further catecholamine medications was required. With the ECMO support about 6 hours, the heart rate decreased gradually to the range of 80–120 beats/min with accelerated junctional rhythm. On the second day (ECMO support about 12 h), the ECG showed sinus rhythm, and she had a favorable recovery of cardiac function (ejection fraction of 50%). She was able to discontinue ECMO support. Clinical follow-up for 6 months, she had no symptoms and ECG showed normal sinus rhythm.

The present case report described the use of ECMO for a severe cardiogenic shock related to incessant junctional ectopic tachycardia secondary to catheter closure of VSD and had been shown the benefit of ECMO to restore systemic circulation and to allow time for achieving rate control and sinus rhythm while awaiting recovery of myocardial function.

Tachyarrhythmia, if persistent, can progress to cardiomyopathy or myocardial dysfunction. Tachyarrhythmia-induced cardiomyopathy can entirely or partially reversible after control of the responsible tachyarrhythmia and is typically caused by an incessant

Address for correspondence: Prof. Xi Su,

Department of Cardiology, Wuhan Asia Heart Hospital,
No. 753 Jingnan Avenue, Hankou, Wuhan 430022, China
E-Mail: yaxin_suxi@163.com

This is an open access journal, and articles are distributed under the terms of the Creative Commons Attribution-NonCommercial-ShareAlike 4.0 License, which allows others to remix, tweak, and build upon the work non-commercially, as long as appropriate credit is given and the new creations are licensed under the identical terms.

© 2018 Chinese Medical Journal | Produced by Wolters Kluwer - Medknow

Access this article online

Quick Response Code:



Website:
www.cmj.org

DOI:
10.4103/0366-6999.239298

Received: 17-06-2018 **Edited by:** Ning-Ning Wang

How to cite this article: Zhang ZP, Su X, Wang JY, Liu CW. Extracorporeal Membrane Oxygenation Support for Incessant Tachyarrhythmia-Induced Severe Cardiogenic Shock. Chin Med J 2018;131:2139-40.

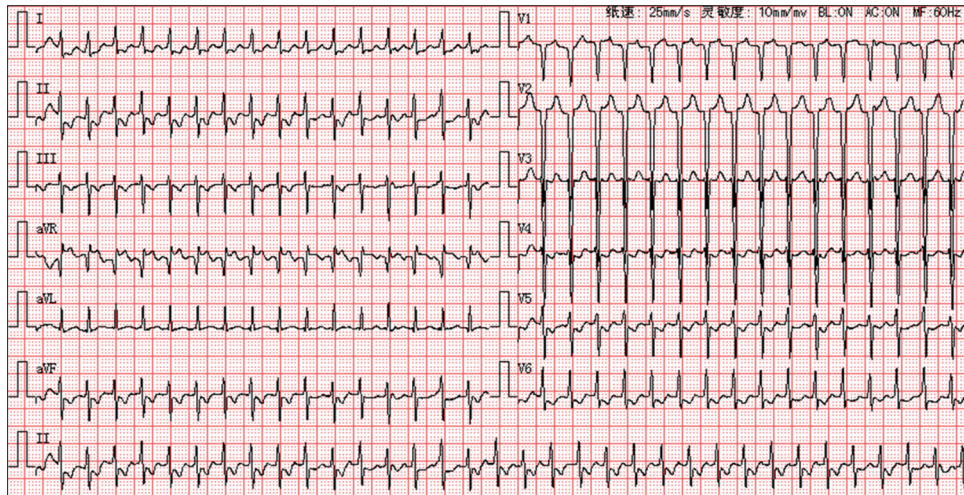


Figure 1: The 12-lead electrocardiogram at admission showing a junctional ectopic tachycardia.

supraventricular tachycardia. Junctional ectopic tachycardia is often the form of incessant supraventricular tachycardia. It is believed to originate from a focus with abnormal automaticity within or immediately adjacent to the atrioventricular junction and is believed to be secondary to trauma, infiltrative hemorrhage, or inflammation of the conduction tissue.^[1] The nature of congenital heart surgery and its repair have been implicated as a major contributor to the genesis of junctional ectopic tachycardia.^[2] Postoperative junctional ectopic tachycardia is associated with manipulation within the crux of the heart, resulting in myocardial injury which increases the electrical excitability in heart tissue. Transcatheter closure of VSD as an alternative to surgical treatment is mini traumatic. One of the most serious complications is complete atrioventricular block.^[3] Junctional ectopic tachycardia has rarely been reported in patients with VSD following intervention. However, this rare incessant tachyarrhythmia still occurred in this particular case.

For most patients with primary tachyarrhythmias, they can be successfully managed with appropriate antiarrhythmic therapy, overdrive pacing, direct current cardioversion, and, if necessary, timely ablation.^[4] However, these therapies are not always effective. Rarely, despite appropriate attempts to treat, some patients with refractory arrhythmias may present late with severely reduced cardiac function and even deteriorate to cardiac arrest requiring cardiopulmonary resuscitation. ECMO provides cardiopulmonary support and it is an effective rescue technique proposed for cardiogenic shock or cardiac arrest due to various pathophysiological situations. However, there are only few reports on the use of ECMO in neonates or infants with incessant tachyarrhythmia as a bridge to recovery and those patients had a good prognosis.^[5]

In our case, the incessant tachyarrhythmia was resistant to overdrive pacing as well as medical and electrical cardioversion. In the setting of cardiac function decompensation occurred during initiation of conventional therapies, ECMO was immediately chosen as a rescue therapy. ECMO in this condition provided significant haemodynamic support and it ensured the weaning of the antiarrhythmic and catecholamine drugs, thereby achieving rate control and sinus rhythm. This case highlights the importance

of timely ECMO support for incessant tachyarrhythmia when the hemodynamically unstable arrhythmia fails to be controlled by a conventional treatment.

Declaration of patient consent

The authors certify that they have obtained all appropriate patient consent forms. In the form the patient(s) has/have given his/her/their consent for his/her/their images and other clinical information to be reported in the journal. The patients understand that their names and initials will not be published and due efforts will be made to conceal their identity, but anonymity cannot be guaranteed.

Financial support and sponsorship

The study was supported by a grant from the 2015 Training Project of Wuhan Young & Middle-aged Medical Backbone.

Conflicts of interest

There are no conflicts of interest.

REFERENCES

1. Dodge-Khatami A, Miller OI, Anderson RH, Goldman AP, Gil-Jaurena JM, Elliott MJ, *et al*. Surgical substrates of postoperative junctional ectopic tachycardia in congenital heart defects. *J Thorac Cardiovasc Surg* 2002;123:624-30. doi: 10.1067/mtc.2002.121046.
2. Andreasen JB, Johnsen SP, Ravn HB. Junctional ectopic tachycardia after surgery for congenital heart disease in children. *Intensive Care Med* 2008;34:895-902. doi: 10.1007/s00134-007-0987-2.
3. Fu YC, Bass J, Amin Z, Radtke W, Cheatham JP, Hellenbrand WE, *et al*. Transcatheter closure of perimembranous ventricular septal defects using the new Amplatzer membranous VSD occluder: Results of the U.S. Phase I trial. *J Am Coll Cardiol* 2006;47:319-25. doi: 10.1016/j.jacc.2005.09.028.
4. Paech C, Janousek J, Wagner F, Gebauer RA. Rate control by transoesophageal atrial overdrive pacing for refractory supraventricular tachycardia with severe ventricular dysfunction: A bridge to recovery. *Pediatr Cardiol* 2017;38:228-33. doi: 10.1007/s00246-016-1503-7.
5. Darst JR, Kaufman J. Case report: An infant with congenital junctional ectopic tachycardia requiring extracorporeal mechanical oxygenation. *Curr Opin Pediatr* 2007;19:597-600. doi: 10.1097/MOP.0b013e3282f11f55.