

# Difficult tracheostomy tube placement in an obese patient with a short neck

## -A case report-

Sung Mi Hwang, Ji Su Jang, Jae In Yoo, Hyung Ki Kwon, Soo Kyung Lee, Jae Jun Lee, and So Young Lim

Department of Anesthesiology and Pain Medicine, School of Medicine, Hallym University, Chuncheon, Korea

We report a difficult case of tracheostomy in a 34-year-old obese woman with a short neck. The tracheostomy tube placement repeatedly failed because of anatomical changes due to obesity and a short neck, tracheal mucosal swelling due to prolonged intubation, and unexpected false passage; however, it was successfully performed using an endotracheal tube exchanger as a guidewire. (Korean J Anesthesiol 2011; 60: 434-436)

**Key Words:** Guidewire, Obesity, Tracheostomy.

The overall complication rate of surgical tracheostomy in obese patients is estimated at 25%; most complications are minor. Serious complications occur in 10% of cases and are usually life-threatening [1]. Of patients requiring tracheostomy, obese patients present a unique surgical challenge because of increased submental and anterior cervical adipose tissue, and a short, thick neck. We present a difficult surgical tracheostomy performed on obese patient with a short neck and prolonged intubation, and successful placement of a tracheal tube using an endotracheal tube exchanger as a guidewire.

## Case Report

A 34-year-old woman with obesity (height, 150 cm; weight, 65 kg; and body mass index, 28.8 kg/m<sup>2</sup>) and a short neck

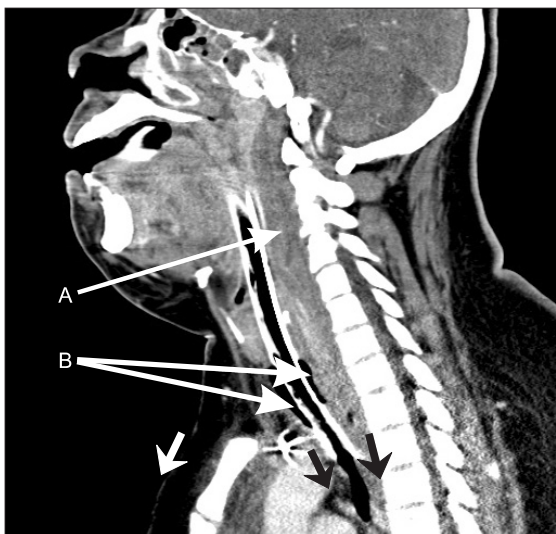
(Fig. 1) suddenly developed dyspnea, seizure, and drowsy change of mental status and was transferred to our hospital for management. Her diagnosis was spontaneous subarachnoid hemorrhage due to left middle cerebral artery (MCA) aneurismal rupture, and she underwent coil embolization. On postoperative day 4, a deteriorating level of consciousness and respiratory failure requiring intubation occurred because of postoperative vasospasm. On postoperative day 10, a computed tomography (CT) scan of her head and neck showed a retropharyngeal abscess (Fig. 1), and the physicians decided to perform a tracheostomy because of operative drainage of the abscess and anticipated prolonged ventilator dependency.

In the operating room, the patient's initial vital signs were blood pressure 120/80 mmHg, heart rate 95 beats min<sup>-1</sup>, and O<sub>2</sub> saturation 99%; she was still intubated. Anesthesia was induced

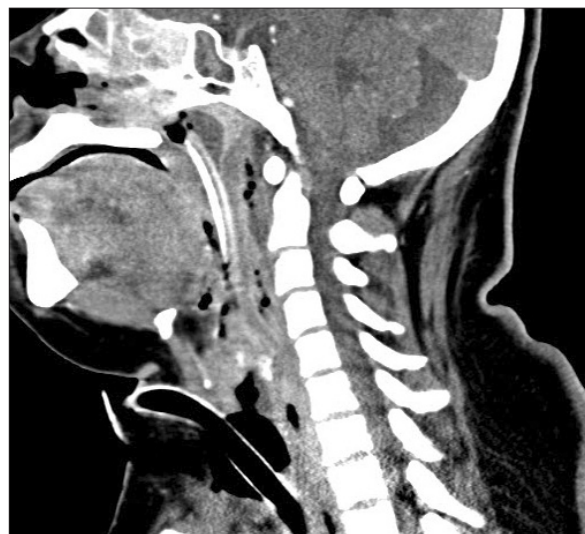Received: December 16, 2010. Revised: 1st, December 27, 2010; 2nd, January 2, 2011. Accepted: January 2, 2011.

Corresponding author: Jae Jun Lee, M.D., Department of Anesthesiology and Pain Medicine, Chuncheon Sacred Heart Hospital, 153, Kyo-dong, Chuncheon 200-704, Korea. Tel: 82-33-240-5353, Fax: 82-33-252-0941, E-mail: iloveu59@hallym.or.kr

© This is an open-access article distributed under the terms of the Creative Commons Attribution Non-Commercial License (<http://creativecommons.org/licenses/by-nc/3.0/>), which permits unrestricted non-commercial use, distribution, and reproduction in any medium, provided the original work is properly cited.



**Fig. 1.** Midline sagittal computed tomography section of cervical area shows short thick neck, retropharyngeal abscess (arrow A) and endotracheal tube whose cuff was placed the level of 7<sup>th</sup> and 8<sup>th</sup> cervical spines (arrow B). It also shows that the trachea (the straight black arrow) follows the similar course of the cervical and thoracic spine (the straight black arrow) and not the direction of the skin contour (the straight white arrows).



**Fig. 2.** Midline sagittal computed tomography section of cervical area shows that the tracheostomy tube is inserted into the trachea.

with 60 mg of propofol and 40 mg of rocuronium, and was maintained using sevoflurane 2% with N<sub>2</sub>O/O<sub>2</sub>. End-tidal CO<sub>2</sub> was kept at 38 to 40 mmHg. An expert senior otolaryngologist made an anterior tracheal wall incision; the ETT was retracted cephalad, and its tip was visualized at the upper border of the tracheal incision. A 7.0-mm inner diameter (ID) tracheostomy tube was fully inserted and the cuff was inflated. We tried to ventilate manually. However, the patient could not be ventilated, and no end-tidal CO<sub>2</sub> waveform showed on the capnograph. The tracheostomy tube was removed and the ETT, placing it at the upper border of the tracheal stoma, was inserted. The patient could then be ventilated normally, and an end-tidal CO<sub>2</sub> waveform appeared. The operator tried to insert the 7.0-mm ID tube again, as well as 7.5- and 8-mm ID tubes, but the results were the same. He thought that a false passage within the trachea was made; the insertion into the true passage was difficult due to the angle of her obese, short neck. We used an ETT exchanger with a flexible tip as a guidewire, inserting the exchanger into the trachea through the tracheal stoma. The tracheal tube was then inserted through the guidewire. At the time of insertion, the tube bent forward excessively and was entered just inferior to the anterior tracheal rings compared to the previous trial. After the insertion was completed (Fig. 2), the patient could be ventilated successfully through the tracheal tube, and an end-tidal CO<sub>2</sub> waveform was visible. Surgical drainage of the abscess was performed uneventfully, and the patient was transferred to the surgical ICU.

## Discussion

To perform a surgical tracheostomy, the patient's shoulders are elevated and the head is extended unless contraindicated by cervical disease or injury. This position elevates the larynx and exposes more of the upper trachea [2]. However, even in this position, our patient's neck was still too short. Muhammad and colleagues [3] compared MRI scans of patients with short, thick necks and those with normal necks. They reported that the more exaggerated the curvature of the spine, the further away the trachea is from the skin, and that the trachea follows the curvature of the spine, not the skin. Our patient had similar anatomy. Sagittal CT scans show that the trachea follows the course of the cervical and thoracic spine and not the direction of the skin contour, and that the curvature of the spine is quite pronounced. As a result, the extrathoracic trachea lies deep in the root of neck (Fig. 1). Tracheostomies in these individuals are usually fraught with difficulties because of the size discrepancy and curvature mismatch between a standard-size tracheostomy tube and the increased distance between the skin and trachea. As most commercially available tracheostomy tubes are designed with normal limits of anatomic proportions in mind, these standard tubes are usually of inadequate length to suit obese patients and those with short, thick necks [4]. Standard tracheostomy tubes are too short and angulated.

Furthermore, the patient had an ETT whose cuff was placed at the level of the seventh and eighth cervical vertebrae (Fig. 1); this position could cause swelling of the membranous portion of the trachea. Increased tracheal mucosal swelling is a major risk factor for the creation of a false passage during tracheostomy [5].

The level of ETT cuff placement was similar to the level of the tracheal tube tip; thus, the tube could be obstructed against the posterior tracheal wall due to both the swelling of the posterior wall and curvature mismatch.

In general, a 10-mm outer diameter (OD) tube is usually appropriate for adult women, and an 11-mm OD tube is usually appropriate for adult men as initial tracheostomy tube sizes [6]. In this case, we used 7-, 7.5-, and 8-mm ID tubes, which were angled tracheostomy tubes with 10.0-, 10.6-, and 11.2-mm ODs, respectively. Several trials with different tracheal tube sizes were all inserted into the false passage; however, insertion through a guidewire with a 10.6-mm OD tube was successfully placed. Previously, some authors suggested the use of suction catheters or nasogastric tubes as a guidewire for replacement of tracheostomy tubes [7-9]. However, we think that the catheters or tubes are too flexible to act as a guidewire, and that the ETT exchanger, which is solid, not hollow, acts as a truly adequate guide. Furthermore, our case involved the initial placement of a tracheal tube, which was successfully performed with an ETT exchanger, effectively overcoming a false passage.

In conclusion, potential difficulties exist with both surgical tracheostomy performed on obese patients with short/thick necks and prolonged intubation. This report shows that an ETT exchanger can be successfully used as a guidewire in cases of difficult tracheostomy tube placement caused by anatomical changes due to obesity and a short neck, tracheal mucosal

swelling due to prolonged intubation, and unexpected false passage.

## References

1. El Solh AA, Jaafar W. A comparative study of the complications of surgical tracheostomy in morbidly obese critically ill patients. *Crit Care* 2007; 11: R3.
2. Durbin CG Jr. Tracheostomy: why, when, and how? *Respir Care* 2010; 55: 1056-68.
3. Muhammad JK, Major E, Patton DW. Evaluating the neck for percutaneous dilatational tracheostomy. *J Craniomaxillofac Surg* 2000; 28: 336-42.
4. Headley WB, Rodning CB. Fabricated single lumen tracheal cannula for a morbidly obese patient. *J Otolaryngol* 1993; 22: 438-41.
5. Windsor HM, Shanahan MX, Cherian K, Chang VP. Tracheal injury following prolonged intubation. *Aust N Z J Surg* 1976; 46: 18-25.
6. Hess DR. Tracheostomy tubes and related appliances. *Respir Care* 2005; 50: 497-510.
7. Myers EN, Carrau RL. Early complications of tracheotomy. incidence and management. *Clin Chest Med* 1991; 12: 589-95.
8. Brown JM, White MC. Conversion from suction catheter to guidewire for difficult tracheostomy tube change. *Anaesth Intensive Care* 2004; 32: 842.
9. Young JS, Brady WJ, Kesser B, Mullins D. A novel method for replacement of the dislodged tracheostomy tube: the nasogastric tube "guidewire" technique. *J Emerg Med* 1996; 14: 205-8.