

Parasitic Myomas: An Unusual Risk after Morcellation

P. G. Paul, Hemant Shintre, Santwan Mehta, Gunjan Gulati, George Paul, Sumina Mannur

Centre for Advanced Endoscopy and Infertility Treatment, Paul's Hospital, Kochi, Kerala, India

Abstract

A 24-year-old unmarried woman had undergone laparoscopic myomectomy for single degenerated myoma of size 15 cm. Uncontained morcellation of the myoma was done with an electromechanical morcellator. Two years later, she presented with abdominal pain, and laparoscopy revealed enlarged uterus (20 weeks) with multiple degenerated myomas. There were multiple parasitic myomas measuring 1–3 cm in the pelvis and anterior abdominal wall which were removed laparoscopically. Histopathology of all the myomas including parasitic myomas confirmed the diagnosis of leiomyoma. The formation of parasitic myomas was assumed to be due to the myomatous fragments which were left behind during morcellation at the time of initial myomectomy. Methods to prevent this complication are colpotomy, mini-laparotomy, or in-bag morcellation.

Keywords: Laparoscopic myomectomy, parasitic myoma, uncontained tissue morcellation

INTRODUCTION

Laparoscopic myomectomy is a safe and feasible option for women with symptomatic myomas who desire uterine conservation. This minimally invasive procedure is associated with better postoperative outcomes, including less postoperative pain, quicker recovery, and fewer overall complications, compared with abdominal myomectomy. There are many reports of parasitic myomas after laparoscopic uncontained morcellation of uterine fibroids.^[1-3] The overall incidence of parasitic myomas after laparoscopic surgery with the use of uncontained morcellation is reported to be 0.9%.^[4] We report a case of multiple parasitic myomas after uncontained electromechanical morcellation.

CASE REPORT

A 24-year-old unmarried woman presented with lower abdominal pain of 6 months' duration. She had undergone laparoscopic myomectomy for a 15-cm posterior intramural degenerated myoma 2 years back. The specimen was removed via uncontained morcellation with electromechanical tissue morcellator and the specimen weighed 900 g. She had recurrence of myoma after 2 years and treated with ulipristal acetate for 3 months.

On clinical examination, the uterus enlarged to 20 weeks' gravid uterus size. Transabdominal ultrasound showed enlarged uterus with multiple myomas including largest

fundoposterior wall myoma of 9 cm and posterior wall myoma of 6 cm. Laparoscopy revealed an enlarged uterus with multilobulated degenerated myoma of 15 cm in the fundoposterior region and other 5 myomas of 3–4 cm in the posterior wall. There were multiple parasitic myomas of 1–3 cm in the pelvis and anterior abdominal wall [Figures 1 and 2]. All the myomas were removed from the uterus and the myometrium was sutured with barbed sutures. Eleven parasitic myomas of 1–3 cm were excised from pelvic wall, uterovesical fold, and anterior abdominal wall. For reducing the risk of recurrence of parasitic myomas, all the myomas were placed in a specially designed endobag (MorSafe tissue isolation bag (Veol Technologies, Mumbai, Maharashtra, India)) and removed from the peritoneal cavity by in-bag morcellation as described earlier.^[5] Histopathology of all the myomas including parasitic myomas confirmed the diagnosis of leiomyoma.

DISCUSSION

The first case of a parasitic myoma after use of the laparoscopic morcellation was reported in 1997 by Ostrzenski.^[6] There

Address for correspondence: Dr. P. G. Paul,
Centre for Advanced Endoscopy and Infertility Treatment, Paul's Hospital,
Vattekkattu Road, Kaloork, Kochi - 682 017, Kerala, India.
E-mail: drpaulpg@gmail.com

Access this article online

Quick Response Code:



Website:
www.e-gmit.com

DOI:
10.4103/GMIT.GMIT_36_18

This is an open access journal, and articles are distributed under the terms of the Creative Commons Attribution-NonCommercial-ShareAlike 4.0 License, which allows others to remix, tweak, and build upon the work non-commercially, as long as appropriate credit is given and the new creations are licensed under the identical terms.

For reprints contact: reprints@medknow.com

How to cite this article: Paul PG, Shintre H, Mehta S, Gulati G, Paul G, Mannur S. Parasitic myomas: An unusual risk after morcellation. *Gynecol Minim Invasive Ther* 2018;7:124-6.

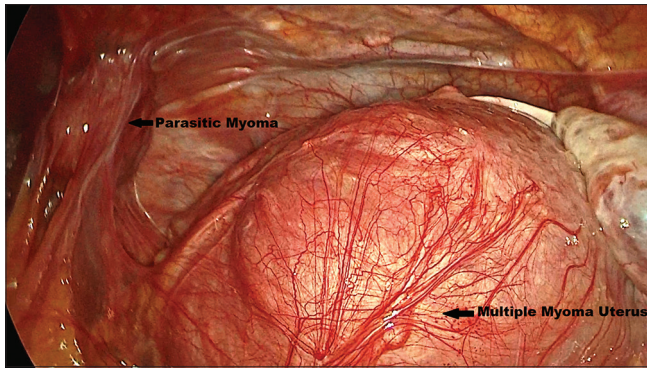


Figure 1: Multiple myoma uterus with parasitic myoma

were many reports of iatrogenic parasitic myomas afterward.^[1-3] During electromechanical morcellation, small tissue fragments are easily lost in the peritoneal cavity and can regrow into parasitic myomas.^[7] Gonadal steroid hormones are known to influence the growth of uterine fibroids.^[8] Likewise, it is hypothesized that prolonged exposure to steroid hormones such as hormonal replacement therapy could be a risk factor for the development of parasitic myomas.^[9] Takeda *et al.*^[1] compared the histological appearance of multiple parasitic myomas found 6 years after laparoscopic myomectomy with electric tissue morcellation, with the histological results of the myoma removed at the initial surgery. The histopathological findings were almost identical and the presence of progesterone receptors was reported in both the parasitic myomas and the previously removed myoma. The impact of hormones on the development of parasitic myomas was illustrated by a case of rapid growth of a parasitic myoma during pregnancy. Takeda *et al.*^[1] published a case report of a woman who was diagnosed with a parasitic myoma 2 years after a laparoscopic myomectomy. After 2 years of conservative treatment, the size of the mass remained the same; yet during pregnancy, rapid growth of this mass was observed, supporting the hormonal impact on the growth of parasitic myomas.

The clinical presentations of parasitic myomas are nonspecific. Patients may present with pain, pelvic pressure, dyspareunia, abdominal or pelvic mass, or even may be asymptomatic.^[2,10] As these symptoms are more commonly associated with uterine myomas, the diagnosis of parasitic myomas is often incidental at the time of surgery for symptomatic uterine myomas. Clinically, any mass separated from the uterus in case of previous laparoscopic morcellation of myoma should raise the suspicion of parasitic myoma. The identification of myoma-like lesions outside pelvis by ultrasonography may aid in the diagnosis. Magnetic resonance imaging (MRI) is the most reliable technique in such cases. It can accurately demonstrate the location of the tumor relative to adjacent structures such as the ureter, bladder, or rectum.^[11] In the present case, the diagnosis of parasitic myoma was made only during laparoscopy. Takeda *et al.*^[1] had identified multiple tumors ranging from 1 to 6 cm with unknown origin in the

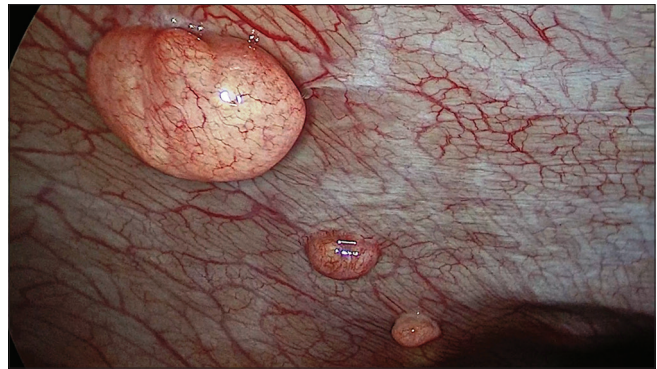


Figure 2: Parasitic myomas over the anterior abdominal wall

lower abdomen on MRI, but the diagnosis of parasitic myomas was possible only at laparoscopy. Clark *et al.*^[3] diagnosed parasitic myoma with the help of MRI.

Management of parasitic myomas is usually excision. In our case, all parasitic myomas were excised without complications. Sometimes, parasitic myomas can be adherent to vital organs and excision can be risky. Takeda *et al.*^[1] had identified multiple parasitic myomas ranging from 1 to 6 cm in the lower abdomen; out of them, one myoma on the left pelvic sidewall was firmly attached to peritoneal tissue adjacent to the ureter. Since there was concern about the risk of ureteral injury, a ureteral stent was placed in the left ureter under cystoscopic observation before blunt dissection, and then the nodule was removed. Clark *et al.*^[3] had found two parasitic myomas. One (17.5 cm × 13 cm) was enwrapped in the sigmoid mesocolon and other (5.2 cm × 3.2 cm) was identified in the hepatorenal fossa, the decision was made to convert to a laparotomy. Both of these masses were carefully separated from the adjacent organs and excised. Excision of myomas was done in other studies also.^[1-3,9]

Since parasitic myomas grow from retained fragments of morcellated myomas, every attempt should be made to reduce fragmentation and dissemination during specimen removal. Mini-laparotomy and colpotomy with manual morcellation within a specimen bag are options to reduce the occurrence of parasitic myomas. Contained in-bag morcellation is another alternative to reduce this complication.^[5] If at all uncontained morcellation has to be performed, all residual fragments which may be buried under bowel or bladder or stuck in cannulas and wedged in the abdominal wall should be removed completely.^[10] We preferred to remove all the myomas by in-bag morcellation technique.

Laparoscopic myomectomy with uncontained tissue morcellation is a major risk factor for parasitic myomas. In patients with a history of laparoscopic morcellation who report pelvic symptoms, iatrogenic parasitic myomas as a late complication should be considered in the differential diagnosis. Meticulous surgical technique with systematic surveying of the entire cavity and complete retrieval of even small fragments of morcellated tissue should be practiced so as

not to iatrogenically increase the risk of morbidity associated with parasitic myomas.

Declaration of patient consent

The authors certify that they have obtained all appropriate patient consent forms. In the form, the patient has given her consent for her images and other clinical information to be reported in the journal. The patient understand that name and initial will not be published and due efforts will be made to conceal identity, but anonymity cannot be guaranteed.

Financial support and sponsorship

Nil.

Conflicts of interest

There are no conflicts of interest.

REFERENCES

1. Takeda A, Mori M, Sakai K, Mitsui T, Nakamura H. Parasitic peritoneal leiomyomatosis diagnosed 6 years after laparoscopic myomectomy with electric tissue morcellation: Report of a case and review of the literature. *J Minim Invasive Gynecol* 2007;14:770-5.
2. Paul PG, Koshy AK. Multiple peritoneal parasitic myomas after laparoscopic myomectomy and morcellation. *Fertil Steril* 2006;85:492-3.
3. Clark NV, Leon MG, Feltmate CM, Cohen SL. Parasitic leiomyomas following laparoscopic myomectomy. *CRSLS* 2017. [doi: 10.4293/CRSLS.2017.00018].
4. Tulandi T, Leung A, Jan N. Nonmalignant sequelae of unconfined morcellation at laparoscopic hysterectomy or myomectomy. *J Minim Invasive Gynecol* 2016;23:331-7.
5. Paul PG, Thomas M, Das T, Patil S, Garg R. Contained morcellation for laparoscopic myomectomy within a specially designed bag. *J Minim Invasive Gynecol* 2016;23:257-60.
6. Ostrzenski A. Uterine leiomyoma particle growing in an abdominal-wall incision after laparoscopic retrieval. *Obstet Gynecol* 1997;89:853-4.
7. Van der Meulen JF, Pijnenborg JM, Boomsma CM, Verberg MF, Geomini PM, Bongers MY, *et al.* Parasitic myoma after laparoscopic morcellation: A systematic review of the literature. *BJOG* 2016;123:69-75.
8. Stewart EA. Uterine fibroids. *Lancet* 2001;357:293-8.
9. Cucinella G, Granese R, Calagna G, Somigliana E, Perino A. Parasitic myomas after laparoscopic surgery: An emerging complication in the use of morcellator? Description of four cases. *Fertil Steril* 2011;96:e90-6.
10. Kho KA, Nezhat C. Parasitic myomas. *Obstet Gynecol* 2009;114:611-5.
11. Fasih N, Prasad Shanbhogue AK, Macdonald DB, Fraser-Hill MA, Papadatos D, Kielar AZ, *et al.* Leiomyomas beyond the uterus: Unusual locations, rare manifestations. *Radiographics* 2008;28:1931-48.