

Received: 2017.02.12  
Accepted: 2017.04.02  
Published: 2017.06.17

## Dieulafoy's Lesion of the Anal Canal: A Rare Cause of Lower Gastrointestinal Bleeding

Authors' Contribution:  
Study Design A  
Data Collection B  
Statistical Analysis C  
Data Interpretation D  
Manuscript Preparation E  
Literature Search F  
Funds Collection G

ABEF 1 **Ahmed Khalid**  
ABEF 1 **Husham Abdelrahman**  
BDE 1 **Syed Muhammad Ali**  
ABE 1 **Ejaz Ahmed Latif**  
BDE 1 **Hassan Al-Thani**  
DEF 2,3 **Ayman El-Menyar**

1 Department of Surgery, Trauma Surgery, Hamad General Hospital, Doha, Qatar  
2 Department of Surgery, Trauma Surgery, Clinical Research, Hamad General Hospital, Doha, Qatar  
3 Department of Clinical Medicine, Weill Cornell Medical College, Doha, Qatar

**Corresponding Author:** Ayman El-Menyar, e-mail: [Aymanco65@yahoo.com](mailto:Aymanco65@yahoo.com)  
**Conflict of interest:** None declared

### Case series

**Patient:** Male, 48 • Female, 85  
**Final Diagnosis:** Dieulafoy's lesion of the anal canal  
**Symptoms:** Bleeding per rectum  
**Medication:** —  
**Clinical Procedure:** Anoscopy or sigmoidoscopy  
**Specialty:** General Surgery

**Objective:** Challenging differential diagnosis


**Background:** Dieulafoy's lesion of the anal canal is an uncommon cause of lower gastrointestinal bleeding due to rupture of a submucosal artery. This could be an under-recognized cause of hemorrhagic shock in rare cases.

**Case Report:** We present 2 cases admitted with bleeding per rectum and hemorrhagic shock, and both were diagnosed as Dieulafoy's lesion of the anal canal on sigmoidoscopy. One case was treated surgically and the second was managed endoscopically.

**Conclusions:** Dieulafoy's lesion of the anal canal can be a source of massive lower gastrointestinal bleeding. Initial anoscopy or sigmoidoscopy might miss such a lesion. Proper visualization helps not only the diagnosis, but also the provision of therapeutic intervention in the same setting.

**MeSH Keywords:** Anal Canal • Endoscopy, Gastrointestinal • Gastrointestinal Diseases • Lower Gastrointestinal Tract

**Full-text PDF:** <http://www.amjcaserep.com/abstract/index/idArt/903735>



1301



—



2



16



## Background

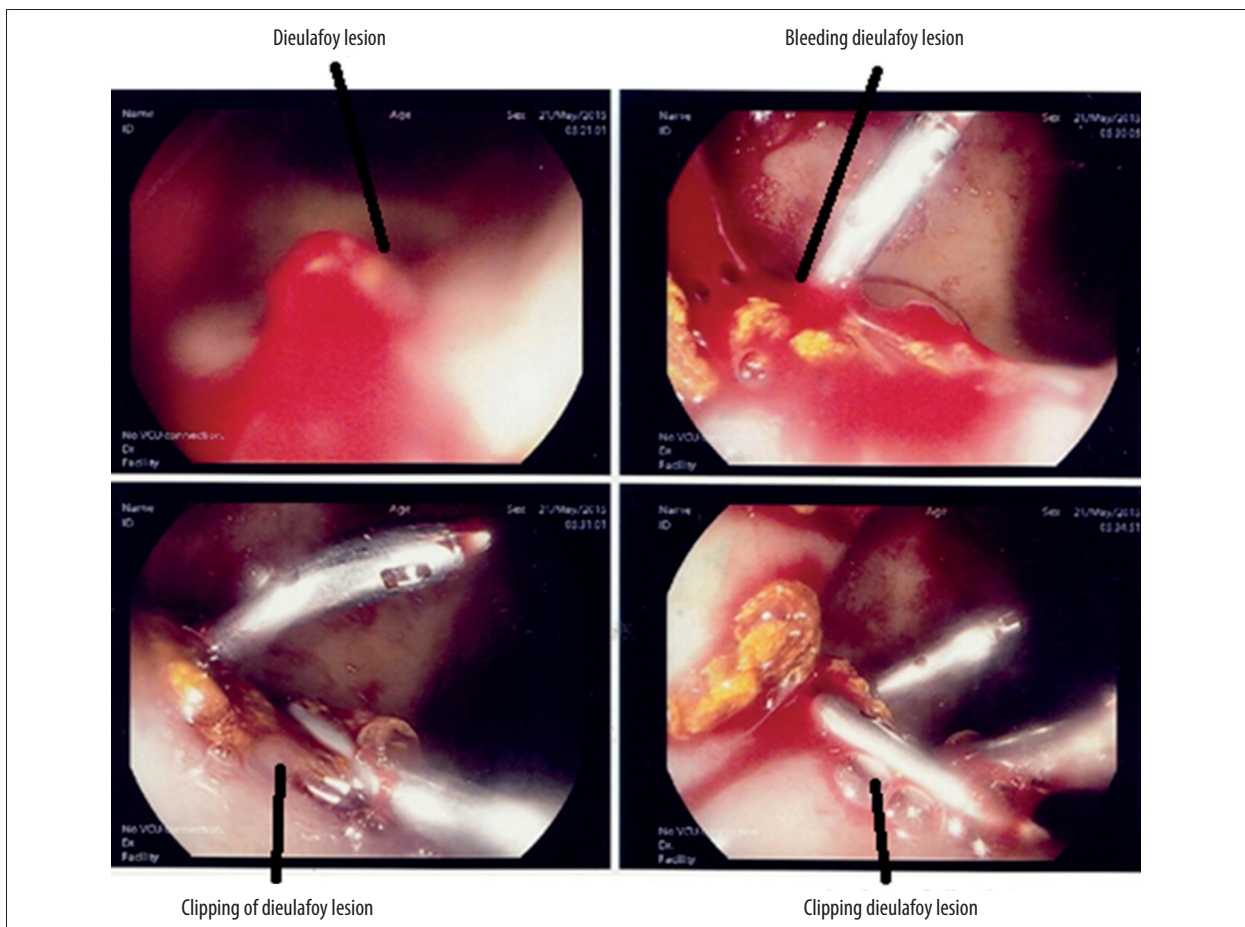
Dieulafoy's lesion of the anal canal is a rare surgical condition that can cause massive life-threatening lower gastrointestinal bleeding. It is defined as a dilated, aberrant, submucosal artery that disintegrates overlying mucosa in the absence of an underlying ulcer, aneurysm, or intrinsic mural abnormality [1]. Although it was initially described in the stomach, this lesion can occur in any part of the gastrointestinal tract. Dieulafoy's lesion of the anal canal is due to rupture of an exposed submucosal artery. This lesion can be treated endoscopically or surgically. Herein, we present 2 cases with Dieulafoy's lesion. This work has been reported according to the consensus-based surgical case report (SCARE) guidelines [2].

## Case Report

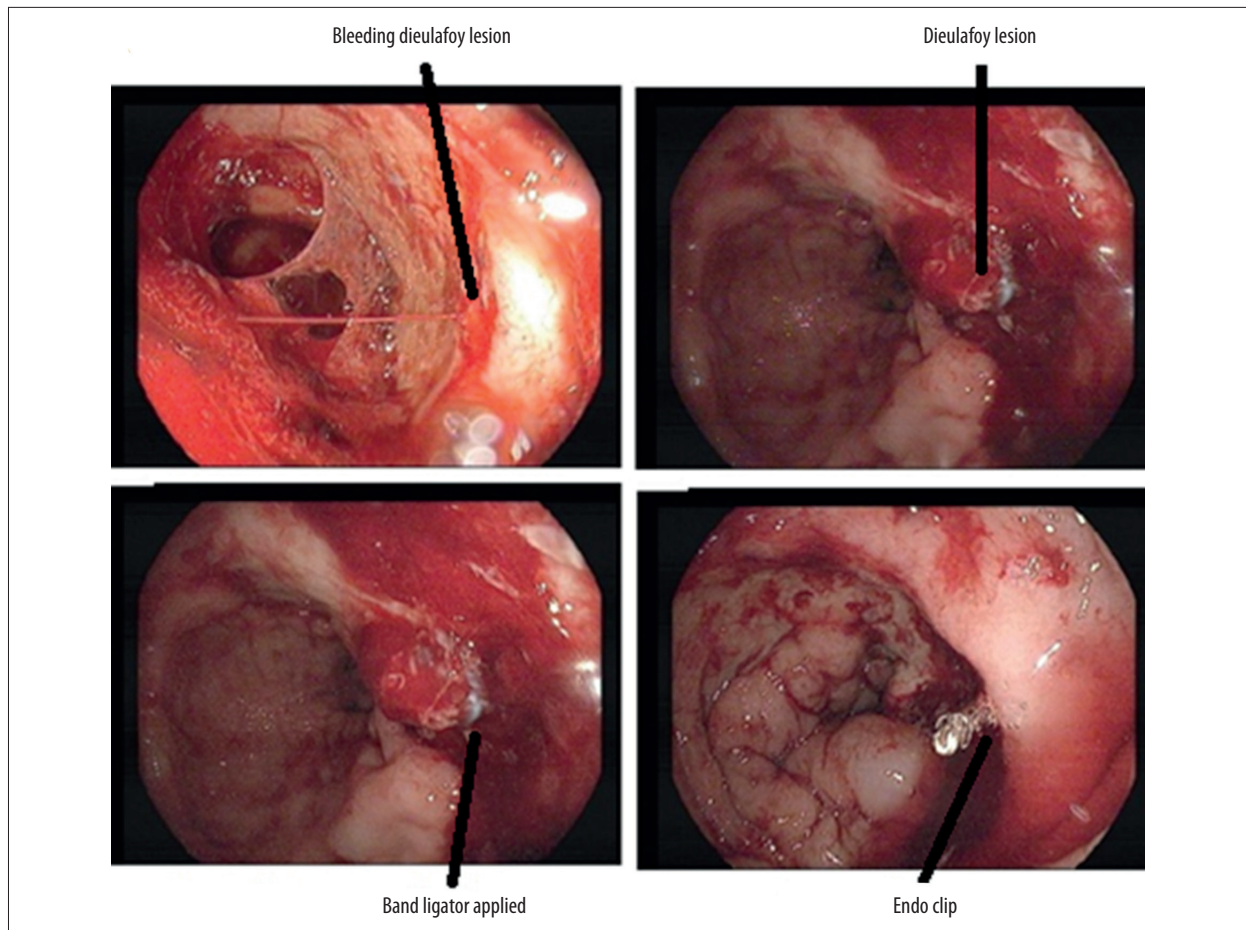
### Case No. 1

A 48-year old man with multiple co-morbidities (diabetes mellitus, hypertension, ischemic heart disease, peripheral arterial

disease, and end-stage renal disease on dialysis) presented to the Emergency Department with a 7-day history of progressive upper and lower limb weakness and was subsequently diagnosed as having Guillain-Barre syndrome. His condition deteriorated over the next few days; he had a cardiac arrest and was successfully resuscitated. On the 16<sup>th</sup> day of MICU admission, he started to have rectal bleeding. The patient became tachycardic (pulse 120/min) and hypotensive (BP 100/50). Abdominal examination was unremarkable; however, rectal examination showed fresh and profuse bleeding but no mass or lesion could be felt. Anoscopy could not see the site of bleeding because of excessive blood in the anal canal. He underwent emergency sigmoidoscopy, which showed a bleeding vessel in the posterior anal wall 4 cm from the anal verge (Figure 1). Given this critical situation, the initial decision was to perform minimal intervention. Adrenaline was endoscopically injected into the bleeding vessel, but it continued to bleed, and an Endoclip was applied to stop the bleeding. After 6 hours, the patient again started to have massive lower gastrointestinal bleed with tachycardia (hear rate 150 b/min) and hypotension (BP 80/40 mmHg). The immediate blood test showed hemoglobin level of 4.6; base deficit 11, and a lactate level of 9. An emergency



**Figure 1.** Case 1: Emergency sigmoidoscopy showed a bleeding vessel at the posterior anal wall 4 cm from the anal verge.



**Figure 2.** Case 2: Sigmoidoscopy showed a bleeding vessel at the posterior anal wall.

resuscitation was started, including transfusion of packed red blood cell (PRBCs), platelets, and fresh frozen plasma (FFP). He underwent sigmoidoscopy again, which showed bleeding from the same vessel. An Endoclip was again applied, but it failed. After failed endoscopic treatment, the bleeding vessel was over-sewn using Vicryl, which stopped the bleeding. The resuscitation was continued until the patient was stabilized. During this 16-hour episode, his hemoglobin dropped from 9.8 to 4.6. He received 8 units of PRBCs, 8 units FFP, and 12 units of platelets, and the last hemoglobin was 10.8 after stabilization, with normal vital signs. There was no recurrence of bleeding after this episode.

#### Case No: 2

An 85-year-old woman with multiple co-morbidities (diabetes mellitus, hypertension, osteoarthritis, deep vein thrombosis) was admitted with acute dyspnea, tachycardia, and tachypnea, with desaturation and right leg swelling. She was diagnosed as having pulmonary embolism on a CT angiogram and was admitted for further management into the medical unit. On the 10<sup>th</sup> day of her hospital admission, she started

to have profuse rectal bleeding. She became hypotensive (BP 90/40 mmHg) and tachycardic (heart rate 110/min). Physical examination showed unremarkable abdomen and chest. A rectal examination showed profuse fresh bleeding. Her hemoglobin dropped from 9.2 to 7.5 g/dl. She was moved immediately to the endoscopy unit. Sigmoidoscopy showed a Dieulafoy's lesion with an active bleeding spurter above the anal verge. Initially, 1 band ligator was applied, but there was still oozing; therefore, an Endoclip was applied (Figure 2). The patient was moved back to the medical unit and there was no further episode of rectal bleeding.

#### Discussion

Dieulafoy's lesion of the gastrointestinal tract commonly occurs in the stomach (70%) and rarely develops in the ano-rectal region [1]. It causes bleeding in the gastrointestinal tract (1.5% of acute upper GI bleeding and 3.5% of jejunoileal GI bleeding) [1]. Although it is very distal, the lesion maintains a constant arterial caliber (1–3 mm) [1].

The exact cause of Dieulafoy's lesion in the anal canal is unclear, but the following hypotheses have been suggested: (a) it is a congenital malformation [3]; (b) submucosal venous pulsation causes damage to the epithelium and local ischemia, followed by erosion and vascular rupture [4]; and (c) arterial thrombosis results in necrosis, followed by bleeding [4]. It has also been proposed that the solid fecal content in the intestine and rectum initiates the development of mucosal ulceration and submucosal artery dilatation, resulting in bleeding [4]. Additionally, mucosal atrophy in elderly patients may contribute to this process [5,6].

The endoscopic diagnosis of Dieulafoy's lesion is based on certain criteria, including: (a) normal mucosa nearby the small defected mucosal lesion, which has active pulsatile bleeding <3 mm; (b) occurrence of protruded vein; and (c) the presence of a fresh clot attached to a mucosal defect [7,8]. Diagnosis of the lesion occurs in 70% of patients with the first endoscopy [9]. However, lesions in the anal canal pose difficulties due to profuse bleeding and poor visualization [4]. Our diagnosis was Dieulafoy's lesion and not simply hemorrhoids based on the endoscopic picture of Dieulafoy's lesion, which is normal mucosa near a small mucosal lesion which has active pulsatile bleeding <3 mm, whereas hemorrhoids appear as bulging purplish-blue veins without a spurter [10].

The first-line treatment for Dieulafoy's lesion in the anal canal is endoscopy, since it is successful in 90% of cases [8,9]. Endoscopic therapy includes thermal electro-coagulation, local epinephrine injection, sclerotherapy, mechanical banding, and clip application [11–13]. The surgical treatments are over-sewing [14], suture ligation, or wedge excision in the form of hemorrhoidectomy [15]. The recurrent bleeding risk in patients with Dieulafoy's lesion has been reported as 9–40% [7,9]. After endoscopic therapy failure, repeat endoscopic therapy, angiography, or surgical wedge resection are alternatives [1]. A management algorithm has been suggested [10]. It should start with resuscitation and stabilization, followed by endoscopic evaluation as lesion can be identified and treated endoscopically. If this fails, surgery is the alternative. If the lesion cannot be identified endoscopically, then angiography (or CT

angiography or red cell scan or capsule endoscopy) ± embolization or surgery can be performed [10].

Azimuddin et al. [15] reported 2 cases of Dieulafoy's lesion of the anal canal that presented with sudden onset of massive hemorrhage. In one case, the bleeding was controlled by over-sewing ligation of the bleeding arteriole, while the other patient was taken to the operating room and the lesion was excised in continuity with the hemorrhoidal complex [15]. As surgical rescue is a good option if the first fails, the appropriate place for the initial treatment of these lesions could be in the operating room, where the endoscopic procedure can be easily converted into transanal surgery if needed.

Firat et al. [16] reported a case of Dieulafoy's lesion of the anal canal, in which the patient had massive hematochezia requiring multiple blood transfusions. Surgical over-sewing was attempted twice but rebleeding occurred, and local excision through the anal canal was performed [16]. Therefore, because the arterial bleeding was recurrent and life-threatening, local excision could be a reliable management approach. In our case, the endoscopic treatment with epinephrine injection followed by clipping the lesion twice failed, and was treated with over-sewing that stopped the bleeding in 1 case. On the other hand, the endoscopic treatment with banding and clipping stopped the bleeding in the other patient, who presented with the same lesion. The overall mortality rate in the literature shows a decline from 30% to ~9%, which reflects the efficacy of endoscopic therapy [1].

## Conclusions

Dieulafoy's lesion of the anal canal can be a source of massive lower gastrointestinal bleeding. Initial anoscopy or sigmoidoscopy might miss such a lesion. Proper visualization would help not only the diagnosis, but also the provision of therapeutic intervention on the same setting.

## Conflict of interests

None.

## References:

1. Nojkov B, Cappell MS: Gastrointestinal bleeding from Dieulafoy's lesion: Clinical presentation, endoscopic findings, and endoscopic therapy. *World J Gastrointest Endosc*, 2015; 7(4): 295–307
2. Agha RA, Fowler AJ, Saeta A et al., SCARE Group: The SCARE Statement: Consensus-based surgical case report guidelines. *Int J Surg*, 2016; 34: 180–86
3. Ma CK, Padda H, Pace EH, Szilagyi E: Submucosal arterial malformation of the colon with massive hemorrhage. Report of a case. *Dis Colon Rectum*, 1989; 32(2): 149–52
4. Dogan U, Gomceli I, Koc U et al: Rectal Dieulafoy's lesions: A rare etiology of chronic lower gastrointestinal bleeding. *Case Rep Med*, 2014; 2014: 180230
5. Chaer RA, Helton WS: Dieulafoy's disease. *J Am Coll Surg*, 2003; 196(2): 290–96
6. Stark ME, Gostout CJ, Balm RK: Clinical features and endoscopic management of Dieulafoy's disease. *Gastrointest Endosc*, 1992; 38(5): 545–50
7. Morowitz MJ, Markowitz R, Kamath BM, von Allmen D: Dieulafoy's lesion and segmental dilatation of the small bowel: An uncommon cause of gastrointestinal bleeding. *J Pediatr Surg*, 2004; 39(11): 1726–28
8. Lee YT, Walmsley RS, Leong RW, Sung JJ: Dieulafoy's lesion. *Gastrointest Endosc*, 2003; 58(2): 236–43

9. Marangoni G, Cresswell AB, Faraj W et al: An uncommon cause of life-threatening gastrointestinal bleeding: 2 synchronous Dieulafoy lesions. *J Pediatr Surg*, 2009; 44(2): 441–43
10. Baxter M, Aly EH: Dieulafoy's lesion: Current trends in diagnosis and management. *Ann R Coll Surg Engl*, 2010; 92(7): 548–54
11. Chung IK, Kim EJ, Lee MS et al: Bleeding Dieulafoy's lesions and the choice of endoscopic method: Comparing the hemostatic efficacy of mechanical and injection methods. *Gastrointest Endosc*, 2000; 52(6): 721–24
12. Yeoh KG, Kang JY: Dieulafoy's lesion in the rectum. *Gastrointest Endosc*, 1996; 43(6): 614–16
13. Iacopini F, Petruzzello L, Marchese M et al: Hemostasis of Dieulafoy's lesions by argon plasma coagulation (with video). *Gastrointest Endosc*, 2007; 66(1): 20–26
14. Rajendra T, Chung YF, Ong HS: Rectal Dieulafoy's lesion: Cause of massive lower gastrointestinal tract haemorrhage. *Aust NZJ Surg*, 2000; 70(10): 746–47
15. Azimuddin K, Stasik JJ, Rosen L et al: Dieulafoy's lesion of the anal canal: A new clinical entity. Report of two cases. *Dis Colon Rectum*, 2000; 43(3): 423–26
16. Firat O, Karaköse Y, Calışkan C et al: Dieulafoy's lesion of the anal canal: Report of a case. *Turk J Gastroenterol*, 2007; 18(4): 265–67