



Case report

Application of spatial replacement method in the treatment of laparoscopic incarcerated femoral hernia – A case report

Binyu Luo, Xiao Zhang, Qing Guo, Yunhong Tian, Mingyang Ren, MD*

Department of Gastrointestinal Surgery, The Affiliated Nanchong Central Hospital of North Sichuan Medical College, Nanchong 637000, Sichuan, China

ARTICLE INFO

Keywords:

Incarcerated femoral hernia
Spatial replacement
Laparoscopy
Surgery
Case report

ABSTRACT

Introduction: Incarcerated femoral hernia is a common surgical acute abdominal disease. Laparoscopic surgery is considered a safe and effective method for treating incarcerated femoral hernias, which have different surgical approaches to releasing the contents of the hernia.

Presentation of case: We report the case of a 65-year-old female with a right incarcerated femoral hernia with an irreducible mass in the right femoral region for 2 days diagnosed by physical examination and abdominal ultrasonography. We used a catheter to inject normal saline into the hernia sac during surgery. Injury and rupture of the small intestine were avoided, and the polypropylene mesh was successfully repaired.

Discussion: Incarcerated femoral hernias is a common surgical emergency that can lead to intestinal obstruction, strangulation, or infarction. Laparoscopy is advantageous for treating incarcerated femoral hernias. In our case, spatial replacement theory was used to release the incarcerated small intestine. The principle is that changing the internal and external pressures of the hernial sac returns the hernia contents. The non-necrotic small intestine did not lead to intraperitoneal infection, and the standard transabdominal preperitoneal repair was simultaneously performed with a polypropylene mesh.

Conclusion: Laparoscopic incarcerated femoral hernia repair is a common emergency surgery that is safe and feasible for treating incarcerated femoral hernia using the spatial replacement method, the most beneficial to patients.

1. Introduction

Incarcerated inguinal hernia, a common surgical emergency, is an unreduced abdominal wall hernia, accounting for 5–15 % of abdominal hernias. Femoral hernias are rare, accounting for 3–4 % of all inguinal hernias [1]. Although the incidence of femoral hernia is low, intestinal necrosis is likely to occur once incarcerated femoral hernia occurs. The potentially necrotic content might lead to bowel perforation, abdominal infection, and even fatal sepsis if not operated [2]. Laparoscopic treatment of incarcerated hernias did not increase morbidity and mortality and was associated with a shorter hospital stay, faster recovery, and no recurrence [3]. However, the incarcerated small intestine can be easily damaged during treatment, resulting in the spread of abdominal infection. This article introduces the spatial replacement theory to release the incarcerated small intestine. This procedure was performed at an academic hospital, and the case report aligns with Surgical Case Report criteria [4].

2. Presentation of case

We report the case of a 65-year-old female with a right incarcerated femoral hernia and an irreducible mass in the right inguinal region for 2 days. She had no history of trauma and had been presenting with a reducible hernia for 2 years. The patient's abdomen was soft and nontender, with hyperactive bowel sounds during the examination. Abdominal computed tomography (CT) showed intestinal inclusions in the hernia sac with edema and dilatation of the proximal small intestine. The patient was systemically well, a right incarcerated femoral hernia was found laparoscopically, and the hernia contents were the small intestine. The incarcerated intestine cannot be released by internal pull and extrapolation, and violence can easily damage it (Fig. 1). An 8# rubber catheter tip was inserted into the hernia sac through the right trocar, and 15–20 mL of normal saline was injected into the hernia sac through the rubber catheter simultaneously. It must be noted that the operation needs to be gentle, and when there is resistance, violent damage to the bowel must be avoided by stopping the procedure

* Corresponding author.

E-mail addresses: luobinyu2014@126.com (B. Luo), 2861746489@qq.com (M. Ren).<https://doi.org/10.1016/j.ijscr.2022.107535>

Received 24 July 2022; Received in revised form 12 August 2022; Accepted 18 August 2022

Available online 22 August 2022

2210-2612/© 2022 Published by Elsevier Ltd on behalf of IJS Publishing Group Ltd. This is an open access article under the CC BY-NC-ND license (<http://creativecommons.org/licenses/by-nc-nd/4.0/>).

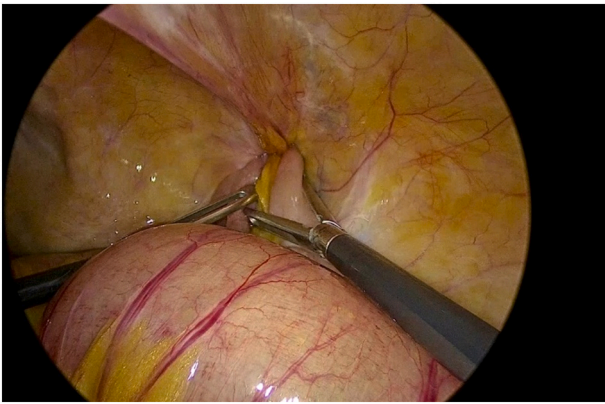


Fig. 1. Right incarcerated femoral hernia; the contents of the hernia were the small intestine that could not be released.

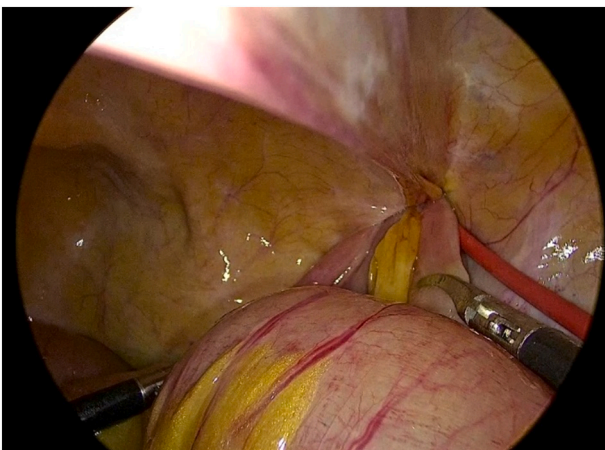


Fig. 2. Inserted the tip of an 8# rubber catheter into the hernia sac and injected 15–20 mL normal saline.

(Fig. 2). The incarcerated small intestine was replaced by the principle of spatial replacement to avoid iatrogenic injury to the small intestine. The principle is that changing the internal and external pressures of the hernia sac returns the hernia contents (Fig. 3). We performed standard transabdominal preperitoneal repair using a polypropylene mesh because there was no spread of intraperitoneal infection (Fig. 4). Her

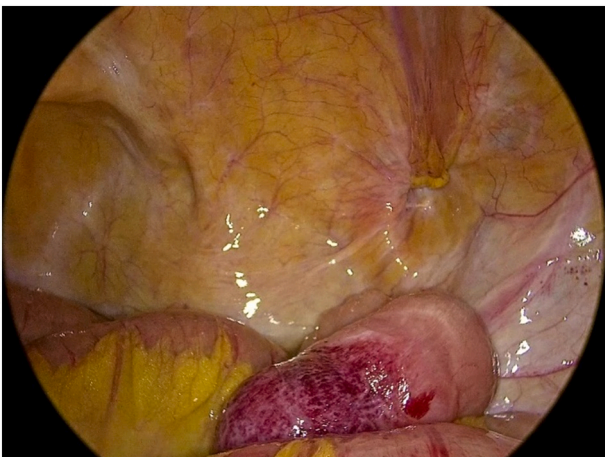


Fig. 3. Release of the incarcerated small intestine by spatial displacement principle.

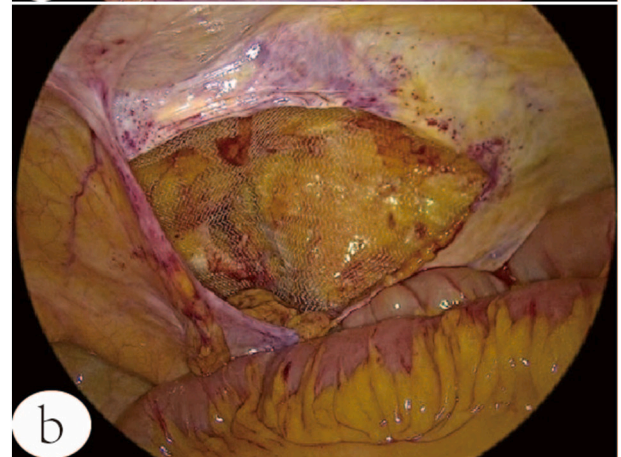
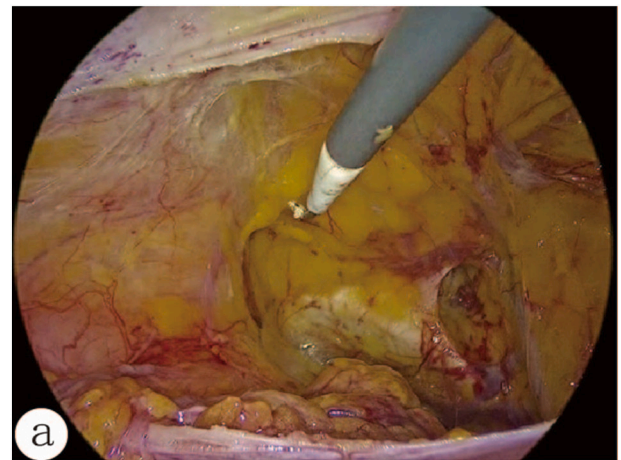


Fig. 4. (a) myopectineal orifice after dissection, (b) fixation with polypropylene mesh covering the myopectineal orifice.

post-operative recovery was uneventful; she was discharged soon after the operation and quickly returned to daily life.

3. Discussion

Femoral hernias are relatively uncommon, and the incidence rate of adult femoral hernias is approximately 2–8 %. Due to the wide pelvic structure, femoral hernias are more common in females than males. The ratio of females to males is 4:1. Femoral hernias account for approximately 2–4 % of all inguinal hernias [5]. Approximately 60 % of femoral hernias are found on the right side, 30 % on the left side, and 10 % bilaterally. The incarceration/strangulation rate of femoral hernia is between 44 % and 86 %, and 30.4–45.9 % of femoral hernias present as surgical emergencies with high rates of exploratory laparotomy for segmental resection of the intestine and primary end-to-end anastomosis [6]. Patients with bowel necrosis have significantly longer hospitalization and higher post-operative complications, ranging from 6 % to 43 %, with a mortality rate of 1–7 % [7,8]. An incarcerated femoral hernia can easily cause small-intestinal necrosis; therefore, emergency surgery is needed. In most cases, the non-mesh repair technique was frequently considered to avoid any possible mesh infection after surgery, such as those utilized in McVay repair. However, incarcerated hernia contents may return to the abdominal cavity owing to anesthetics and muscle relaxants, leading to potential necrotic contents that may lead to intestinal perforation, abdominal infection, or fatal sepsis. The introduction of laparoscopic techniques has greatly sharpened the surgical paradigm and is more prevalent in hernia surgery, with plausible clinical outcomes [9]. Using a laparoscope can facilitate the direct assessment of an incarcerated bowel, and the viability of the bowel can be evaluated [10].

However, in releasing the incarcerated small intestine, iatrogenic intestinal injury can easily occur, which may cause rupture, leading to abdominal infection. At our Hernia Treatment Center, we successfully released the incarcerated small bowel using a spatial replacement method. The principle is that the negative pressure of the hernia sac is eliminated by injecting normal saline so that the internal and external pressures of the hernia sac are equal. As the injected normal saline increases, the internal pressure becomes higher than the external pressure, which is conducive to the recovery of the hernia contents. As the hernia contents are returned, an increasing volume of normal saline enters the hernia sac, and finally, the hernia contents are returned. No small-bowel rupture or infection results. In addition, the condition can be treated with transabdominal polypropylene mesh preperitoneal repair [11]. All problems can be solved simultaneously without iatrogenic injury, which benefits the patient's healing and avoids secondary surgery.

4. Conclusion

The spatial replacement method is safe and effective in assisting the laparoscopic release of incarcerated hernia contents and is worthy of clinical promotion.

Funding

No funding.

Ethics approval

This study is exempt from ethical approval.

Consent

Written informed consent was obtained from the patient for publication of this case report and accompanying images. A copy of the written consent is available for review by the Editor-in-Chief of this journal on request.

CRediT authorship contribution statement

1. Binyu Luo: chief surgeon, wrote the manuscript, conceived and designed research, and collected the references.

2. Xiao Zhang and Qing Guo: Surgical assistant, analyzed data and manuscript review.

3. Yunhong Tian and Mingyang Ren: clinical supervision and manuscript review and editing.

All authors read and approved the manuscript.

Guarantor

Binyu Luo

Registration of research studies

N/a.

Declaration of competing interest

Not applicable.

Appendix A. Supplementary data

Supplementary data to this article can be found online at <https://doi.org/10.1016/j.ijscr.2022.107535>.

References

- [1] J. Coelho, et al., Femoral hernia: uncommon, but associated with potentially severe complications, *Arq. Bras. Cir. Dig.* 34 (2) (2021), e1603.
- [2] T. Kalayci, U.H. Iliklerden, M.C. Kotan, Factors affecting morbidity, mortality, and recurrence in incarcerated femoral hernia, *J. Coll. PhysiciansSurg. Pak.* 32 (2) (2022) 213–219.
- [3] R. Okazaki, et al., Laparoscopic approach as a safe and effective option for incarcerated femoral hernias, *Asian J. Endosc. Surg.* 15 (2) (2022) 328–334.
- [4] R.A. Agha, et al., The SCARE 2020 guideline: updating consensus Surgical CAsE REport (SCARE) guidelines, *Int. J. Surg.* 84 (2020) 226–230.
- [5] A. Goethals, C.E. Azmat, C.T. Adams, Femoral Hernia, 2022.
- [6] D.J. Humes, et al., Population-based study of presentation and adverse outcomes after femoral hernia surgery, *Br. J. Surg.* 100 (13) (2013) 1827–1832.
- [7] P. Chen, et al., Risk factors for bowel resection among patients with incarcerated groin hernias: a meta-analysis, *Am. J. Emerg. Med.* 38 (2) (2020) 376–383.
- [8] M. Koizumi, et al., Optimal timeline for emergency surgery in patients with strangulated groin hernias, *Hernia* 18 (6) (2014) 845–848.
- [9] J. Payiziwula, et al., Laparoscopy versus open incarcerated inguinal hernia repair in octogenarians: single-center experience with world review, *Surg. Laparosc. Endosc. Percutan. Tech.* 29 (2) (2019) 138–140.
- [10] Y. Tsuchiya, et al., Case of incarcerated femoral hernia treated with laparoscopic surgery after groin hernia repair, *Case Rep. Gastroenterol.* 15 (1) (2021) 35–40.
- [11] R. Mancini, G. Pattaro, E. Spaziani, Laparoscopic trans-abdominal pre-peritoneal (TAPP) surgery for incarcerated inguinal hernia repair, *Hernia* 23 (2) (2019) 261–266.