

Infection mimicking skin condition: pyoderma gangrenosum

Ellen Burlage,¹ Janneke W. C. M. Mulder,² Jorm M. Nellensteijn,¹
Adelgunde V. C. M. Zeegers¹

¹Orthopaedic Surgery, Medisch Spectrum Twente, Enschede, The Netherlands

²Internal Medicine, Erasmus Medical Center, Rotterdam, The Netherlands

Correspondence to

Dr Adelgunde V. C. M. Zeegers; a.zeegers@mst.nl

Accepted 5 July 2022

SUMMARY

The a priori risk of infection is high when a patient presents with an ulcerative skin condition and elevated inflammatory parameters. If the ulceration is progressive despite adequate antibiotic therapy and tissue cultures are negative, pyoderma gangrenosum should be considered as the diagnosis. This rare infection mimicking skin condition can develop and worsen due to surgery. In this paper, we report two cases that illustrate the importance of making this clinical diagnosis in a timely manner in order to avoid unnecessary surgical interventions and worsening of the clinical picture.

BACKGROUND

Pyoderma gangrenosum (PG) is a rare and often infectious-looking skin condition.¹ Although the pathophysiology is not yet fully understood, it appears to most closely resemble an auto-inflammatory mechanism. In recent years, PG has been described more frequently, but nevertheless, the diagnosis often proves to be difficult. In infectious skin conditions, the treatment is often aimed at combatting bacterial pathogens by antibiotic therapy and surgical debridement, but this can have major ramifications for the patient with PG.² Therefore, it is important to come to an early diagnosis to prevent iatrogenic deterioration.

CASE PRESENTATION

Patient A, a man in his early 70s, presented to the emergency department (ED) with wound leakage 10 days after an uncomplicated total hip arthroplasty (THA). Medical history only mentioned the recent THA. Since the procedure, the patient used dalteparin once a day, according to the hospital protocol, to prevent thromboembolic events and oral morphine 5 mg two times per day to reduce pain. Wound leakage started two days before presentation to the ED on the eighth day after surgery. Wound leakage rapidly increased and pain worsened in the 48 hours before presentation to the ED. The patient did not remove the postoperative dressing by himself.

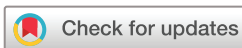Physical examination revealed a wound with undermined borders, peripheral erythema and cream-coloured wound leakage. Laboratory results were abnormal with increased C reactive protein (CRP) (302 mg/L, reference value: 0–10 mg/L), increased erythrocyte sedimentation rate (ESR) (67 mm/hour, reference value: <20 mm/hour) and a leucocytosis ($34.1 \times 10^9/L$, reference value: $3.8\text{--}10.6 \times 10^9/L$). Suspecting a periprosthetic joint

infection (PJI), a debridement, antibiotics and implant retention (DAIR) was performed. After collecting tissue cultures, 1000 mg of cefazolin was administered intravenously.

Two days postoperatively, a progressively expanding ulcer developed around the operation wound with undermined blue-purple edges, necrotic skin and bloody, cream-coloured oozing, despite adequate infection treatment (figure 1). Suspicion of infection persisted, and the patient was readmitted for a second DAIR procedure. Due to the substantial risk of recurrent infection, the decision was made to completely remove the THA, a drastic decision in terms of the patient's independence. After excessive debridement, negative pressure wound therapy was used for wound management. Nonetheless, the ulcer progressively worsened again and the diagnosis of PJI had to be reconsidered even though tissue cultures remained negative. The dermatologist was consulted and diagnosed PG. Presence of an ulcer with undermined blue-purple wound edges, aggravated by surgery, and exclusion of other causes (also see box 1) supported the diagnosis of PG.

Patient B, a woman in her late 40s, presented at the orthopaedics department with an ulcer distal to the left lateral malleolus. Medical history reported ulcerative colitis and hypertension. She was taking mesalazine for her colitis, but had stopped taking this medication 1 month prior due to side effects such as myalgia. At that time, she had no gastrointestinal symptoms. Three months before presentation at the hospital, the patient consulted the general practitioner regarding a small skin defect on her ankle. Despite surgical debridement and treatment with antibiotics (e.g. augmentin and flucloxacillin), the skin defect worsened. The vascular surgeon found no vascular cause for the wound. Ankle-brachial pressure index was normal and there were no signs of venous insufficiency. Also, the rheumatologist was consulted to exclude rheumatic diseases as cause for the ulcer, which could have been a possible skin manifestation. The laboratory analysis, including cyclic citrullinated peptide antibody and rheumatoid factor tests, did not show any signs of rheumatic diseases.

On physical examination, the orthopaedic surgeon noticed a fluctuating mass distal to the lateral malleolus with two papules and peripheral erythema. An MRI was made, showing oedema on the lateral side of the ankle, osteoarthritis and extensive synovitis. Infection parameters were slightly raised (ESR 44 mm/hour, leucocytes $6.09 \times 10^9/L$



© BMJ Publishing Group Limited 2022. No commercial re-use. See rights and permissions. Published by BMJ.

To cite: Burlage E, Mulder JWCM, Nellensteijn JM, et al. *BMJ Case Rep* 2022;**15**:e247770. doi:10.1136/bcr-2021-247770

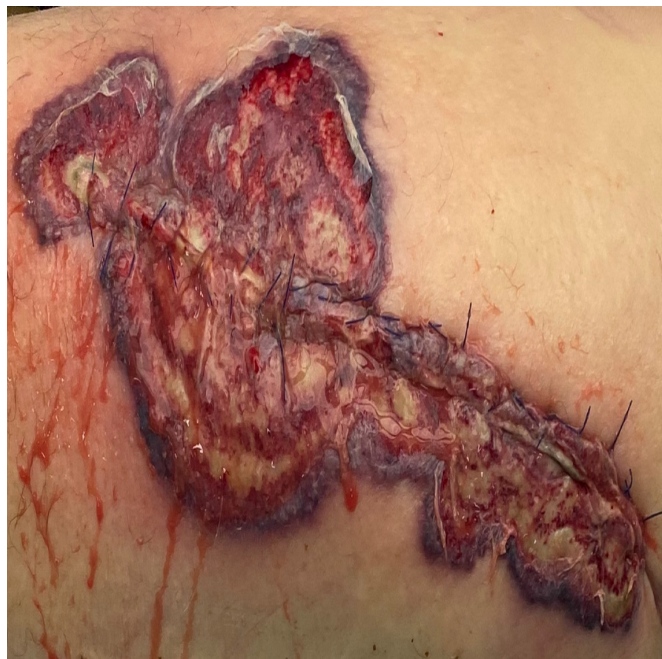

Figure 1 Ulcer around the operation wound on the hip with undermined blue-purple edges and peripheral erythema 3 days after debridement, antibiotics and implant retention procedure.

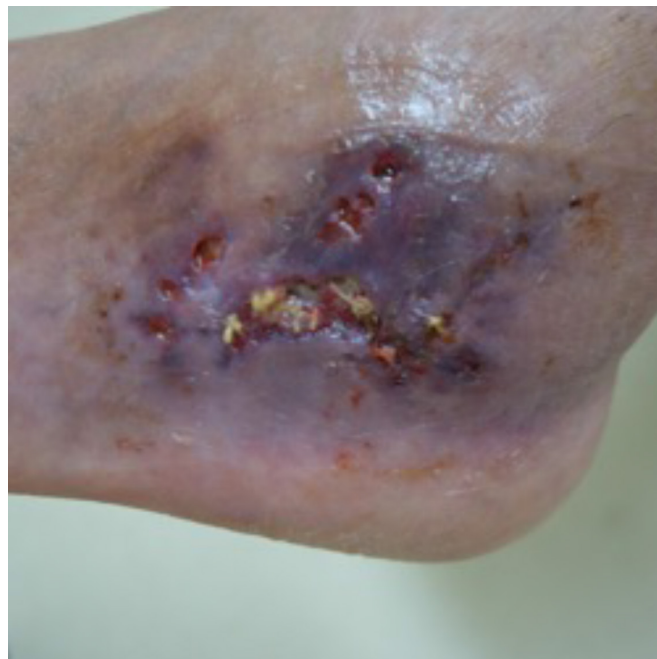


Figure 2 Pyoderma gangrenosum at the lateral malleolus. Multiple ulcerations with swelling, undermined wound edges and blue-purple skin.

and CRP 41 mg/L). To provide rest for the ankle joint, a plaster cast was given. However, 1 week after cast treatment, the papules had transformed into large ulcers with purple undermined edges and swelling (figure 2). Hence, incision and drainage followed, and cefazolin was started. New wound cultures were taken, but remained negative. Perioperatively, biopsies were obtained from the ulcer base and synovial sheath of the peroneal tendons. They showed an active chronic inflammation and cell infiltrate with neutrophils. After creating a new intravenous access site at the elbow, similar ulcers appeared near and at the access site. The dermatologist was consulted and concluded the diagnosis of PG based on the findings from histology, the purple undermined borders of the wound, the pathergic reaction after creating intravenous access and the negative tissue cultures.

DIFFERENTIAL DIAGNOSIS

In both cases, a bacterial infectious cause was initially suspected. In the case of patient A, the clinical suspicion of an acute PJI was very strong due to wound leakage and increased inflammatory parameters after a recent THA. In the case of necrotic skin, a differential diagnosis of necrotic fasciitis should be considered. This condition is characterised by the acute onset of severe local pain with extensive necrosis within 24–48 hours. If not

surgically treated, the patient may develop a fatal septic shock.³ Necrotic fasciitis was unlikely, because the pain was not prominent in these cases and the skin defects did not develop acutely. Skin ulcers are also seen in venous or arterial insufficiency. The preferred location of a venous insufficiency ulcer is above the medial malleolus. Patients with arterial insufficiency have intermittent claudication. On physical examination, the affected limb may be cold or pale with weak pulses and an ankle-arm index <0.9. The defect on the lateral malleolus made a venous cause less likely for patient B. An arterial cause could also be ruled out because there were no anamnestic symptoms of intermittent claudication and the ankle-arm index was normal (see box 1 for a list of differential diagnoses for PG).¹⁴

TREATMENT

Patient A: daily administration of 60 mg prednisone was initiated immediately, which showed good response. Infliximab (tumour necrosis factor- α blocker) treatment was also started to expedite further recovery (figures 3 and 4).

Patient B: antibiotics were stopped and the patient received treatment with prednisone and daily local application of clobetasol propionate lotion, which showed good results (figure 5).

OUTCOME AND FOLLOW-UP

Patient A: 1 month after presentation to the ED, the patient was discharged from hospital with home care. After 2 months of PG treatment, the skin ulcer had healed sufficiently (figure 4). The patient was scheduled for a skin graft and to consecutively reimplant the THA in a second procedure. Additionally, the patient was referred to the internal medicine outpatient clinic to investigate the presence of an underlying disease. The patient had no signs of inflammatory arthritis. Complete blood count with analysis of leucocytes count showed normal distribution. Also, total serum protein was not elevated, and serum free light chain testing showed normal values and ratio. Sigmoidoscopy

Box 1 Differential diagnosis in pyoderma gangrenosum

- ▶ **Infections:** viral, bacterial, mycobacterial, parasitic, fungal.
- ▶ **Malignancies:** skin carcinoma (e.g. squamous cell carcinoma, basal cell carcinoma), leukaemia.
- ▶ **Vascular:** Venous or arterial insufficiency, systemic vasculitis (e.g. Behcet's disease).
- ▶ **Systemic disorders:** systemic lupus erythematosus, rheumatoid arthritis, Sweet syndrome.
- ▶ **Other:** insect bite, drug reaction, self-mutilation.

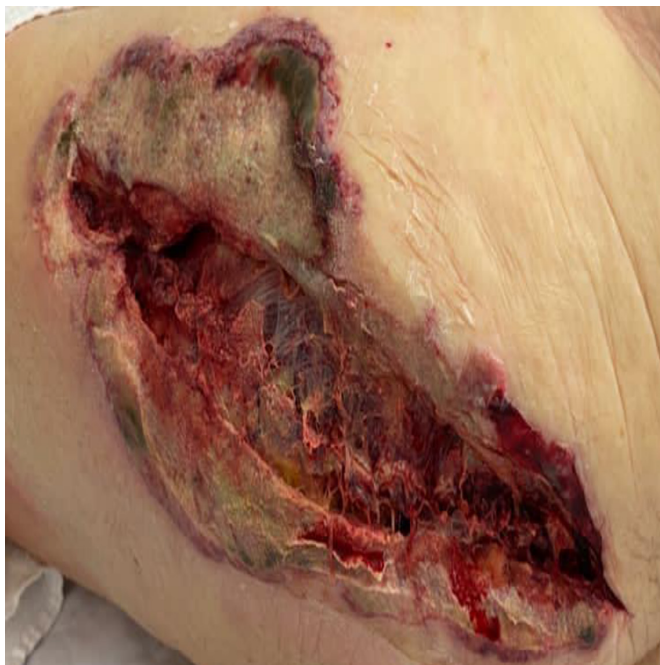

Figure 3 Picture of the left hip a few days after removal of the total hip arthroplasty, surgical debridement and starting with prednisone therapy. The wound edges are less irritated and erythema is reduced.

was planned to investigate the presence of an underlying inflammatory bowel disease. Unfortunately, the patient died from the consequences of COVID-19 before the interventions and further investigations could take place.

Patient B: a few weeks after prednisone initiation, the skin was healed. Consequently, the dose of prednisone was reduced. However, this unfortunately resulted in increased activity of PG. Ciclosporin was added to prednisone, which at first showed a good clinical response. Unfortunately, it also caused kidney

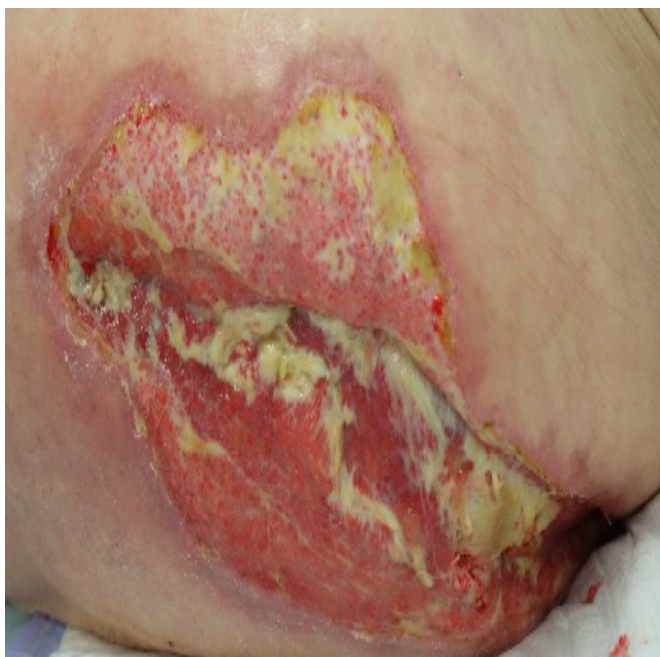

Figure 4 Improvement of the skin at the left hip 1.5 months after treatment with prednisone and infliximab.

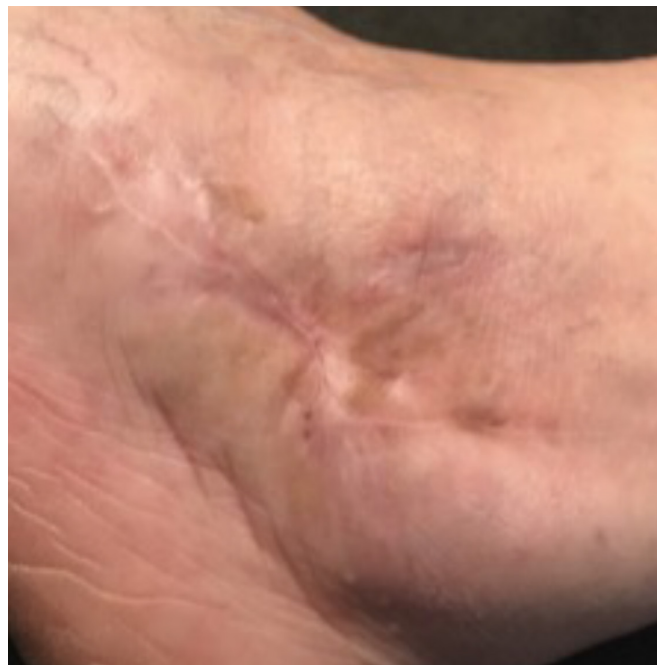

Figure 5 Complete resolution of pyoderma gangrenosum at the lateral malleolus several months after starting treatment with prednisone and adalimumab.

failure and therefore had to be discontinued again. Because the results with prednisone alone were insufficient, adalimumab injections were started (figure 5). Currently, more than a year after PG diagnosis, the patient has to use daily 3 mg prednisone and adalimumab injections two times per week to prevent recurrence of PG.

DISCUSSION

PG is a rare condition characterised by rapidly evolving ulceration. The incidence of PG is estimated to be 3–10 patients per million per year with a peak incidence between age 20 and 50 years. Women appear to be more frequently affected than men.⁴

The clinical picture was first described in 1930.⁵ Initially, the aetiology was thought to be of infectious nature, however, later it became clear that PG is caused by sterile inflammation of the skin.⁴ The true pathophysiology of PG is not yet understood, yet it appears to most closely resemble an aberrant immune response of neutrophils and inflammatory mediators.⁶ Approximately 50% of patients with PG also have an underlying systemic disease. PG is associated with inflammatory arthritis, inflammatory bowel diseases and haematological malignancies.⁷ In case of patient A, blood tests for haematological disease (ie, white cell count, total serum protein and free light chain testing) were negative. Unfortunately, further investigation to determine the presence of an underlying disease could not take place. In patient B, PG seems to possibly be associated with ulcerative colitis. At the onset of PG, the patient had no symptoms of her colitis. However, discontinuation of mesalazine may have contributed to the development of PG.^{8,9}

PG is characterised by a pustule that rapidly develops into an ulcer with raised, blue-purple-coloured wound edges, surrounded by erythema. The skin and subcutis may become necrotic, which is accompanied by the production of haemorrhagic and cream-coloured wound leakage. In addition to local symptoms, the patient may present with fever, general malaise

Box 2 Diagnostic Delphi criteria for pyoderma gangrenosum

Major criterion: required

- ▶ Biopsy of ulcer edge shows neutrophil infiltrates.

Minor criteria: minimum four required

- ▶ Exclusion of infection.
- ▶ Pathergy.
- ▶ History of inflammatory bowel disease or inflammatory arthritis.
- ▶ Papule, pustule or vesicle develops into an ulcer within 4 days.
- ▶ Ulcers with undermined wound edges, peripheral erythema and pain.
- ▶ Multiple ulcerations with at least one ulcer on the lower leg.
- ▶ Atrophic scars after ulcer healing.
- ▶ After initiation of immunosuppressant, ulcer size decreased within 1 month.

and pain.⁴ PG is often located on the lower extremities, but can develop anywhere on the body.¹⁰

In 20%–25% of patients with PG, a pathergic reaction occurs.⁷ Sterile inflammation occurs due to (minimal) trauma to the skin, for example, after surgery or even a needle prick. In patient A, the THA procedure may have been the cause. Subsequent surgeries probably aggravated the clinical picture due to new pathergic reactions. In patient B, localised pustule formation at the elbow occurred after creating a new intravenous access site.

The Delphi criteria have been the most recently defined diagnostic framework with which PG can be determined, with a specificity of 90% and a sensitivity of 86% (box 2).¹¹ Just as many PG cases in clinical practice are identified with the Delphi criteria as with the Su criteria.¹² However, the Paracelsus score seems to recognise even more patients with PG (89% vs 74%).¹² Compared with the Su criteria and Paracelsus score, the Delphi criteria seem to be the most practical for clinical use.¹² The presence of a neutrophilic infiltrate in biopsy is a major criterion and also requires the exclusion of an infectious cause, where the other two diagnostic criteria, both have the major criterion that other possible differentials should be excluded before PG becomes more probable.¹² Nevertheless, other causes of ulcerations should also be considered and ruled out (box 1).¹⁴

Blood tests for PG are non-specific and may show an inflammation. Wound cultures are important to rule out infection by microorganisms. However, wound cultures can be positive as a coinfection can occur, since PG provides a beneficial environment for bacteria to grow. Despite the risk of a pathergic effect, a biopsy of the wound edge should be performed to either prove or rule out causes such as vasculitis or malignancy.⁷ Histopathological examination of a biopsy of PG shows neutrophil infiltration.¹¹ After diagnosis, screening of PG-associated diseases, such as inflammatory bowel diseases and haematological malignancies, should be performed and part of clinical workup. Clinical signs and symptoms should provide guidance on where to start this screening process and vary case to case, which is why a multidisciplinary approach could be beneficial.

The treatment of PG is non-surgical. Surgical debridement should be avoided in the management of PG because it may induce pathergy and therefore worsen the disease iatrogenically.¹ In case of mild disease, patients can be treated with a low-dose prednisone and/or topical immunosuppressive drugs. In

patients with severe disease, which is defined as multiple ulcers or a single ulcer of at least 3 cm, prednisone in a high dose is recommended (dose 0.5–1.0 mg/kg body weight).¹ Improvement usually occurs within 2–3 days.¹³ If not necessary, long-term use of corticosteroids is not recommended due to the potential risk of common side effects, such as osteoporosis, weight gain and adrenal insufficiency. A corticosteroid-sparing treatment with ciclosporin (dose 4 mg/kg body weight) or a biological agent, such as infliximab (dose 5 mg/kg body weight), can offer the solution.¹⁴ A multicentre randomised controlled trial (RCT) showed no significant difference in efficacy of ciclosporin versus corticosteroids in the treatment of PG. After 6 weeks of treatment, successful response was seen in 47% of the patients.¹⁵ The benefits of biological agents have mainly been described in small case studies.⁶ Regarding the application of biological agents in PG, only one RCT has been performed. The study demonstrated a beneficial clinical response to infliximab in 69% of the patients vs 21% in the placebo group.¹⁶ More clinical trials are needed to compare treatment options.

In case of patient B, several therapeutic options were explored before coming to the above-mentioned long-term therapy. This was due to the reoccurrence of PG. In addition to drug therapy, optimal wound care is important to promote recovery and form a barrier against infection.¹⁷

Since PG can be aggravated and triggered by (minimal) traumatic injury, it is recommended that surgical intervention be avoided until the disease is in remission. Patients with a history of PG seem to be more prone to redevelop PG when operated again. Xia *et al*¹⁸ found a per-patient risk of 15.1% for experiencing a recurrence of PG after surgery. More invasive procedures, such as open surgeries, and presence of chronic PG at the time of the procedure, were associated with the recurrence of PG.¹⁸ Factors, such as the extensiveness of the operation as well as previous reappearance(s), seem to be predictive for this reoccurrence. As a preventive measure, prednisone treatment can be started a few days before the procedure.⁴ It is important that systemic therapy is slowly tapered postoperatively, as abrupt discontinuation may lead to reoccurrence.¹⁰

Different cases have been described in literature in which PG develops after surgical procedures. Ebrad *et al*¹⁹ conducted a review and found three cases of PG that occurred after THA.¹⁹ Also, a case has been reported where PG was seen after knee arthroscopy.²⁰ Recently, Mizushima *et al*²¹ described a patient with myelodysplastic syndrome who received granulocyte colony stimulating factor to prevent postoperative infections.²¹ The patient developed PG a few days after the procedure. In all cases, a bacterial infection was suspected based on the skin lesions. Initial treatment was often insufficient with surgical debridement and antibiotics. It is important to report cases of this rare skin condition to raise awareness that PG should be included in the differential diagnosis of an infectious-looking skin disease. Moreover, it is essential that, besides dermatologists, other specialists include PG in the workup of an ulcer.²² Therefore, PG should receive more exposure in literature of different medical specialties (eg, surgery, orthopaedics, general practice).

The gold standard for purulent excretion within 3 weeks after THA is performing a DAIR procedure. Patient A met these conditions. Because the clinical picture deteriorated after the DAIR, a second operation was performed. The entire prosthesis was removed during this surgery. Regarding the policy pursued in patient A, the first DAIR was a logical and inevitable step. The wound leakage and increased infection rates made infection very likely. In contrast, the second operation and explanation of the

prosthesis could have been avoided if the diagnosis had been made earlier. A biopsy of the wound edge could have indicated PG. Also, patient B had been admitted to the hospital for several weeks, underwent multiple surgeries and cast immobilisation. These invasive measures could possibly have been avoided if the diagnosis was confirmed earlier.

These cases highlight the importance of considering PG in infectious-appearing skin diseases that do not respond to antibiotics. When this diagnosis is made in a timely manner, unnecessary surgical interventions can be prevented to avoid pathergic deterioration. This is in order to minimise the considerable impact PG can have on a patient's life (also see Patient's perspective).²

Patient's perspective

Patient B: a small skin defect that appeared on the side of my ankle grew into an abscess. However, the abscess refused to heal after incision by the general practitioner (GP). I was given two different antibiotics, but to no avail. The GP referred me to the general surgeon in the hospital. I have had appointments at the departments wound expertise centre, Rheumatology and Vascular Surgery of the hospital. Despite the many appointments, the cause for the infection could not be found. The vascular surgeon opened the abscess in the operating room. I was allowed to go home the following day and the wound was rinsed twice a day. I had hoped this would heal my foot. Sadly, this was not the case. When the wound was almost healed, it seemed to get infected again. The surgeon urgently got an MRI of my foot done and I was referred to the orthopaedic surgeon. The orthopaedic surgeon advised a plaster to give rest to the foot. I was sceptical about the approach, but of course agreed. Unfortunately, I was right and the plaster did not yield the desired result. A week later, I was lying once again on the operating table for incision and drainage of the infection. Cultures taken during the operation remained negative. I was given antibiotics intravenously for the treatment of an infection. I had lost confidence in my own body and it was frustrating that no treatment had relieved me of my complaints. I am grateful that the orthopaedic surgeon was triggered by the atypical course of events.

The skin defect on my foot has healed. Currently, I am still taking 3 mg prednisone daily and getting adalimumab injections. Reducing the prednisone and replacing it with cyclosporine has not been successful.

Learning points

- ▶ Consider pyoderma gangrenosum when observing a painful, rapidly evolving, undermined ulcer with a purple edge that is unresponsive to antibiotics, and where tissue cultures show no growth of microorganisms.
- ▶ Pyoderma gangrenosum is a neutrophilic dermatosis which should be treated non-surgically with local or systemic corticosteroids.
- ▶ Surgical debridement should be avoided to limit pathergy and worsening of the disease.
- ▶ Early diagnosis can prevent a long and invasive healing process, reduce potential long-term damage and reduce healthcare costs.

Contributors EB and JM did the literature search and wrote the manuscript. JN and AZ provided the patient data and helped with editing and writing. All authors critically revised the manuscript and approved the final version.

Funding The authors have not declared a specific grant for this research from any funding agency in the public, commercial or not-for-profit sectors.

Competing interests None declared.

Patient consent for publication Obtained.

Provenance and peer review Not commissioned; externally peer reviewed.

Case reports provide a valuable learning resource for the scientific community and can indicate areas of interest for future research. They should not be used in isolation to guide treatment choices or public health policy.

REFERENCES

- 1 Mavarakis E, Marzano AV, Le ST, *et al.* Pyoderma gangrenosum. *Nat Rev Dis Primers* 2020;6:81-020-0213-x.
- 2 McPhie ML, Fletcher J, Machado MO, *et al.* A systematic review of depression and anxiety in adults with pyoderma gangrenosum. *Adv Skin Wound Care* 2021;34:432-6.
- 3 Anaya DA, Dellinger EP. Necrotizing soft-tissue infection: diagnosis and management. *Clin Infect Dis* 2007;44:705-10.
- 4 Ruocco E, Sangiuliano S, Gravina AG, *et al.* Pyoderma gangrenosum: an updated review. *J Eur Acad Dermatol Venereol* 2009;23:1008-17.
- 5 Brunsting LA, Goekerman WH, O'leary PA. Pyoderma (echthyma) gangrenosum: clinical and experimental observations in five cases in adults. *Arch Derm Syphilol* 1930;22:655-80.
- 6 Alavi A, French LE, Davis MD, *et al.* Pyoderma gangrenosum: an update on pathophysiology, diagnosis and treatment. *Am J Clin Dermatol* 2017;18:355-72.
- 7 Ashchyan HJ, Nelson CA, Stephen S, *et al.* Neutrophilic dermatoses: pyoderma gangrenosum and other bowel- and arthritis-associated neutrophilic dermatoses. *J Am Acad Dermatol* 2018;79:1009-22.
- 8 Karagozian R, Burakoff R. The role of mesalamine in the treatment of ulcerative colitis. *The Clin Risk Manag* 2007;3:893-903.
- 9 Lee JI, Park HJ, Lee JY, *et al.* A case of pyoderma gangrenosum with ulcerative colitis treated with mesalazine. *Ann Dermatol* 2010;22:422-5.
- 10 Ahronowitz I, Harp J, Shinkai K. Etiology and management of pyoderma gangrenosum: a comprehensive review. *Am J Clin Dermatol* 2012;13:191-211.
- 11 Mavarakis E, Ma C, Shinkai K, *et al.* Diagnostic criteria of ulcerative pyoderma gangrenosum: a Delphi consensus of international experts. *JAMA Dermatol* 2018;154:461-6.
- 12 Haag C, Hansen T, Hajar T, *et al.* Comparison of three diagnostic frameworks for pyoderma gangrenosum. *J Invest Dermatol* 2021;141:59-63.
- 13 Miller J, Yentzer BA, Clark A, *et al.* Pyoderma gangrenosum: a review and update on new therapies. *J Am Acad Dermatol* 2010;62:646-54.
- 14 Brooklyn T, Dunnill G, Probert C. Diagnosis and treatment of pyoderma gangrenosum. *BMJ* 2006;333:181-4.
- 15 Ormerod AD, Thomas KS, Craig FE, *et al.* Comparison of the two most commonly used treatments for pyoderma gangrenosum: results of the stop gap randomised controlled trial. *BMJ* 2015;350:h2958.
- 16 Brooklyn TN, Dunnill MGS, Shetty A, *et al.* Infliximab for the treatment of pyoderma gangrenosum: a randomised, double blind, placebo controlled trial. *Gut* 2006;55:505-9.
- 17 Fonder MA, Lazarus GS, Cowan DA, *et al.* Treating the chronic wound: a practical approach to the care of nonhealing wounds and wound care dressings. *J Am Acad Dermatol* 2008;58:185-206.
- 18 Xia FD, Liu K, Lockwood S, *et al.* Risk of developing pyoderma gangrenosum after procedures in patients with a known history of pyoderma gangrenosum-A retrospective analysis. *J Am Acad Dermatol* 2018;78:310-4.
- 19 Ebrad S, Severyns M, Benzakour A, *et al.* Pyoderma gangrenosum after orthopaedic or traumatologic surgery: a systematic review of the literature. *Int Orthop* 2018;42:239-45.
- 20 Bates T, Sheehan AJ, Kao E, *et al.* Fulminant pyoderma gangrenosum after outpatient knee arthroscopy. *J Am Acad Orthop Surg Glob Res Rev* 2021;5:e21.00006.
- 21 Mizushima M, Miyoshi H, Yonemori K. Pyoderma gangrenosum after total hip arthroplasty associated with administration of granulocyte colony-stimulating factor: a case report. *JBJS Case Connect* 2021;11:JBJS.CC.20.00924.
- 22 Reese AM, Haag CK, Jung E, *et al.* Pyoderma gangrenosum underrepresentation in non-dermatological literature. *Diagnosis* 2021;8:85-90.

Copyright 2022 BMJ Publishing Group. All rights reserved. For permission to reuse any of this content visit <https://www.bmj.com/company/products-services/rights-and-licensing/permissions/>
BMJ Case Report Fellows may re-use this article for personal use and teaching without any further permission.

Become a Fellow of BMJ Case Reports today and you can:

- ▶ Submit as many cases as you like
- ▶ Enjoy fast sympathetic peer review and rapid publication of accepted articles
- ▶ Access all the published articles
- ▶ Re-use any of the published material for personal use and teaching without further permission

Customer Service

If you have any further queries about your subscription, please contact our customer services team on +44 (0) 207111 1105 or via email at support@bmj.com.

Visit casereports.bmj.com for more articles like this and to become a Fellow