

Arthroscopic Transosseous Repair for both Proximal and Distal Components of Peripheral Triangular Fibrocartilage Complex Tear

Abstract

Background: Tears of the triangular fibrocartilage complex (TFCC) can result in instability of the distal radioulnar joint (DRUJ) and ulnar-sided wrist pain. This study evaluates clinical results of arthroscopic transosseous repair for both proximal and distal components of TFCC tear with DRUJ instability. **Materials and Methods:** Ten patients who underwent both proximal component and distal component of TFCC repair were retrospectively reviewed. The proximal component of TFCC was repaired through arthroscopic one-tunnel transosseous suture technique, and the combined distal component tear was repaired to the ulnar capsule using same transosseous tunnel in all cases. Visual analog scale (VAS) score for pain, wrist range of motion, grip strength, and postoperative complications were evaluated after a mean followup period of 23.5 months, and each patient was rated according to modified Mayo wrist score and quick disabilities of the arm, shoulder, and hand (DASH) questionnaire. **Results:** On arthroscopic findings, the hook test confirmed the proximal component of the TFCC tear and visible capsular detachment from TFCC confirmed combined distal component tear in all patients. At final followup, 7 patients had normal stability of DRUJ and 3 patients showed mild laxity compared with the contralateral side. The mean VAS for pain perception decreased from 4.1 to 0.7, and grip strength was increased significantly. The modified Mayo wrist score and Quick DASH score showed significant functional improvement. No surgery-related complications occurred. **Conclusions:** Arthroscopic one-tunnel transosseous TFCC foveal repair and simultaneous transosseous capsular repair of distal component can be a safe and effective strategy for repair of complete TFCC tear combined with DRUJ instability.

Keywords: Arthroscopy, transosseous suture, triangular fibrocartilage complex, distal radioulnar joint

MeSH terms: Wrist, cartilage, arthroscopy, ligaments

**Ji Hun Park,
Jong Woong Park**

Department of Orthopaedic
Surgery, Korea University Anam
Hospital, Seoul, Korea

Introduction

The triangular fibrocartilage complex (TFCC) is a three-dimensional structure that stretches between the radius, ulna, and the carpus. Biomechanical studies elucidated that this structure plays important role of absorbing axial load at the wrist and stabilizing distal radioulnar joint (DRUJ) during forearm rotation.^{1,2} Tears of the TFCC can, therefore, result in instability of the DRUJ and ulnar-sided wrist pain.

Palmer classified TFCC injuries based on the location and chronicity of the tear.³ Atzei proposed a treatment-oriented classification system focused on the Palmer 1B type peripheral tear, which subdivides into a distal component of TFCC (dc-TFCC; Atzei Class 1), a proximal component of TFCC (pc-TFCC; Atzei Class 3), and a combined complete tear pattern (Atzei Class 2).⁴ According to the reparability of each lesion, various treatment options are suggested.

Even though ideal procedure for TFCC tear remains controversial, most authors agree that restoring foveal insertion, which is considered as pc-TFCC, is the most important element for managing DRUJ instability. To date, various arthroscopic TFCC foveal repair techniques have been introduced, including direct foveal portal, all-inside, and transosseous techniques that use two suture passing tunnels.⁵⁻⁸ All of these techniques described the feasibility of anchoring the foveal attachment site of the torn TFCC to the original insertion. However, few studies have reported the clinical results for these techniques.

The distal component of the TFCC has a lesser role in DRUJ stability, but it is known to have the function of supporting and suspending the ulnar carpus.^{2,4} Several reports of isolated dc-TFCC repair have proved the benefits of restoring tautness of the TFCC for relieving symptoms.⁹ In a combined complete tear pattern, however,

Address for correspondence:

Prof. Jong Woong Park,
Department of Orthopaedic
Surgery, Korea University
Anam Hospital, 73, Incheon-Ro,
Sungbuk-Gu, Seoul 06334,
Korea.
E-mail: ospark@korea.ac.kr

Access this article online

Website: www.ijoonline.com

DOI:
10.4103/ortho.IJOrtho_598_16

Quick Response Code:



How to cite this article: Park JH, Park JW. Arthroscopic transosseous repair for both proximal and distal components of peripheral triangular fibrocartilage complex tear. Indian J Orthop 2018;52:596-601.

This is an open access journal, and articles are distributed under the terms of the Creative Commons Attribution-NonCommercial-ShareAlike 4.0 License, which allows others to remix, tweak, and build upon the work non-commercially, as long as appropriate credit is given and the new creations are licensed under the identical terms.

For reprints contact: reprints@medknow.com

the status of dc-TFCC after foveal fixation was not clearly verified.

We have been using arthroscopic one-tunnel transosseous repair for complete TFCC tears (Atzei Class 2). When a dc-TFCC is definitely torn or unhealed after detach from the capsule and is combined with a pc-TFCC tear, the pc-TFCC tear is repaired first through the transosseous tunnel, and then the dc-TFCC tear is repaired to the ulnocarpal capsule using the same transosseous tunnel. This study describes the arthroscopic technique for both pc-TFCC and dc-TFCC repair using one-tunnel transosseous suture in detail, as well as the clinical outcomes.

Materials and Methods

10 patients who underwent arthroscopic transosseous both components (pc-and dc-TFCC) repair for complete TFCC tear with DRUJ instability operated between 2013 and 2015 were included in this study. Approval of the institutional review board (AN16119-001) was obtained for review of medical records and clinical followup. All patients underwent routine wrist radiographic series, and initial diagnosis was made based on foveal sign¹⁰ (focal tenderness on the TFCC foveal insertion site), DRUJ instability test, and a magnetic resonance arthrography (MRA). Tear of each TFCC component was categorized according to the classification proposed by Atzei *et al.*⁴ [Table 1]. The definite diagnosis of Atzei class 2 complete TFCC tear was confirmed through arthroscopic examination before the TFCC repair. On the arthroscopic examination, pc-TFCC tear was confirmed with a positive hook test. When torn dc-TFCC was definitely detached and unhealed from its capsular insertion, it was indicated for both components suture repair [Figure 1].

The ballottement test was used to assess DRUJ stability.⁷ The examiner firmly grasped the radius and radial carpal bones

with one hand and evaluated the anteroposterior translation of the ulnar head on the sigmoid notch of the radius in the neutral, supination, and pronated forearm positions. An increased passive anteroposterior or posteroanterior laxity and evoked symptom without a firm end-point was considered as a positive instability. Depending on the instability in various forearm positions, the test results were classified into one of the four grades compared with those from the normal opposite side. Grade 0 was defined as normal stability (same as the contralateral side), Grade 1 as increased laxity with firm end-point in all forearm position, Grade 2 as increased translation with firm end-point at least one forearm position, and Grade 3 as increased translation without firm end-point in all forearm position. Our indication of TFCC repair surgery was primarily subjected in patients with Grade 2 or Grade 3. Patients who underwent single component repair of TFCC were excluded from the study. No one had previous

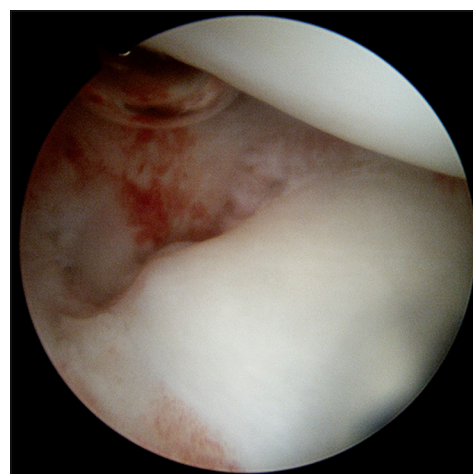


Figure 1: Arthroscopic view showing detached distal component of triangular fibrocartilage complex (dc-triangular fibrocartilage complex) from its capsular insertion

Table 1: Atzei-European Wrist Arthroscopy Society treatment-oriented classification of triangular fibrocartilage complex peripheral tears

Clinical and arthroscopic findings	Class 1 Repairable distal tear	Class 2 Repairable complete tear	Class 3 Repairable proximal tear	Class 4 Nonrepairable tear	Class 5 Arthritis DRUJ
Clinical DRUJ instability	None/slight	Mild/severe	Mild/severe	Severe	Mild/severe
Status of TFCC distal component	Torn	Torn	Intact	Torn	Variable
Status of TFCC proximal component	Intact	Torn	Torn	Torn	-
Healing potential of TFCC tear	Good	Good	Good	Poor	-
Status of DRUJ cartilage	Good	Good	Good	Good	Poor
Treatment	Repair: Suture (ligament-to-capsule)	Repair: Foveal refixation		Reconstruction: Tendon graft	Salvage: Arthroplasty or joint replacement

DRUJ=Distal radioulnar joint, TFCC=Triangular fibrocartilage complex

operative history on the same wrist, traumatic event at the contralateral wrist, and any systemic diseases that can cause hand and wrist problems, such as rheumatoid arthritis.

There were six males and four females with a mean age of 33.4 years (range 19-50 years). The average followup period was 23.5 months (range 12-42 months) after surgery. All patients had a history of trauma to the wrist before symptom onset. All patients manifested a foveal sign with various degrees of DRUJ instability; 3 patients were Grade 2, and 7 patients were Grade 3. The mean period from injury to operation was 8.5 months (range 2-48 months). The mechanism of injury was falling with wrist hyperextension in 6 patients and forced forearm twisting in 4 patients. Preoperative MRA revealed complete tear including both pc-and dc-TFCC tears (Atzei class 2) in all patients. Arthroscopic one-tunnel transosseous repair of both pc-TFCC and dc-TFCC were performed by one senior surgeon in all of the patients, using the same surgical technique.

The clinical outcome assessment at the final followup included the 10-point visual analog scale (VAS) score for pain, wrist range of motion (ROM), grip strength, modified Mayo wrist score, Quick disabilities of the arm, shoulder, and hand score (DASH) questionnaire, DRUJ instability based on graded ballottement test, and postoperative complications. For grip strength, the parameters expressed as percentages were compared with those of the contralateral normal side of the wrist. All preoperative evaluation and postoperative outcome assessment including instability test were performed by one surgeon.

Operative procedure

The patient was placed in the supine position, and general orthopedic preparation for wrist arthroscopic surgery was performed, including pneumatic tourniquet and traction of the wrist under appropriate traction power (10-15 lb.). Before wrist traction for the arthroscopic procedure, we rechecked DRUJ instability under general anesthesia. The standard 3-4 and 6R portals were utilized for diagnostic arthroscopy with a 2.4-mm small joint arthroscope. Evaluation for possible combined tear of the carpal ligament was performed, followed by identification of pathologic findings of the TFCC. Palmer 1B TFCC tear was identified through arthroscopic viewing and the hook test, with a probe inserted in the prestyloid recess. Foveal tear of the TFCC (pc-TFCC tear) was revealed as loss of tension and displacement both radially and distally. Combined tear of dc-TFCC was revealed as detachment of distal component with joint capsule.

A longitudinal skin incision was made on the direct lateral aspect of the ulna from the tip of the ulnar styloid process to the proximal region 2 cm between the extensor carpi ulnaris (ECU) and flexor carpi ulnaris (FCU). To make a transosseous tunnel, a specially designed targeting

device (C-Ring Aiming Guide, Arthrex, Naples, FL, USA) was placed through the 6R portal with the sharp pointed tip over the fovea ulnaris. The acceptable trajectory point was on the proximal region 1.5 cm proximal to the tip of the ulnar styloid process. A 1.1-mm K-wire was introduced through the targeting guide to the center of the footprint of the torn pc-fibre of the TFCC. First, a 2.7-mm-diameter cannulated drill was used to make a transosseous tunnel, which was enlarged with a 4-mm diameter cannulated drill. Under arthroscopic control, a 2-0 fiber wire suture (FiberWire, Arthrex, Naples, FL, USA) was passed into the joint with the aid of an 18-gauge needle through the osseous tunnel and TFCC. The 18-gauge needle was removed, and half of the length of the suture material was pulled out through the 6R portal using a grasper. We inserted the other 18-gauge needle with a lasso loop to pull out the suture through the osseous tunnel. The puncture point of the TFCC by the wired lasso loop was kept apart at least 4 mm from the first suture. The fiber wire suture was passed through the lasso loop in the joint with the aid of a suture retriever or fine-tipped mosquito clamp. Then, the lasso loop was pulled back through the transosseous tunnel. The two ends of the sutures were stabilized with a suture anchor (2.5-mm Push-Lock, Arthrex, Naples, FL, USA) proximal to the trajectory of the bone tunnel, approximately 5-10 mm apart [Figure 2a].

After completion of foveal fixation, another 18-gauge guide needle with 2-0 fiber wire was inserted through the osseous tunnel targeted to the periphery of the TFCC [Figure 2a and b]. After retrieval of the end of the suture through the 6R portal, the other 18-gauge needle with a lasso loop was passed through the osseous tunnel to pull out the suture and entered the joint through the ulnocarpal capsule from an outside-in direction [Figure 2c and d]. With the suture end, the lasso loop was pulled back through the transosseous tunnel to secure the peripheral end of the TFCC to the capsule [Figure 2e]. The two ends of the sutures were also stabilized with a suture anchor proximal to the first anchor that was inserted for pc-TFCC repair, approximately 5-10-mm apart [Figure 2f and g].

Postoperative care and rehabilitation

A bulky compressive dressing and an above the elbow long-arm cast were applied in 30° forearm supination. At 2 postoperative weeks, skin sutures were removed and a well-molded long-arm cast was kept for an additional 4 weeks. After removal of the cast at 6 weeks after surgery, active ROM exercise was started, and the wrist was protected with a removable wrist brace for an additional 2 weeks when the ROM exercise was temporarily suspended or during the night. The target of physiotherapy was to achieve full pronation supination range of wrist motion at 8-9 weeks after the operation. Isometric strengthening exercise was initiated about 3 months after

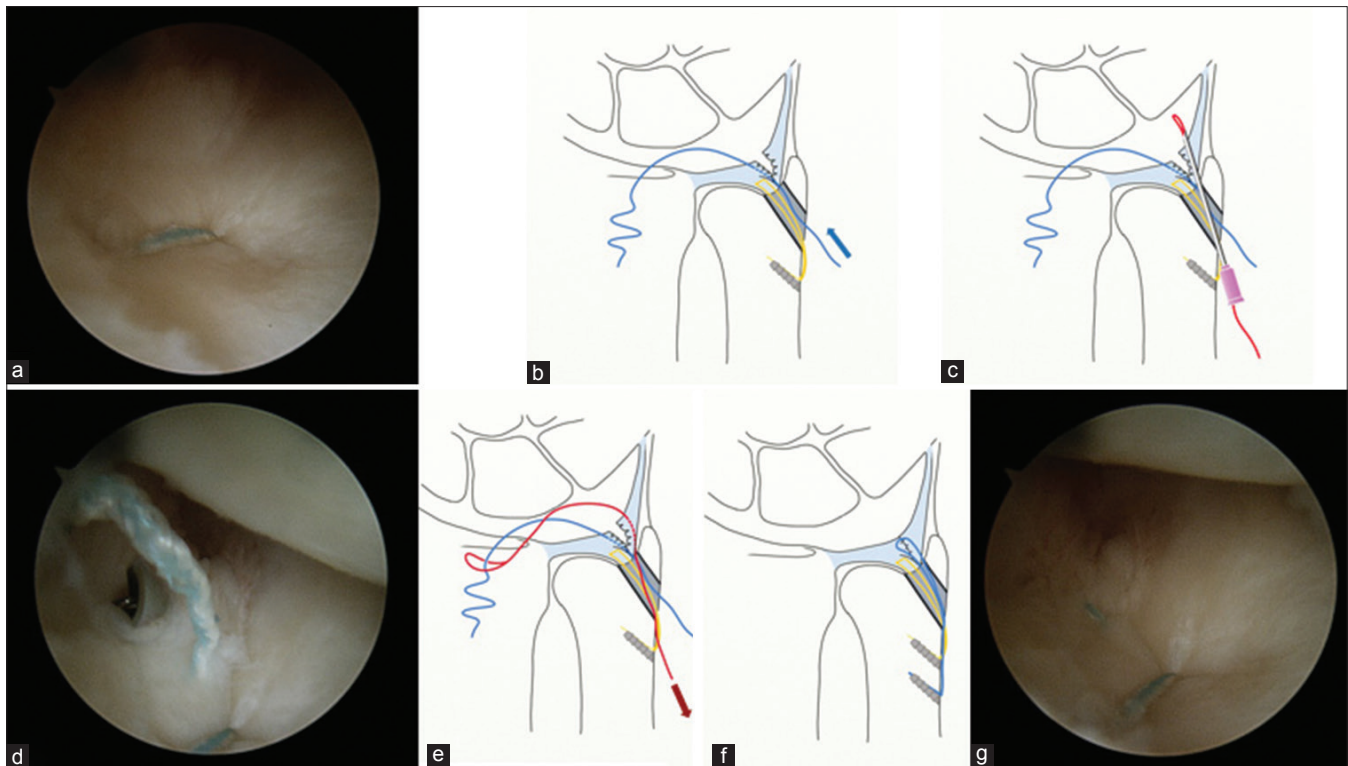


Figure 2: The operative procedure of proximal and distal component of triangular fibrocartilage complex (pc- and dc-triangular fibrocartilage complex) repair. (a) Arthroscopic view showing completion of repair for the torn proximal component of triangular fibrocartilage complex (pc-triangular fibrocartilage complex). (b) Line diagram showing first, pc-triangular fibrocartilage complex is repaired with transosseous suture (yellow). A fibre wire suture (blue) is pulled out through 6R portal passing the peripheral portion of dc-triangular fibrocartilage complex. (c) Line diagram showing Nitinol loop wire (red) passed through the ulnocarpal capsule using guide needle. (d) Arthroscopic view of passed guide needle and loop wire. (e) Line diagram showing Pull-out fibre wire (blue) with wire loop (red) through bone tunnel. (f) Line diagram showing the suture is completed with an anchor. (g) Final arthroscopic view after completion of dc- and pc-triangular fibrocartilage complex repair using a single transosseous tunnel

the surgery. The patient was permitted to resume contact or heavy-lifting sports activities 6 months after the surgery.

Statistical analysis

For the evaluation of statistical significance, a Wilcoxon signed-rank test was used to compare preoperative and postoperative results. Statistical analyses were performed using IBM SPSS Statistics, version 20 software (IBM Corporation, USA). The meaningful statistical significance was set as $P < 0.05$.

Results

Arthroscopic examination revealed Atzei Class 2 complete TFCC tear in all cases. Preoperatively, unstable DRUJ was stabilized intraoperatively after foveal repair. At the final followup, DRUJ instability test showed improved stability in all patients; Grade 0 in 7 patients and Grade 1 in 3 patients.

The mean arc of flexion extension, radioulnar deviation, and pronation supination at the final followup were 147.0° (range 110° – 170°), 59.3 (range 50° – 70°), and 172.0 (range 160° – 180°), respectively. All arc of motion did not change significantly (flexion extension, $P = 0.091$; radioulnar deviation, $P = 0.395$; pronation supination, $P = 0.197$). The grip strength was recovered from average 67.5% of

the contralateral side to an average of 79.3% ($P = 0.038$). Resting and movement-related pain perception decreased from 4.1 to 0.7 on the 10-point VAS ($P = 0.004$). Five patients were pain-free and 4 patients felt vague pain on the end range motion of forearm rotation (VAS 1–2). The mean modified Mayo wrist score was significantly improved after surgery from 60.5 to 84 ($P = 0.005$). The Quick DASH score was improved from 36.1 to 14.1 ($P = 0.005$). All patients returned to their work and did not complain restriction in their daily and social lives.

No surgery-related complications such as ulnar styloid fracture, infection, nerve injury, or recurrence of DRUJ instability occurred. The transosseous tunnel was invisible on the radiographs at an average 3 months after surgery.

Discussion

This study aimed to examine the clinical outcome of arthroscopic, one-tunnel, transosseous suture repair of complete TFCC tears. The technique we used had two distinctive procedures compared with previous arthroscopic repair techniques for a peripheral TFCC tear. One procedure used a single large transosseous tunnel to repair the torn pc-TFCC, and the other performed simultaneous repair of the distal component of the TFCC using the same

transosseous tunnel. At a mean 23.5 months of followup, patients showed significant and sustained pain relief and acceptable functional outcome. All patients demonstrated significant functional improvement as measured using the Quick DASH and Mayo wrist scores.

Recent anatomic and biomechanical studies have enabled advanced repair methods for foveal tears of the TFCC. The TFCC can be described as a distal component that acts like a hammock to surround and support the carpus, with the proximal component represented by a proximal triangular ligament anchoring the fovea ulnaris.^{2,4} The proximal component was revealed main stabilizer of DRUJ.¹¹ Various recently introduced techniques of arthroscopic foveal repair of the pc-TFCC reportedly had good clinical outcomes comparable to those of previous open techniques. Atzei *et al.*⁴ reported arthroscopy-assisted foveal repair with a suture anchor through the direct foveal portal. Nakamura *et al.*⁸ and Shinohara *et al.*¹² reported arthroscopy-assisted transosseous outside-in techniques with two separate osseous tunnels. Iwasaki and Minami⁵ introduced an arthroscopically assisted foveal repair using a single transosseous tunnel. They made one 2.9-mm transosseous tunnel under C-arm guidance, and two ends of the suture through the osseous tunnel were tied onto the ulnar periosteum around the proximal entrance of the osseous tunnel. Our technique is primarily based on the method of Iwasaki and Minami.⁵ We made one larger transosseous tunnel using a 4-mm cannulated drill using guidance from a specific targeting device.

According to our experience, this had several technical advantages. First, making a secure suture with an adequate width is much easier through the larger osseous tunnel rather than a narrow one. Second, a larger tunnel allows making a secondary suture if the security of the first suture is questionable. Furthermore, the peripheral end of the osseous tunnel can be positioned outside of the ulnocarpal joint capsule, and the guiding needle can be aimed toward the capsule with outside-in direction, which enables securing of the torn dc-TFCC to its insertion site on the capsule.

Making one large transosseous tunnel also provides improved healing potential, especially if the patient has a chronic TFCC tear. The previous studies showed that creation of an osseous tunnel can enhance fresh bleeding from the cancellous bone and provide increased healing potential to the avulsed, retracted, and scarred fiber end of the TFCC.⁵ According to the clinical results of Nakamura *et al.*,⁸ open repair with thorough refreshing of the bone insertion site showed excellent clinical results in acute, subacute, and chronic cases longer than 7 months after injury. We believe that a larger transosseous tunnel has a much greater chance of providing a fresh healing bed compared to simple curettage of the TFCC footprint.

For isometricity, the torn vertical fibers of the TFCC should be attached at the center of the fovea. The ideal direction

of the structures is parallel to the direction of the fibres.¹¹ In our technique, we started the transosseous tunnel just proximal to the ulnar styloid base, where the point of the ulnar ward curvature of the ulnar styloid process converts to the flat ulnar shaft. This point is approximately 1.5 cm proximal to the tip of the ulnar styloid process. Aiming the cannulated drill guide wire under the control of a TFCC targeting guide helps establish a more accurate position of the osseous tunnel than under C-arm guidance or manual guide insertion under arthroscopic control.

Problems in establishing the transosseous tunnel should be addressed. Because the width of the ulnar end is relatively small, we were concerned about iatrogenic ulnar styloid fracture by creating a large tunnel. To avoid this situation, we made the tunnel in two steps, starting with a smaller 2.7-mm cannulated drill. This first osseous tunnel was enlarged using a 4-mm cannulated drill. This stepwise drilling could decrease acute stress on the ulnar end. In our series, there was no intraoperative or postoperative ulnar fracture as of the latest followup.

For the torn dc-TFCC, several arthroscopic techniques have been advocated to repair it to the ulnocarpal joint capsule and ECU tendon subsheath.^{9,13} Accumulated evidence indicates that suturing only the dc-TFCC to the surrounding soft tissue or capsule without healing of the proximal portion of the TFCC to its anatomical insertion site is not enough to attain sufficient DRUJ stability.^{11,14} With a stable DRUJ, however, repairing the dc-TFCC still results in a good clinical outcome, especially from the aspect of pain relief.^{9,15} We anticipated that repairing the dc-TFCC would have a synergistic effect on the outcome in a complete tear pattern, especially after achieving stability of the DRUJ by foveal repair.

In earlier reports, the status of the dc-TFCC after foveal repair was not verified. In our experience, some patients revealed fibrotic healing of the dc-TFCC on arthroscopy, even though they showed a complete tear on preoperative MRA taken several months before the operation. In some cases, however, the dc-TFCC still showed a visible gap without evidence of spontaneous healing from the detached capsule. Our study was restricted to the latter cases. We believe that individual suturing of the dc-TFCC portion helps restore tension to the TFCC, possibly enabling more anatomical healing of a distal component that had not spontaneously healed.

A permanent suture has been preferred for TFCC repair rather than a biodegradable suture, because of its strength and the long lasting durability required for the healing time of the TFCC. Thus, remaining suture knot irritation has been a frequent complication with previous techniques. We used nonabsorbable sutures but made them knotless with a specific suture stabilizing device (2.5-mm PushLock, Arthrex, Naples, FL, USA) to provide sufficient construct for the repair.¹⁶ In this study, there were no complaints of suture knot irritation or recurrent DRUJ instability as of the latest followup.

A limitation of this study is that we could not delineate the exact contribution of dc-TFCC repair to improved clinical outcomes. Because all patients had DRUJ instability, they already expected improved functional outcomes from repair of the pc-TFCC. However, accumulated data already showed the beneficial effects of dc-TFCC repair in Atzei class 1 tears. Furthermore, our technique for additional repair of the unhealed dc-TFCC accompanied with pc-TFCC repair in this study was easily possible through a single transosseous tunnel and did not show any additional complication. Future study comparing both components repair and only foveal repair in complete TFCC tears could fully evaluate advantages of this procedure.

Conclusions

Arthroscopic, one-tunnel, and transosseous suture repair can provide reliable pain relief and reestablishment of DRUJ stability for complete TFCC tear. Simultaneous repair of combined distal component could be simply fulfilled using the transosseous tunnel created for foveal repair with favorable outcomes.

Declaration of patient consent

“The authors certify that they have obtained all appropriate patient consent forms. In the form the patient(s) has/have given his/her/their consent for his/her/their images and other clinical information to be reported in the journal. The patients understand that their names and initials will not be published and due efforts will be made to conceal their identity, but anonymity cannot be guaranteed.”

Financial support and sponsorship

Nil.

Conflicts of interest

There are no conflicts of interest.

References

- Palmer AK, Werner FW. The triangular fibrocartilage complex of the wrist – Anatomy and function. *J Hand Surg Am* 1981;6:153-62.
- Nakamura T, Yabe Y, Horiuchi Y. Functional anatomy of the triangular fibrocartilage complex. *J Hand Surg Br* 1996;21:581-6.
- Palmer AK. Triangular fibrocartilage disorders: Injury patterns and treatment. *Arthroscopy* 1990;6:125-32.
- Atzei A, Rizzo A, Luchetti R, Fairplay T. Arthroscopic foveal repair of triangular fibrocartilage complex peripheral lesion with distal radioulnar joint instability. *Tech Hand Up Extrem Surg* 2008;12:226-35.
- Iwasaki N, Minami A. Arthroscopically assisted reattachment of avulsed triangular fibrocartilage complex to the fovea of the ulnar head. *J Hand Surg Am* 2009;34:1323-6.
- Desai MJ, Hutton WC, Jarrett CD. Arthroscopic repair of triangular fibrocartilage tears: A biomechanical comparison of a knotless suture anchor and the traditional outside-in repairs. *J Hand Surg Am* 2013;38:2193-7.
- Atzei A. New trends in arthroscopic management of type 1-B TFCC injuries with DRUJ instability. *J Hand Surg Eur Vol* 2009;34:582-91.
- Nakamura T, Sato K, Okazaki M, Toyama Y, Ikegami H. Repair of foveal detachment of the triangular fibrocartilage complex: Open and arthroscopic transosseous techniques. *Hand Clin* 2011;27:281-90.
- Wysocki RW, Richard MJ, Crowe MM, Leversedge FJ, Ruch DS. Arthroscopic treatment of peripheral triangular fibrocartilage complex tears with the deep fibers intact. *J Hand Surg Am* 2012;37:509-16.
- Tay SC, Tomita K, Berger RA. The “ulnar fovea sign” for defining ulnar wrist pain: An analysis of sensitivity and specificity. *J Hand Surg Am* 2007;32:438-44.
- Nakamura T, Makita A. The proximal ligamentous component of the triangular fibrocartilage complex. *J Hand Surg Br* 2000;25:479-86.
- Shinohara T, Tatebe M, Okui N, Yamamoto M, Kurimoto S, Hirata H, *et al.* Arthroscopically assisted repair of triangular fibrocartilage complex foveal tears. *J Hand Surg Am* 2013;38:271-7.
- Ruch DS, Anderson SR, Ritter MR. Biomechanical comparison of transosseous and capsular repair of peripheral triangular fibrocartilage tears. *Arthroscopy* 2003;19:391-6.
- Bain GI, McGuire D, Lee YC, Eng K, Zumstein M. Anatomic foveal reconstruction of the triangular fibrocartilage complex with a tendon graft. *Tech Hand Up Extrem Surg* 2014;18:92-7.
- Reiter A, Wolf MB, Schmid U, Frigge A, Dreyhaupt J, Hahn P, *et al.* Arthroscopic repair of palmer 1B triangular fibrocartilage complex tears. *Arthroscopy* 2008;24:1244-50.
- Geissler WB. Arthroscopic knotless peripheral triangular fibrocartilage repair. *J Hand Surg Am* 2012;37:350-5.