



# Omental Incarceration over Twenty Years Presenting as a Hyperechoic Endometrial Mass in a Postmenopausal Woman

Gina Nam<sup>1</sup>, Sa Ra Lee<sup>2</sup>, Yu Ra Ko<sup>2</sup>, Gwang Jun Kim<sup>1</sup><sup>1</sup>Department of Obstetrics and Gynecology, Chung-Ang University Hospital, Chung-Ang University College of Medicine, Seoul, Korea,<sup>2</sup>Department of Obstetrics and Gynecology, Asan Medical Center, University of Ulsan College of Medicine, Seoul, Korea

Uterine perforation related with dilatation and curettage (D&C) is an uncommon event. Combined complications such as hemorrhage, adjacent organ injury, and omental incarceration may require an emergent surgical treatment. These are usually evident immediately or several days after the D&C, and a delayed presentation of uterine perforation are extremely rare. Herein, we report a rare case of omental incarceration presenting as a hyperechoic endometrial mass in a postmenopausal woman, diagnosed twenty-three years after the D&C. According to this case, when we encounter a hyperechoic endometrial lesion penetrating the uterine wall in women with a history of an intrauterine procedure such as D&C, we need to consider the possibility of an incarcerated omentum.

**Key Words:** Dilatation and curettage, Omentum, Ultrasonography, Uterine perforation

## INTRODUCTION

Dilatation and curettage (D&C) is one of the most commonly performed procedure in obstetrics and gynecology. Uterine perforation during D&C is not a common event and can be occurred in 1.9 per 1,000 women [1]. Nathanson [2] reported that incidence of uterine perforation was between 0.75 and 15 per 1,000 women. Some of the patients are asymptomatic and remained undiagnosed [1]. However, complications of uterine perforation such as hemorrhage [3], bladder or bowel injury, jejunum-uterine fistula [4], small bowel incarceration [5], appendix incarceration [6], and omental incarceration [6] have been reported and present with severe symptoms. These are usually evident immediately after or several days after the D&C and require an emergent surgical treatment. However, a delayed presentation of uterine perforation is extremely rare. Herein, we report a rare case of omental incar-

ceration diagnosed twenty-three years after the D&C. In addition to that, to the best of our knowledge, cases of omental incarceration after D&C have been reported only in premenopausal women with accompanying symptoms of abdominal pain, vaginal bleeding or discharge.

Herein, we present a rare case of asymptomatic omental incarceration in uterus in a postmenopausal woman who presented as a hyperechoic endometrial mass and diagnosed by ultrasonography with office hysteroscopy and confirmed by pelviscopy.

## CASE REPORT

This study was conducted according to the guidelines of the Declaration of Helsinki (2013) and was approved by the Asan Medical Center Institutional Review Board (approval No. 2020-0731).

We report a rare case of omental incarceration pre-

Received: January 6, 2021 Revised: February 15, 2021 Accepted: March 1, 2021

Address for Correspondence: Sa Ra Lee, Department of Obstetrics and Gynecology, Asan Medical Center, University of Ulsan College of Medicine, 88 Olympic-ro 43-gil, Songpa-gu, Seoul 05505, Korea

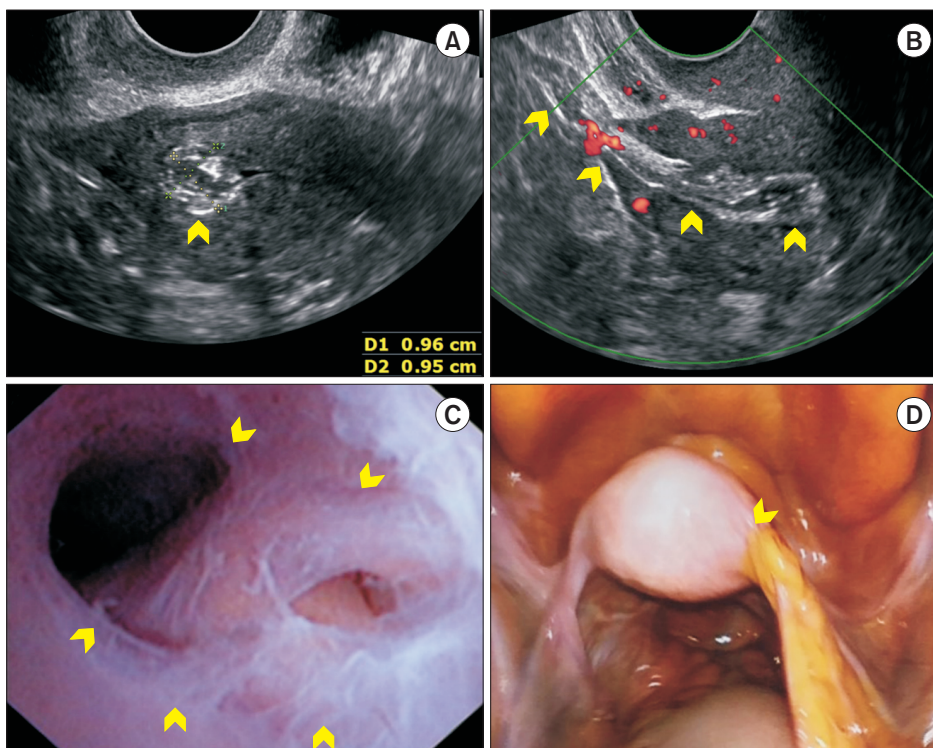
Tel: 82-2-3010-3648, E-mail: leesr@amc.seoul.kr, ORCID: <https://orcid.org/0000-0002-7890-8348>

sented as a hyperechoic endometrial mass in a postmenopausal woman. A 57-year-old postmenopausal woman (gravida 2, para 2) was transferred for an abnormal endometrial mass on pelvic ultrasonography during a checkup a month ago. She did not have abnormal vaginal discharge, vaginal bleeding or abdominal pain. She had a history of D&C 23 years ago for abnormal uterine bleeding and had no other surgical history. The patient reported that vaginal bleeding and abdominal discomfort had continued for several weeks after D&C. She didn't have regular checkups and has only been tested for Pap smear. Transvaginal sonography showed a hyperechoic round mass with thick band-like structure penetrating the uterine wall and blood vessels in it on color Doppler exam (Fig. 1A and 1B). Office hysteroscopy revealed a pale-yellowish mass with intrauterine adhesions (Fig. 1C). Laparoscopy showed an incarcerated omentum into uterine cavity through the uterine perforation site on fundus (Fig. 1D). Laparoscopic and hysteroscopic resection of the incarcerated omentum was performed. The uterine wall defect was sutured with 2-0 Vicryl (Ethicon, Somerville, NJ, USA) intracorporeally. The hospital course was not eventful.

## DISCUSSION

Uterine perforation after D&C is usually diagnosed immediately after or several days after the D&C and a delayed presentation is extremely rare. There is a case of uterine perforation diagnosed at 28 days after the D&C and the patient complained lower abdominal pain and small amount of vaginal bleeding [7]. However, some cases of uterine perforation can be asymptomatic for the minimal accompanying bleeding or no injuries to adjacent organs. These cases can be remained undiagnosed for a long time [1]. Ozaki and Suzuki [8] reported a suspected case of omental incarceration in an woman who underwent D&C, 2 years ago. The patient had no symptom and was referred for an abnormal hyperechoic mass-like lesion in the anterior uterine wall which was noted in her pregnancy at 16 weeks' of gestation [8].

In terms of omental incarceration after D&C, symptomatic cases have been reported and presented with abdominal pain, vaginal bleeding or discharge [7-10]. All cases were reported in premenopausal women and this is the first report on omental incarceration in postmenopausal women with the longest duration of asymptomatic period. Most authors agree that if the endometrial thickness is less than 4-5 mm in menopause



**Fig. 1.** (A, B) Sonographic finding showing a hyperechoic band-like structure penetrating the uterine wall with blood flow on Doppler exam (arrows). (C) A pale-yellowish mass with filmy adhesions in uterine cavity was noted on office hysteroscopy (arrows). (D) Diagnostic laparoscopy revealed incarcerated omentum with blood vessel (arrow).

state, the risk of endometrial malignancy is extremely low [11]. If this endometrial mass sized about 9 mm (as in this case) was found in premenopausal women, it is likely that it was considered as endometrial polyp and followed-up without further evaluation or work-up. However, 9 mm endometrial mass can be regarded as a pathologic lesion in postmenopausal women, as this patient did, we apply more strictive standard about appropriate evaluation of endometrial mass in postmenopausal women. Therefore, we investigated that complete packing of the perforation site of the uterus with the omentum accompanied by the intact blood vessels supplying the incarcerated omentum, enabled this patient to live without symptom related with omental necrosis for so long time.

Sedrati et al. [9] reported the first case of omental incarceration diagnosed using a hysteroscopy. The fat like yellowish endometrial mass and yellow drops on hysteroscopy led to discover the omentum. As in the case, the omental incarceration accompanying uterine perforation can be diagnosed by conventional hysteroscopy [9] but usually the patient has to be under anesthesia. Koshiha et al. [7] mentioned that magnetic resonance imaging (MRI) is useful for detection of incarcerated omental tissue because of superior soft tissue contrast. However, MRI is expensive and less available in emergent situation. Our case demonstrated the usefulness of ultrasonography and an office hysteroscopy in diagnosing incarcerated omentum without anesthesia. Ultrasonography with office hysteroscopy can be cost-effective diagnostic option and easy to perform.

If uterine perforation is suspected in a patient with hemodynamically stable, the conservative treatment can be an option unless the patient has future pregnancy plan. However, if the patient is hemodynamically unstable, it may be a life threatening and may be associated with complications that need an emergent surgical intervention. The appropriate decision about the need of surgical treatment can prevent fatal consequences.

To the best of our knowledge, this is the first case of asymptomatic omental incarceration after D&C in a postmenopausal woman undiagnosed for the longest duration. It is warranted to consider the possibility of incarcerated omentum when we encounter hyperchoic endometrial lesion penetrating uterine wall in a woman with a history of intracavitary interventions

such as D&C. The importance of thorough history taking about prior procedures with a risk of uterine perforation should be emphasized. Pelvic ultrasonography combined with office hysteroscopy is useful primary diagnostic option for the suspected incarcerated omentum.

## CONFLICT OF INTEREST

No potential conflict of interest relevant to this article was reported.

## REFERENCES

1. Amarin ZO, Badria LF. A survey of uterine perforation following dilatation and curettage or evacuation of retained products of conception. *Arch Gynecol Obstet* 2005; 271: 203-6.
2. Nathanson BN. Management of uterine perforations suffered at elective abortion. *Am J Obstet Gynecol* 1972; 114: 1054-9.
3. Tong S, Jeffares J, Lopes R, Vollenhoven B. Delayed presentation of uterine perforation and haemorrhagic shock 10 days after surgical termination of pregnancy. *Aust N Z J Obstet Gynaecol* 2001; 41: 335-6.
4. Duttaroy DD, Madhok BM. Jejuno-uterine fistula. *Eur J Obstet Gynecol Reprod Biol* 2006; 129: 94-5.
5. Shulman SG, Bell CL, Hampf FE. Uterine perforation and small bowel incarceration: sonographic and surgical findings. *Emerg Radiol* 2006; 13: 43-5.
6. Dignac A, Novellas S, Fournol M, Caramella T, Bafghi A, Chevalier P. Incarceration of the appendix complicating a uterine perforation following surgical abortion: CT aspects. *Emerg Radiol* 2008; 15: 267-9.
7. Koshiha A, Koshiha H, Noguchi T, Iwasaku K, Kitawaki J. Uterine perforation with omentum incarceration after dilatation and evacuation/curettage: magnetic resonance imaging findings. *Arch Gynecol Obstet* 2012; 285: 887-90.
8. Ozaki K, Suzuki S. Uterine perforation with omentum incarceration after dilatation and evacuation/curettage. *Arch Gynecol Obstet* 2013; 287: 607-8.
9. Sedrati A, Drizi A, van Herendaal B, Djokovic D. Hysteroscopic diagnosis of omentum incarceration subsequent to an iatrogenic uterine perforation. *J Minim Invasive Gynecol* 2019; 26: 29-30.
10. Leibner EC. Delayed presentation of uterine perforation. *Ann Emerg Med* 1995; 26: 643-6.
11. Goldstein SR. Modern evaluation of the endometrium. *Obstet Gynecol* 2010; 116: 168-76.