



ELSEVIER

Contents lists available at [ScienceDirect](https://www.sciencedirect.com)

Respiratory Medicine Case Reports

journal homepage: www.elsevier.com/locate/rmcr

Case Report

Metastasis of the abdominal wall in a patient with diagnosis of pulmonary adenocarcinoma: An interesting finding

Juliana Mancera^a, Arturo Vergara^{b,c}, Manuel E. Cadena^{b,c},
Ivan David Lozada-Martinez^d, Daniela Guardo-Carmona^d,
Luis Felipe Cabrera-Vargas^{d,e}, A.H.M. Ataulloh^{f,*}

^a Department of Surgery, Pontificia Universidad Javeriana, Bogotá, Colombia

^b Department of Surgery, Fundacion Santa Fe de Bogotá, Colombia

^c Department of Surgery, School of Medicine, Universidad de los Andes, Bogotá, Colombia

^d Medical and Surgical Research Center, Future Surgeons Chapter, Colombian Surgical Association, Bogotá, Colombia

^e Department of Surgery, Universidad el Bosque, Bogotá, Colombia

^f Medical Officer, Department of Medicine, Sher-E-Bangla Medical College Hospital, Barishal, Bangladesh

ARTICLE INFO

Keywords:

Adenocarcinoma of lung
Neoplasm metastasis
Abdominal wall
Rare diseases

ABSTRACT

Tumors of the abdominal wall are rare, divided into benign and malignant lesions that are composed of primary tumors and by the parietal invasion of intra-abdominal tumors and metastatic parietal implants. In the case of metastases in the abdominal wall, the most frequent are metastases from neoplasms of colonic origin. The case described below is that of a 68-year-old patient with a history of stage IIA left lung adenocarcinoma who received partial response radiotherapy with an indication for chemotherapy, which she refused and lost follow-up.

1. Introduction

Tumors of the abdominal wall are rare; they are divided into benign lesions and malignant lesions which are composed of primary tumors and by the parietal invasion of intraabdominal tumors and metastatic parietal implants [1]. Metastasis of the abdominal wall has an incidence of approximately 0.7–9%, direct invasion and tumor implants in the abdominal wall can be due to tumors of various types and locations., the most common causes is secondary to neoplasms of colonic origin, gastric origin and implants of trocar holes, being metastasis of lung origin very rare [1–3]. Here, we describe a case of a metastasis of the abdominal wall in a patient with diagnosis of pulmonary adenocarcinoma.

2. Case report

68-year-old female patient, with a history of left lung adenocarcinoma stage IIA (T2bN0M0) who received radiotherapy with partial response with indication of chemotherapy, which she rejected. She lost follow up during 3 years, in the last chest x-ray with no evidence of disease progression. She was evaluated in an outpatient general surgery consultation due to the appearance of a 0.8 cm lesion in the abdominal wall on the right flank during the last 7 months that extends towards the dorsal region, which has progressed in size with an average growth of 1 cm per month associated with intense pain, inflammatory process in the skin and fetid discharge in the

* Corresponding author.

E-mail address: ataullah_cox@yahoo.com (A.H.M. Ataulloh).

<https://doi.org/10.1016/j.rmcr.2022.101703>

Received 12 January 2022; Received in revised form 25 May 2022; Accepted 5 July 2022

Available online 15 July 2022

2213-0071/© 2022 The Authors. Published by Elsevier Ltd. This is an open access article under the CC BY-NC-ND license (<http://creativecommons.org/licenses/by-nc-nd/4.0/>).

last month due to skin and abdominal wall soft tissue ulceration with associated local infection. The lesion fetid discharge was taken to gram and culture with *Staphylococcus aureus* colonization. The lesion was not preceded by any abdominal symptoms like constipation, diarrhea, malena, or hematochezia. The physical examination documented a lesion located on the right flank, which extends towards the dorsal region, with measurements of approximately 6×5 cm, with irregular borders, poorly defined, with abundant fetid discharge, which caused a lot of pain (Fig. 1).

Taking into account the functionality of the patient, added to her wishes not to receive further treatment, with the presence of intense pain and fetid discharge from the lesion, it was decided to take her to a toilet surgery. The patient was taken to a resection of the abdominal wall lesion without previous wedge biopsy, we found in the abdominal wall on the right flank extending towards the dorsal region a lesion of approximately 7×5 cm with irregular borders that involves the skin, the subcutaneous cellular tissue, the fibers of the latissimus dorsi muscle, innervated by intercostal nerves, and the evidence of compromise of the periosteum of the last right costal arch without the need of rib resection because this was a palliative and hygienic oncologic procedure. We made an ellipse-shaped incision that encompasses the entire lesion with resection margins of 3 cm from the superior, inferior, lateral and medial borders., due to the compromise of deep border in its upper part a resection R2 was made (Fig. 2). The block resection of the lesion was sent to pathology to perform histopathological studies. The patient was given a five days antibiotic endovenous therapy due to the associated soft tissue infection.

The pathology report confirms the presence of an adenocarcinoma, with extensive necrosis, whose morphology and immunoprofile favored pulmonary origin with negative EGFR, ALK, ROS1 mutations. The tumor infiltrated the entire thickness of the specimen and ulcerated the skin. The superior, inferior, anterior and posterior margins were found without evidence of tumor involvement, while deep margin was positive for tumor involvement. Immunohistochemistry was positive for TTF-1 and Napsin. In the postoperative period, the patient presented complete pain relief, with adequate healing of the surgical wound. Additionally, she was evaluated by oncology after 3 years of losing follow-up with the pathology report and a positron emission tomography scan (PET-SCAN) that confirmed bone metastases in the last left costal arch and brain involvement. Taking into account these findings and the desire not to perform additional management, palliative treatment was indicated.

3. Discussion

Tumors of the abdominal wall are rare. They are divided into benign lesions and malignant lesions [1]. The most frequent benign lesion that compromises the abdominal wall is endometriosis, which usually appears as a secondary process to gynecological-obstetric surgical scars in women of childbearing age, presenting as a cyclically painful nodule located in the thickness of the scar. The diagnosis is made by histological studies; however, the use of images helps to determine the characteristics of the lesion. Treatment is a wide surgical resection with margins of healthy tissue in the surgical specimen to avoid recurrence [2–4].

On the other hand, malignant lesion is composed of primary tumors and by the parietal invasion of intraabdominal tumors and metastatic parietal implants [1]. Among the primary tumors, the most frequent tumor is desmoid tumor, which corresponds to less than 3% of all soft tissue tumors and 0.03% of all neoplasms [5], which in the majority of the cases appear in young women, during pregnancy or followed by child-birth, which suggests a hormonal factor involved, also is associated with familial adenomatous polyposis (Gardner syndrome) [6,7]. This lesion is followed by soft tissue sarcomas, which represent less than 1% of all malignant tumors in the adult population, they are usually sporadic and of unknown etiology, with one characteristic which is there are multiple histological subtypes and not all of them involve the abdominal wall [8]. Finally, there is dermatofibrosarcoma protuberans, which has an incidence of approximately 0.8–4.5 cases per million habitants per year, which corresponds to 1–6% of soft tissue sarcomas, which affects young male adults between 20 and 50 years [9,10]. All of the lesions mentioned above require a histological diagnosis made by a prior biopsy and an image ideally an magnetic resonance imaging (MRI) to plan surgical management, in which ideally a block resection should be performed in all cases [6–9].

The incidence of metastatic abdominal wall lesions is approximately 0.7–9%, direct invasion and tumor implants in the abdominal wall can be due to tumors of various types and locations. The most common causes of metastasis in the abdominal wall is metastases of neoplasms of colonic origin, gastric origin, and in some cases and with the emergence of laparoscopic surgery, incidence of metastases

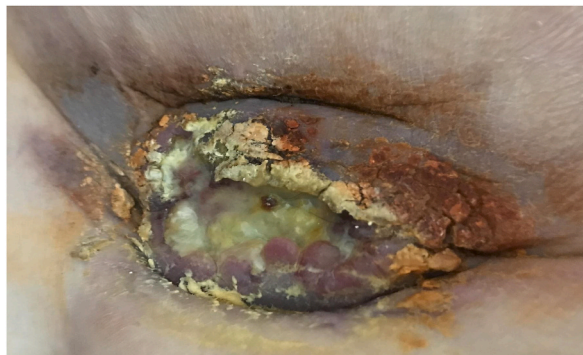

Fig. 1. Lesion located on the right flank, which extends towards the dorsal region, with measurements of approximately 6×5 cm, with irregular borders, poorly defined, with abundant fetid discharge, which caused a lot of pain.

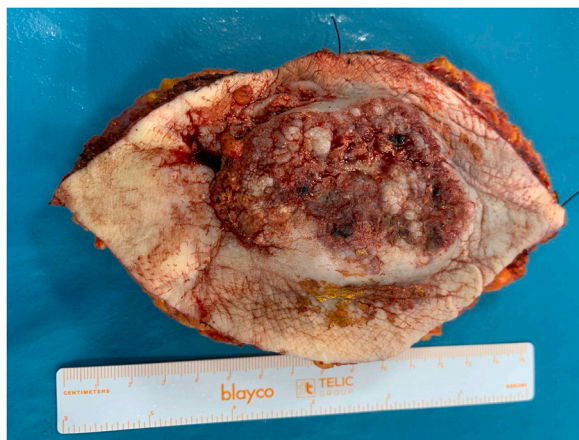


Fig. 2. Ellipse-shaped incision that encompasses the entire lesion with resection margins of 3 cm from the superior, inferior, lateral and medial borders., due to the compromise of deep border in its upper part a resection R2 was made.

in the implants of trocar holes has been reported from 0.7 to 1.3% [11]. Metastases from lung cancer are uncommon with a reported overall prevalence of 2.3%, the major sites of metastases include the liver (33–40%), adrenal glands (18–38%), brain (15–43%), bone (19–33%), kidney (16–23%) and abdominal lymph nodes (29%) [11–14]. Currently, there are no reports in the literature of pulmonary adenocarcinoma coursing with abdominal wall metastasis. In the case of metastasis in the abdominal wall, the image of choice for the diagnosis and for the planning of surgical management is and MRI, although a computed tomography scan (CT scan) can provide useful information. Also, in most of the cases a biopsy should be performed to confirm the diagnosis [11–17].

In the case of our patient, taking into account her comorbidities, the functional deterioration secondary to the neurological sequelae of the cerebrovascular accident, the physical examination findings, added to her desire to not to perform additional management, it was decided to perform a toilet surgery. During the surgical procedure, an R2 resection was performed, the lesion was excised in block with negative section margins except for the deep margin which was positive for tumoral cells. Pathology confirmed the presence of an adenocarcinoma with immunohistochemistry which was positive for TTF-1 and Napsine which favor its pulmonary origin. Currently the patient is being followed up by clinical oncology with the intention of palliative management, with complete pain relief.

This case demonstrates that although metastasis of the abdominal wall is a rare condition it should be taken into account as a diagnosis in the presence of a lesion in the abdominal wall summed up to the history of a neoplasm. Additionally, this case shows that patient management must be individualized, and in some cases, patient can benefit only from a toilet surgery and palliative treatment, relieving the patient symptoms and improving the quality of life.

4. Conclusion

Metastasis of the abdominal wall secondary to pulmonary adenocarcinoma is a rare condition in which surgical treatment is the mainstay of management along with supportive neoadjuvant therapy if needed. The preoperative study with images and biopsy in most of the cases is of vital importance to make a proper diagnosis and guide the surgical approach. However, some patients, as in our case, can benefit from a toilet surgery and palliative treatment.

Ethical approval

The present work was approved by the ethics committee of the Fundacion Santa Fe de Bogota.

Funding source

The present work was self-financed.

Informed consent

Written informed consent was obtained from the patient for the publication of this case and its attached images.

Declaration of competing interest

The authors declare no conflicts of interest.

Acknowledgement

None.

References

- [1] A. Stojadinovic, A. Hoos, H.M. Karpoff, D.H. Leung, C.R. Antonescu, M.F. Brennan, et al., Soft tissue tumors of the abdominal wall. Analysis of disease patterns and treatment, *Arch. Surg.* 136 (1) (2001) 70–79.
- [2] T. Santana, J.L. Estepa, J.C. Estepa, Abdominal wall endometrioma. Report of two cases, *MediSur* 12 (4) (2014) 670–675.
- [3] R. Ortega Herrera, F. Serrano Puche, E. Prieto Sánchez, I. Gómez de Travecedo y Calvo, P. López Marín, M.J. Rubí Uriá, Endometriosis of the abdominal wall, *Progresos Obstet. Ginecol.* 55 (8) (2012) 367–372.
- [4] J.D. Horton, K.J. Dezee, E.P. Ahnfeldt, M. Wagner, Abdominal wall endometriosis: a surgeon's perspective and review of 445 cases, *Am. J. Surg.* 196 (2) (2008) 207–212.
- [5] J.J. Reitamo, P. Häyry, E. Nykyri, E. Saxén, The desmoid tumor. I. Incidence, sex-, age- and anatomical distribution in the Finnish population, *Am. J. Clin. Pathol.* 77 (6) (1982) 665.
- [6] V. Mundra, A rare case of rectus abdominis metastasis adenocarcinoma, *Am J Case Rep* 13 (2012) 177–179.
- [7] H.J. Mankin, F.J. Hornicek, D.S. Springfield, Extra-abdominal desmoid tumors: a report of 234 cases, *J. Surg. Oncol.* 102 (5) (2010) 380.
- [8] L. Koskenvuo, P. Peltomäki, L. Renkonen-Sinisalo, A. Gylling, T.T. Nieminen, A. Ristimäki, et al., Desmoid tumor patients carry an elevated risk of familial adenomatous polyposis, *J. Surg. Oncol.* 113 (2) (2016) 209–212.
- [9] J.H. Choi, J.Y. Ro, The 2020 WHO classification of tumors of soft tissue: selected changes and new entities, *Adv. Anat. Pathol.* 28 (1) (2021) 44–58.
- [10] H.M. Gloster Jr., Dermatofibrosarcoma protuberans, *J. Am. Acad. Dermatol.* 35 (3 Pt 1) (1996) 355.
- [11] P. Rouhani, C.D. Fletcher, S.S. Devesa, J.R. Toro, Cutaneous soft tissue sarcoma incidence patterns in the U.S.: an analysis of 12,114 cases, *Cancer* 113 (3) (2008) 616.
- [12] R. Koyama, Y. Maeda, N. Minagawa, T. Shinohara, T. Hamada, Laparoscopic resection of an abdominal wall metastasis 5 Years after primary colorectal cancer resection, *Case Rep. Gastroenterol.* 13 (2019) 78–84.
- [13] I. Kikuchi, K. Nishida, M. Kurosuni, T. Yatsuoka, Y. Nishimura, H. Sakamoto, et al., [An operated case of metastasis to the small intestine from lung cancer], *Gan To Kagaku Ryoho* 38 (12) (2011) 2372–2374.
- [14] A. Berger, C. Cellier, C. Daniel, C. Kron, M. Riquet, J.P. Barbier, et al., Small bowel metastases from primary carcinoma of the lung: clinical findings and outcome, *Am. J. Gastroenterol.* 94 (7) (1999) 1884–1887.
- [15] D. Pop, A.S. Nadeemy, N. Venissac, P. Guiraudet, J. Otto, M. Poudenx, et al., Skeletal muscle metastasis from non-small cell lung cancer, *J. Thorac. Oncol.* 4 (10) (2009) 1236–1241.
- [16] H.H. Kwas, I. Zendah, H. Ghedira, Skeletal muscle metastases from lung cancer, *Asian Cardiovasc. Thorac. Ann.* 21 (6) (2013) 741–743.
- [17] J.B. Seo, J.G. Im, J.M. Goo, M.J. Chung, M.Y. Kim, Atypical pulmonary metastases: spectrum of radiologic findings, *Radiographics* 21 (2) (2001) 403–417.