

# Repigmentation of White Forelock in a Familial Case of Piebaldism Reported via Teledermatology in the COVID-19 Era

Francesca Gaudiello Maria Ferrillo Maria Vastarella Gabriella Fabbrocini  
Angela Patrì

Department of Clinical Medicine and Surgery, Section of Dermatology, University of Naples Federico II, Napoli, Italy

## Established Facts

- The complete regression of white forelock (WF) is an extremely rare event.

## Novel Insights

- Ours is the fifth case of WF repigmentation.

## Keywords

COVID-19 · Teledermatology · Piebaldism · White forelock · Repigmentation

## Abstract

Piebaldism is a rare autosomal dominant disorder characterized by leucoderma with leucotrichia. We describe a case of white forelock repigmentation in an infant with piebaldism, thanks to a photograph sent by the patient's mother to our dermatology clinic, during COVID-19 pandemic.

© 2020 S. Karger AG, Basel

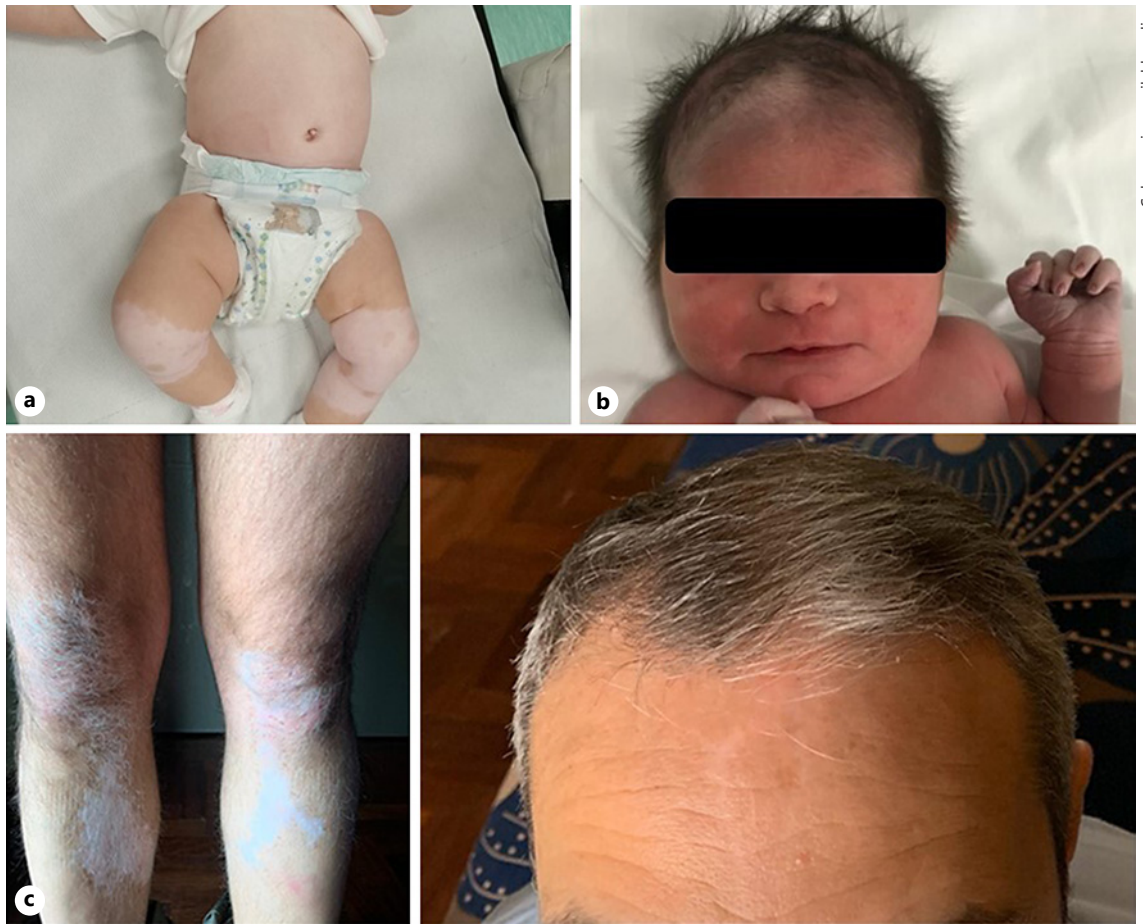## Introduction

Piebaldism is a rare autosomal dominant disorder characterized by leucoderma with leucotrichia typically localized on the abdomen, knees, and forehead, where it

is known as white forelock (WF) [1]. It is due to genetic defects in melanocytes' migration, resulting in abnormal pigment patterns that are prominent at midline [2]. If leucoderma areas' contraction has been described in few cases [1], the complete regression of WF is an extremely rare event [1, 3]. Here we describe a case of WF repigmentation in an infant with piebaldism, thanks to a photograph sent by the patient's mother to our dermatology clinic, during COVID-19 pandemic.

## Case Report

An Italian baby girl was admitted to our clinic at the age of 3 months. She presented with hypopigmented macules localized around the knees, measuring up to 7 cm in the maximum length, and a WF (Fig. 1a, b). Such lesions were considered stable by parents since birth. Similar manifestations were detected in the patient's father who presented leucoderma and leucotrichia on lower limbs and ventral trunk and as well as a WF (Fig. 1c). He reported



Color version available online


**Fig. 1.** **a** Hypopigmented macules localized around the knees, measuring up to 7 cm in the maximum length, at 3 months of age. **b** WF as presented at birth. **c** Leucoderma and leucotrichia on lower limbs and WF in the baby's father. All such lesions were considered stable since birth. WF, white forelock.

that also his mother and brother had a WF and hypopigmented macules on lower limbs. The baby's history was negative for other diseases and an audiological assessment excluded eventual hearing impairment. Based on physical examination and family history, the diagnosis of piebaldism was made. The patient's parents did not accept to perform a genetic analysis. On April 2020, during COVID-19 pandemic [4], when the baby was 6 months old, her mother sent a photograph to our dermatology clinic, thanks to the teledermatology service activated to ensure patient care even during the lockdown. The WF had completely repigmented (Fig. 2).

## Discussion

Piebaldism has an incidence of 2–3 cases per 100,000 individuals [1, 4]. Mutations of the KIT gene have been detected in about 75% of cases. It encodes the tyrosine kinase receptor that binds stem cell growth factor, regu-

lating melanocytes' development and melanoblasts' migration [1, 2]. The lack of its function impairs melanoblasts' migration from neural crest to epidermis. Indeed, few or no melanocytes can be detected in leukodermic areas. Phenotypic severity correlates to KIT gene mutation type [5]. To the best of our knowledge, ours is the fifth case of WF repigmentation [1, 3]. A gene mutation analysis has been conducted only in 1 patient among the previous 4 reported cases [1, 3]. However, the mechanism behind WF regression remains unknown. Perhaps, melanocytes with specific KIT mutations could continue to migrate after birth [1]. Interestingly, Hayashibe et al. [5] reported 3 cases of tyrosinase-positive melanocytes within leukodermal lesions of piebaldism, highlighting the variability of molecular findings associated with the disease. Major differential diagnoses for this disturbance include vitiligo, particularly follicular and segmental form,



**Fig. 2.** WF repigmentation at the age of 6 months as displayed by a photograph taken by the patient's mother. WF, white forelock.

nevus anemicus, and depigmentosus. The pattern of depigmentation and/or presence of a WF helps to differentiate piebaldism with other diseases [2].

Actually, piebaldism is considered as a variant of Waardenburg syndrome which is an auditory-pigmentary disorder accounting for 2–3% of congenital deafness [2]. Congenital sensorineural hearing loss, WF, abnormal iris pigment, dystopia canthorum, musculoskeletal abnormalities, and aganglionic megacolon are possible Waardenburg syndrome manifestations [2]. Thus, in case

of suspicion for piebaldism, a detailed history and physical examination should be performed. At least 1 diagnostic auditory assessment, no later than 6 months of age, should be performed [2].

Our case highlights the variable expressivity of piebaldism. We believe that a regular long-term follow-up could be useful to not miss extraordinary evolutions of such pathology, even if via teledermatology as displayed by our experience during COVID-19 lockdown.

### Statement of Ethics

The authors have obtained the consent of the patient's parents to publish photos and details of the case.

### Conflict of Interest Statement

The authors have no conflicts of interest to declare.

### Funding Sources

None declared.

### Author Contributions

Francesca Gaudiello conceived the presented idea. Maria Ferrillo contributed to the writing of the manuscript. Maria Vastarella was involved in planning. Gabriella Fabbrocini supervised the work. Angela Patri contributed to the writing of the manuscript.

### References

- 1 Murakami T, Fukai K, Oiso N. New KIT mutations in patients with piebaldism. *J Dermatol Sci*. 2004;35(1):29–33.
- 2 Saleem MD. Biology of human melanocyte development, Piebaldism, and Waardenburg syndrome. *Pediatr Dermatol*. 2019;36(1):72–84.
- 3 Matsunaga H, Tanioka M, Utani A, Miyachi Y. Familial case of piebaldism with regression of white forelock. *Clin Exp Dermatol*. 2008; 33(4):511–2.
- 4 Patri A, Gallo L, Annunziata MC, Megna M, Fabbrocini G. COVID-19 pandemic: University of Naples Federico II Dermatology's model of dermatology reorganization. *Int J Dermatol*. 2020 Jul;59(7):e239–40.
- 5 Hayashibe K, Mishima Y. Tyrosinase-positive melanocyte distribution and induction of pigmentation in human piebald skin. *Arch Dermatol*. 1998;124(3):381–6.