

## Case Report

# The use of bone anchors for autologous flap fixation in perineal reconstruction: a case report

Adam Saad<sup>1,\*</sup>, John A. Cece<sup>1</sup>, Michael L. Arvanitis<sup>2</sup> and Andrew I. Elkwood<sup>1</sup>

<sup>1</sup>The Institute for Advanced Reconstruction at The Plastic Surgery Center, Shrewsbury, NJ, USA and <sup>2</sup>Division of Colon and Rectal Surgery, Monmouth Medical Center, Long Branch, NJ, USA

\*Correspondence address. The Institute for Advanced Reconstruction at The Plastic Surgery Center, 535 Sycamore Avenue, Shrewsbury, NJ 07702, USA. Tel: +1-732-741-0970; Fax: +1-732-212-1993; E-mail: adamsaad97@gmail.com

Received 17 May 2013; accepted 4 July 2013

The purpose of this case report is to demonstrate the use of bone anchors with an autologous flap in perineal reconstruction. This technique has not been reported before. A 64-year-old female presented to our office with a chief complaint of perineal hernia 1.5 years after abdominoperineal resection. She had a history of recurrent rectal cancer for which she received chemotherapy, radiation and surgery. To repair the hernia, a standard vertical rectus abdominomyocutaneous was harvested and de-epithelialized. It was secured into place in the pelvis utilizing several bone anchors. Mesh was used to repair the donor site defect. At 18 month follow-up, there was good healing of all the wounds and no recurrence of the hernia. She was pain free and able to resume her activities of daily living. Bone anchor fixation is a viable technique for fixation of autologous flaps in perineal reconstruction.

## INTRODUCTION

Perineal reconstruction is a challenge for any surgeon. Perineal hernia is an infrequent complication of pelvic surgery. Surgical reconstruction is needed in ~1% of the cases [1]. The lack of local tissue options leads one to consider regional flaps and synthetic mesh for reconstruction. There are multiple approaches and several regional tissue or synthetic options [2, 3]. A history of radiation to the area only further complicates reconstruction [2].

The trans-abdominal approach allows better visualization of the pelvic floor, but re-entering an operated abdomen has risk of bowel injury [4]. The perineal approach mitigates risk to the bowel, but it is more difficult to secure the repair [4]. The use of bone anchors to help secure mesh in perineal reconstruction has been described [5]. Recently, bone anchors have also been used to secure the biologic mesh [4].

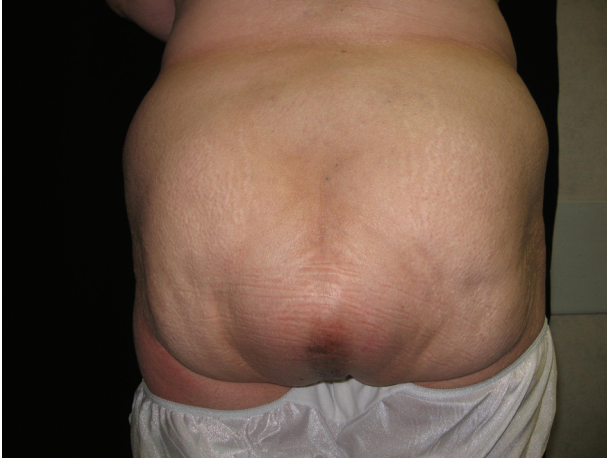When the perineum has been radiated as part of cancer treatment, mesh is not ideal for reconstruction. Regional flaps such as the vertical rectus abdominomyocutaneous (VRAM) flap or thigh based flaps are often used [6]. Traditionally, these flaps are secured to surrounding soft tissues with sutures. This tissue can be friable, especially when radiated. This can lead to unreliable reconstruction due to inability to secure the flap

reliably. We report the first known case of use of bone anchors to secure an autologous flap for perineal reconstruction.

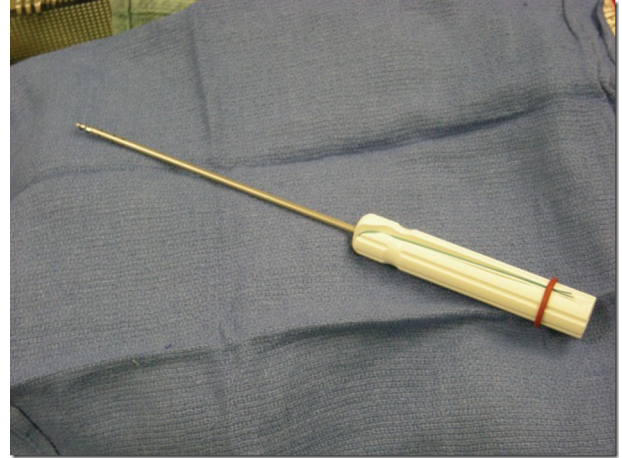
## CASE REPORT

A 64-year-old female presented to our office with a perineal hernia (Fig. 1) 1.5 years after abdominoperineal resection (APR). She had a history of recurrent low-lying rectal cancer for which she received neoadjuvant external beam radiation and chemotherapy, followed by APR. Physical examination showed the hernia was reducible and tender to palpation. Radiation skin changes were also noted in the perineum. The patient reported not being able to sit due to pain related to the hernia. She also did have a large ventral hernia related to her previous abdominal surgeries.

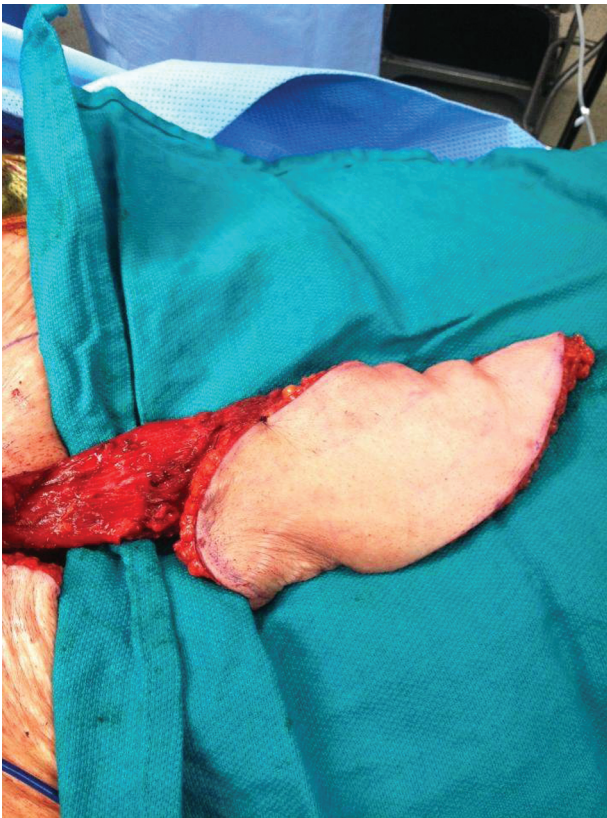Due to her history of perineal radiation, we decided to treat her with a VRAM (Fig. 2) via trans-abdominal approach. There was concern about securing the flap in the perineum due to the size of the defect and previous radiation making the tissues friable. In light of this, we decided to use bone anchor fixation to secure the autologous flap. She also underwent abdominal wall reconstruction with separation of components and mesh placement during the same operation.



**Figure 1:** Posterior view of the patient upon initial presentation. There is a large bulging area where the APR was performed. The hernia was soft and reducible.

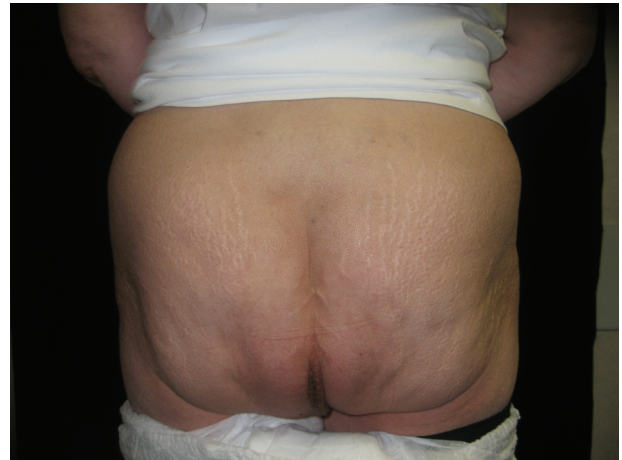


**Figure 3:** A Mitek Fastin bone anchor. The suture is attached to the bone anchor and is seen running in the handle.



**Figure 2:** Intra-operative photo of VRAM harvest.

A standard VRAM was harvested from the abdominal wall. The bowel and abdominal contents were then returned to the abdominal cavity. Several Fastin Mitek brand (Raynham, MA) bone anchors were placed in the bones surrounding the pelvic outlet, including the fecal promontory, pubic tubercle and pelvic rim (Fig. 3). Holes were pre-drilled after the bone had been exposed. The anchors were then screwed into place with suture attached. Care was taken not to injure the ureters, sacral venous



**Figure 4:** One-year post-operative posterior view of the patient. The hernia repair is intact and the patient is symptom free.

plexus, surrounding nerves and blood vessels. The skin of the flap of the VRAM was de-epithelialized. The bone-anchored suture was then passed through the dermis of the flap. The flap was parachuted down into the pelvis and the sutures were tied to secure the flap in place. This created a pelvic sling to close off the pelvic inlet from the abdominal cavity.

Post-operatively the patient did well. She did however present with infected abdominal mesh 3 months after surgery. She was returned to the OR for removal of the abdominal mesh. The perineal repair at that time was intact. At 18 month follow-up, there was good healing of all the wounds and no recurrence of either hernia (Fig. 4).

## DISCUSSION

Perineal hernia is a challenge for any surgeon. There are multiple risk factors for the development of a perineal hernia

including female sex, major abdominopelvic surgery and irradiation as was seen in our patient [2]. Smoking is also a well-known risk factor for hernia and again our patient had this risk factor [7]. Despite these risks, perineal reconstruction occurs only in ~1% of major abdominopelvic surgery [1].

Use of synthetic and biologic meshes in hernia repair has widely been reported [2, 4, 5]. Mesh can be placed either trans-abdominally or perineally. Fixation of the mesh has traditionally been with sutures to the surrounding tissues. Use of bone anchor fixation techniques has also recently been reported [4, 5]. Bone anchors provide reliable fixation of mesh that is not reliant on soft tissue strength [4, 5]. Their use in orthopedics is widely reported and their use in ventral hernia repair has been recently described [8, 9]. In addition, their use in pelvic reconstruction has been reported by urologists for bladder slings [10].

When the patient has been irradiated, the challenge becomes greater [2]. The soft tissues of the pelvis are often friable and unreliable for fixation. Placement of mesh in these patients is not ideal and can lead to further complication such as mesh erosion, infection and recurrence. In these patients, autologous tissue is the reconstruction of choice. There are multiple options including the VRAM, gracilis, thigh-based flaps, omental flaps [6, 7]. The VRAM provides both muscle and skin to reconstruct the perineum [6]. We prefer it to the other options listed above. It does, however, require trans-abdominal approach and can lead to donor site morbidity such as ventral hernia.

Traditionally, the VRAM is secured into place using suture to the surround pelvic ring soft tissues or periosteum [6]. However, in irradiated patients, we feel that this does not provide the strength needed to secure the flap to prevent recurrence. We applied the use of bone anchors to provide a secure platform on which to secure the autologous flap.

In our patient, the bone anchors enabled us to securely fixate our autologous flap on a stable platform for pelvic floor

reconstruction. This is the first report of use of bone anchors to aid in autologous reconstruction of the pelvic floor. The patient reports no recurrence to date and resolution of her pain. We recommend the use of bone anchors to secure autologous soft tissue flaps when surrounding tissues are not suitable for suture fixation. Bone anchors are easy to use, provide stable fixation and have low morbidity.

No external funding was received for the composition of this manuscript.

## REFERENCES

1. Beck DE, Fazio VW, Jagelman DG, Lavery IC, McGonagle BA. Postoperative perineal hernia. *Dis Colon Rectum* 1987;**30**:21–4.
2. Veenhof AA, van der Peet DL, Cuesta MA. Perineal hernia after laparoscopic abdominoperineal resection for rectal cancer: report of two cases. *Dis Colon Rectum* 2007;**50**:1271–4.
3. Gómez Portilla A, Cendoya I, Uzquiza E, Martin E, Martínez de Lecea C, Gómez C, et al. Giant perineal hernia: laparoscopic mesh repair complemented by a perineal cutaneous approach. *Hernia* 2010;**14**:199–201.
4. Kathju S, Lasko LS, Medich DS. Perineal hernia repair with acellular dermal graft and suture anchor fixation. *Hernia* 2011;**15**:357–60.
5. Ong SL, Miller AS. Transperineal approach to perineal hernia repair using suture anchors and acellular porcine dermal mesh. *Tech Coloproctol* 2011. DOI: 10.1007/s10151-011-0774-5A.
6. Sunesen KG, Buntzen S, Tei T, Lindegaard JC, Nørgaard M, Laurberg S. Perineal healing and survival after anal cancer salvage surgery: 10-year experience with primary perineal reconstruction using the vertical rectus abdominismyocutaneous (VRAM) flap. *Ann Surg Oncol* 2009;**16**:68–77.
7. Aboian E, Winter DC, Metcalf DR, Wol VBG. Perineal hernia after proctectomy: prevalence, risks, and management. *Dis Colon Rectum* 2006;**49**:1564–8.
8. Kulwicksi KJ, Kwon YW, Kummer FJ. Suture anchor loading after rotator cuff repair: effects of an additional lateral row. *J Shoulder Elbow Surg* 2010;**19**:81–5.
9. Ali AA, Malata CM. The use of Mitek bone anchors for synthetic mesh fixation to repair recalcitrant abdominal hernias. *Ann Plast Surg* 2012;**69**:59–63.
10. Giberti C, Gallo F, Schenone M, Cortese P, Ninotta G. The bone anchor suburethral synthetic sling for iatrogenic male incontinence: critical evaluation at a mean 3-year follow up. *J Urol* 2009;**181**:2204–8.