

Homocysteinemia: A rare cause of priapism

Jaisukh Kalathia, Santosh Agrawal, Saurabh Sudhir Chipde, Rajeev Agrawal

Department of Urology and Kidney Transplantation, Sri Aurobindo Institute of Medical Sciences, Indore, Madhya Pradesh, India

Abstract

Priapism is a persistent painful erection that continuous beyond or is unrelated to sexual stimulation. Majority of cases are idiopathic (46%), alcohol and drug related (21%), perineal trauma (12%), sickle cell anemia and hypercoagulable state related (11%). We report case of priapism caused by hyperhomocysteinemia with favorable outcome with only few cases so far reported in the literature to the best of our knowledge. A 31 year-old male referred to our institution with non resolving priapism for the last 6 days. Immediate distal shunt (Al-ghorab) was created but it could not achieve the detumescence. The penile Doppler showed no flow into the corpora, so a proximal shunt (Quackels) was made which achieved satisfactory detumescence. On thorough evaluation for the cause of priapism, only homocysteine level was found to be significantly raised (40.46 $\mu\text{mol/L}$), being the unusual and rare cause for priapism. The patient was discharged on homocheck. In the follow-up the patient is on vacuum assisted device for the erectile dysfunction and has been advised for the penile implant. Priapism being a urological emergency should be thoroughly evaluated even for the rare causes and should be timely intervened to avoid the unavoidable consequences of permanent erectile dysfunction.

Key Words: Homocysteinemia, priapism, shunt

Address for correspondence:

Dr. Santosh Agrawal, Department of Urology and Kidney Transplantation, Sri Aurobindo Institute of Medical Sciences, Indore, Madhya Pradesh, India.

E-mail: santro4you@yahoo.com

Received: 13.08.2015, Accepted: 04.11.2015

INTRODUCTION

Priapism is a persistent, prolonged painful erection that continues beyond or is unrelated to sexual stimulation. It is rare, but potentially devastating urological emergency that can result in permanent erectile dysfunction if not intervened timely.^[1] Most common causes are idiopathic (30–50%), sickle cell anemia, leukemia, and drug-related. The goal of management is to achieve detumescence, relieve pain, and preserve the erectile function. We report a case of priapism caused by hyperhomocysteinemia with favorable outcome

with only few cases so far reported in literature to the best of our knowledge.

CASE REPORT

A 31-year-old male patient referred with nonresolving priapism for the last 6 days. There was no predisposing factor as per the history given by the patient. The patient was managed initially conservatively outside, but his symptoms did not improve. On examination, the penis was rigid and firm in consistency with severe tenderness [Figure 1]. Analysis of arterial blood gas from corpora showed pH 7.018 and pO_2 22.7. The routine

Access this article online	
Quick Response Code:	Website: www.urologyannals.com
	DOI: 10.4103/0974-7796.171497

This is an open access article distributed under the terms of the Creative Commons Attribution-NonCommercial-ShareAlike 3.0 License, which allows others to remix, tweak, and build upon the work non-commercially, as long as the author is credited and the new creations are licensed under the identical terms.

For reprints contact: reprints@medknow.com

How to cite this article: Kalathia J, Agrawal S, Chipde SS, Agrawal R. Homocysteinemia: A rare cause of priapism. *Urol Ann* 2016;8:118-21.

investigation including complete blood count and renal functions was normal. The penile Doppler showed no flow into the corpora cavernosa (CC) [Figure 2].

Immediate aspiration from cavernosa using I6G cannula showed minimal deoxygenated blood [Figure 1]. The patient was taken immediately for the distal cavernoglanular shunt (Al-Ghorab), but it could not achieve detumescence even after few hours of observation. Hence, a proximal shunting between the corpus cavernosum and the corpus spongiosum (Quackels shunt) was created, which achieved favorable detumescence and relieved the patient symptomatically.

The postoperative period was uneventful with satisfactory detumescence [Figure 3]. A repeat penile Doppler showed minimal flow in the proximal shunt. On thorough investigation for the cause of priapism, only homocysteine level was found to be significantly raised ($40.46 \mu\text{mol/L}$), which could be the unusual and rare cause for the priapism. The patient was discharged on Homocheck to reduce the levels of homocysteine. In the follow-up period, the patient has satisfactory erection but for the complete erection is using vacuum-assisted device and is doing well.

DISCUSSION

The priapism is of three types namely, ischemic, nonischemic, and stuttering. Ischemic priapism is a persistent erection marked by rigidity of the CC and little or no cavernous arterial inflow. There are time dependent changes in the corporal metabolic environment with progressive hypoxia, hypercarbia, and acidosis. It warrants emergency management as it represents a true compartment syndrome involving the penis. Therefore, if not be timely intervened, it results in permanent tissue damage. Nonischemic priapism is a persistent erection caused by unregulated cavernous arterial inflow which may be due to blunt trauma or an iatrogenic needle injury. The corpora are tumescent but not rigid, and the penis is not painful. Here, the cavernous environment does not become ischemic, and cavernous blood gases do not show hypoxia, hypercarbia, or acidosis as seen in ischemic priapism. Therefore, it does not require emergent intervention and may be managed conservatively, although treatment options are available for men who desire resolution of the problem. Finally, the stuttering priapism is characterized by a pattern of recurrence such that there are recurrent unwanted and painful erections in men with sickle cell disease.

The majority of the cases of priapism are idiopathic (46%), alcohol and drug-related (21%), perineal trauma (12%), sickle cell anemia, and hypercoagulable state-related (11%).^[2] In the immediate management of priapism, it requires

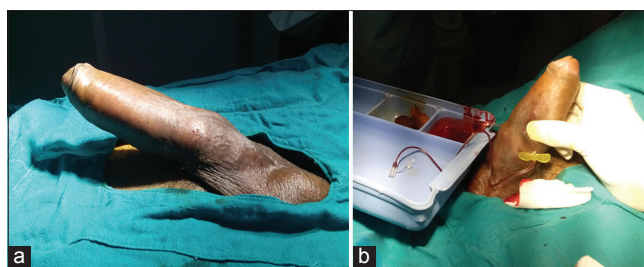

Figure 1: (a) On examination, the penis was rigid and firm in consistency (b) immediate aspiration from cavernosa using 16G needle showed minimal deoxygenated blood

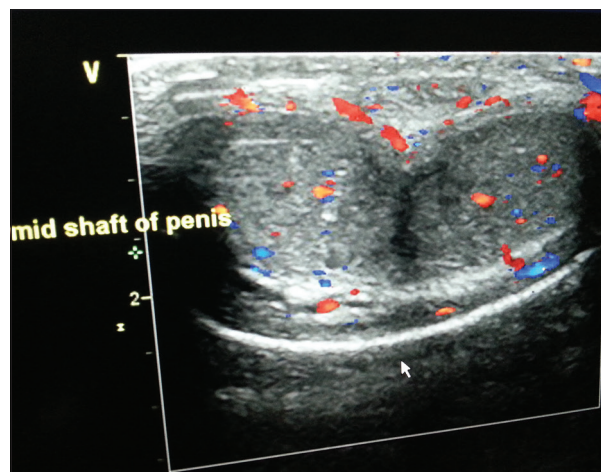


Figure 2: Penile Doppler showed no flow into the corpora cavernosa

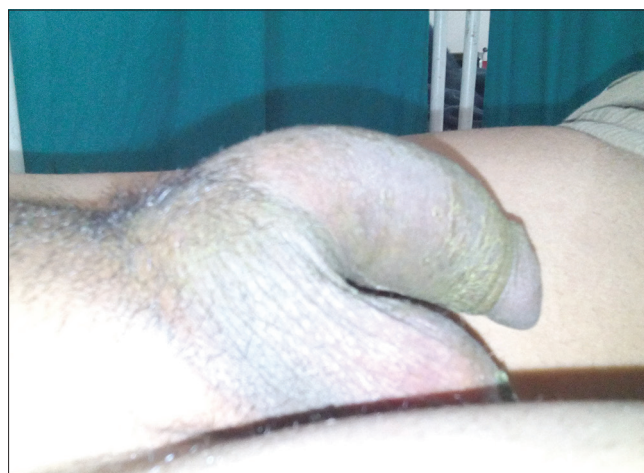

Figure 3: Satisfactory detumescence achieved

insertion of a vein needle directly into the corpus cavernosum to aspirate blood, which solves both diagnostic and therapeutic purposes. It may resolve the following aspiration with or without irrigation in approximately 30% of patient presentations.^[1] Literature suggests that a higher resolution of ischemic priapism follows the concomitant use of sympathomimetic agents with or without irrigation (43–81%) than aspiration with or without irrigation alone (24–36%).^[3]

Surgical shunting is recommended for priapism refractory to intracavernous treatment with primary objective to provide a shunt between the corpus cavernosum and glans penis, corpus spongiosum, or a vein so that the obstructed veno-occlusive mechanism is bypassed. The distal cavernoglanular shunt procedure is performed first in which there is a transgranular placement of large-bore needle or angiocatheter (Winter shunt) or a scalpel (Ebbehøj shunt).^[4,5] Brant *et al.* described the T-shaped distal shunt between the CC and glans penis where a No. 10 blade is placed vertically through the glans 4 mm away from the meatus. The blade pierces through the glans to CC and is rotated 90° away from the urethra and removed.^[6] Followed by milking out, deoxygenated blood out of the wound. The open distal shunt, wherein excising the tunica albuginea at the tip of the corpus cavernosum (Al-Ghorab shunt) or “Corporal Snake,” can be used to resolve ischemic priapism refractory to first-line interventions.^[7]

In case of failure of distal shunting, a more definitive open proximal shunting between the corpus cavernosum and the corpus spongiosum can be performed. The most commonly described proximal shunt is the unilateral shunt, described by Quackles in 1964 or bilateral shunt by Sacher in 1972 which requires a transscrotal or transperineal approach. The cavernosaphenous shunt described by Grayhack *et al.* have been tried as shunt procedures, in resistant cases in which the saphenous vein is mobilized below the junction of the femoral vein and anastomosed the vein end to side into the corpus cavernosum.^[8] Finally, the deep dorsal vein (DDV) shunt with distal ligation of DDV and anastomosis of proximal DDV to corpus cavernosum described by Barry in 1976. The success rates for various surgical decompression procedures are around 75%.^[1]

The penile Doppler study plays a key radiological tool in assessing priapism. In the acute setting, it serves as an adjunct to clinical assessment and cavernosal blood gas analysis to provide the essential diagnostic distinction between ischemic and nonischemic priapism.^[1] The cavernosal blood flow typically will be absent with high resistance in ischemic priapism. Here, the sinusoids will be engorged showing low (or mixed) echogenicity depending on the completeness of sinusoidal thrombosis. The Doppler study also provides information about the degree of resolution, either spontaneous or following treatment and useful in the follow-up assessment.

The partial priapism, also called as partial segmental thrombosis of the corpus cavernosum, is a rare urological condition. It was first described by Gottesman in 1976.^[9] In literature, only 34 cases have been described, and the condition's etiology still remains unclear due to the low number of reported

cases.^[10] Complete penile cavernosal thrombosis due to hyperhomocysteinemia has not been reported in the literature, but Blaut *et al.* reported the first case of partial penile thrombosis due to hyperhomocysteinemia.^[11]

In this case, there were no predisposing factors or hematological abnormality detected on the initial evaluation except for the raised homocysteine found postoperatively. Homocysteinemia defined as elevation of the homocysteine level (normal 2.2–13.2 μmol/L) in blood; whereas in our patient, it was found to be significantly raised (40.46 μmol/L), which could be the unusual cause for the patient's priapism.

Elevated homocysteine levels are related with hypercoagulability and arterial thrombosis.^[12] The deficiencies of Vitamin B6, folic acid (Vitamin B₉), and vitamin B12 can lead to high homocysteine levels.^[13] Hyperhomocysteinemia is typically managed with Vitamin B6, Vitamin B9, and Vitamin B12 supplementation.^[14] Taurine supplementation also has been found to reduce homocysteine levels.^[15] There are multiple possible etiologies of the patient's priapism; however, it appears that homocysteinemia was likely a predisposing factor, and we believe that this represents an important public health issue.

CONCLUSION

Priapism should be thoroughly investigated for the various predisposing factor including all the hematological disorders. Hyperhomocysteinemia can be a causative factor for priapism. We suggest that homocysteine levels should be included in the initial evaluation of priapism.

Financial support and sponsorship

Nil.

Conflicts of interest

There are no conflicts of interest.

REFERENCES

1. Montague DK, Jarow J, Broderick GA, Dmochowski RR, Heaton JP, Lue TF, *et al.* American Urological Association guideline on the management of priapism. *J Urol* 2003;170 (4 Pt 1):1318-24.
2. Raveenthiran V. A modification of Winter's shunt in the treatment of pediatric low-flow priapism. *J Pediatr Surg* 2008;43:2082-6.
3. Mantadakis E, Ewalt DH, Cavender JD, Rogers ZR, Buchanan GR. Outpatient penile aspiration and epinephrine irrigation for young patients with sickle cell anemia and prolonged priapism. *Blood* 2000;95:78-82.
4. Winter CC. Cure of idiopathic priapism: New procedure for creating fistula between glans penis and corpora cavernosa. *Urology* 1976;8:389-91.
5. Ebbehøj J. A new operation for priapism. *Scand J Plast Reconstr Surg* 1974;8:241-2.
6. Brant WO, Garcia MM, Bella AJ, Chi T, Lue TF. T-shaped shunt and intracavernous tunneling for prolonged ischemic priapism. *J Urol* 2009;181:1699-705.

7. Ercole CJ, Pontes JE, Pierce JM Jr. Changing surgical concepts in the treatment of priapism. *J Urol* 1981;125:210-1.
8. Grayhack JT, McCullough W, O'conor VJ Jr, Trippel O. Venous bypass to control priapism. *Invest Urol* 1964;1:509-13.
9. Gottesman JE. Recurrent partial priapism. *Urology* 1976;7:519-20.
10. Horger DC, Wingo MS, Keane TE. Partial segmental thrombosis of corpus cavernosum: Case report and review of world literature. *Urology* 2005;66:194.
11. Blaut S, Schneider M, Zschuppe E, Günl U, Steinbach F. Partial unilateral penile thrombosis of corpus cavernosum due to hyperhomocysteinemia. Case report and references. *Urologe A* 2008;47:748-52.
12. Austin S, Cohen H, Losseff N. Haematology and neurology. *J Neurol Neurosurg Psychiatry* 2007;78:334-41.
13. Miller JW, Nadeau MR, Smith D, Selhub J. Vitamin B-6 deficiency vs folate deficiency: Comparison of responses to methionine loading in rats. *Am J Clin Nutr* 1994;59:1033-9.
14. van Guldener C, Stehouwer CD. Homocysteine-lowering treatment: An overview. *Expert Opin Pharmacother* 2001;2:1449-60.
15. Ahn CS. Effect of taurine supplementation on plasma homocysteine levels of the middle-aged Korean women. *Adv Exp Med Biol* 2009;643:415-22.