

Delayed complication of abdominal aortic stent: a rare complication

Sivakumar Sudhakaran¹, Zoya Surani² and Salim R Surani¹

¹Texas A&M University Health Science Center, Houston Methodist Hospital, Houston, Texas 77030, USA

²Pulmonary Associates, 1177 West Wheeler Ave, Aransas Pass, Texas 78336, USA

Corresponding author: Salim R Surani. Email: srsurani@hotmail.com

Lesson

We hereby present a case of recurrent abdominal aortic aneurysm due to endoleak to outline complications and secondary intervention strategies post endovascular aneurysm repair.

Keywords

Endovascular stent, abdominal aortic aneurysm, abdominal aortic aneurysm leak, stent fracture

A 75-year-old man presented to the emergency department with stabbing abdominal pain that radiated to his lower back. The patient denied fever, chills, diaphoresis and chest pain. Medical history was significant for a massive infrarenal abdominal aortic aneurysm in 2011, which measured approximately 14 cm by 12 cm prior to treatment. Details of endovascular management were as follows: a Talent Thoracic Endovascular Stent Graft (Medtronic, Minneapolis, MN) measuring 46 × 46 × 52 mm was introduced via the right femoral artery and was anchored in the suprarenal position. The main body, deployed inferiorly, was an Endurant II Stent Graft (Medtronic, Minneapolis, MN) measuring 36 × 18 × 155 mm and was introduced via the left femoral artery. Iliac extenders were positioned on both sides, with the right iliac extension measuring 28 × 28 × 40 mm and the left iliac extension measuring 18 × 24 × 85 mm. The patient also had a history of hypertension, chronic obstructive pulmonary disease, gastroesophageal reflux disease and dyslipidemia. Moreover, the patient had a 40 pack/year smoking history, and claimed to have quit smoking three years prior to presentation.

A two-dimensional echocardiogram indicated no evidence of pericardial effusion, intracardiac mass or valvular vegetation. A normal thickening of aortic valve leaflets consistent with aortic sclerosis due to aging was noted. The patient's ejection fraction was greater than 60% and cardiac chambers were normal in size with no decrease in left ventricle

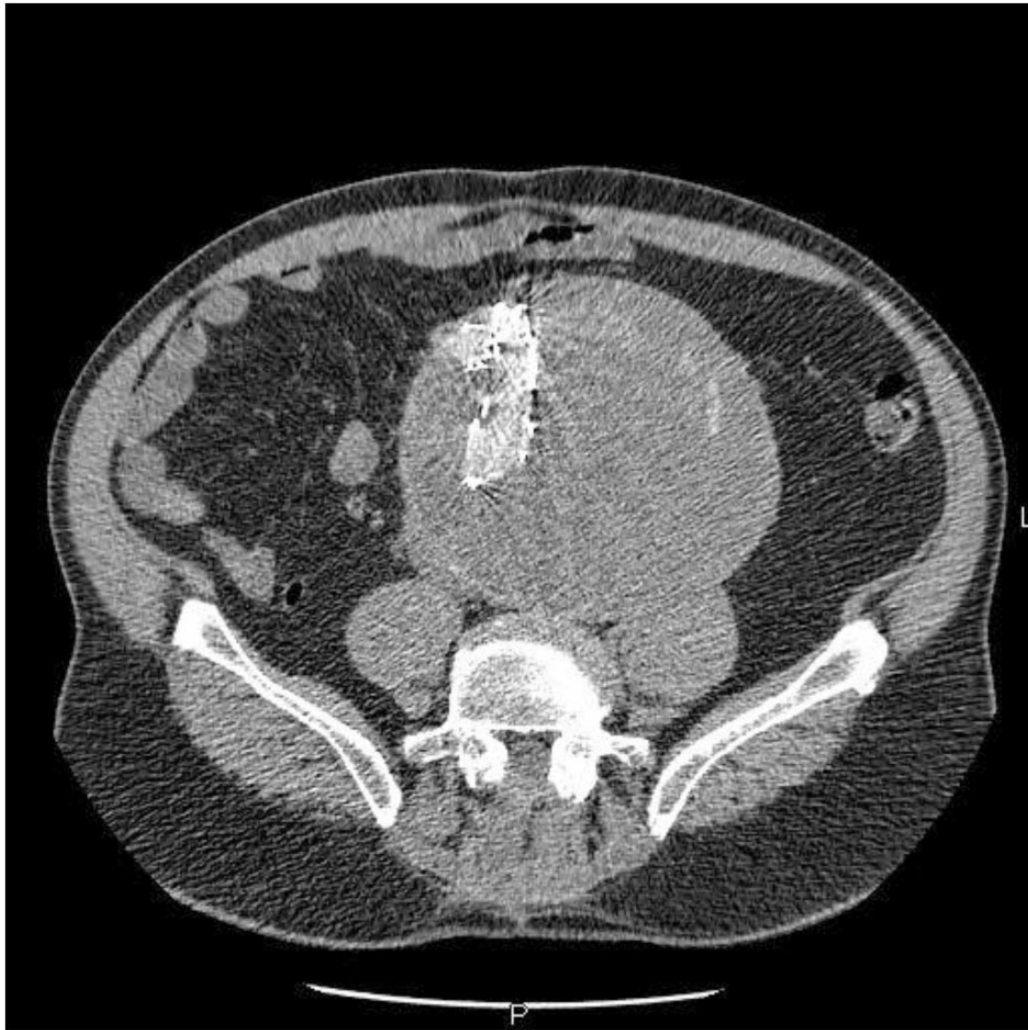
function. However, after completion of CT angiogram, endoleak Type III was noted in the right iliac stent along the inferior margin of the aneurysmal sac. Upon closer visualization, the right iliac graft appeared fragmented and mildly displaced with a small amount of extraluminal contrast adjacent to the compromised right iliac stent (Figures 1 and 2). The upper aspect of the aortic stent appeared slightly expanded when compared to previous examinations; however, no contrast extravasation was imaged. Lab values included a haemoglobin level of 10.0 gm/dL, platelet count of 184 K/μL, blood urea nitrogen of 24 mg/dL and creatinine level of 1.3 mg/dL. Open surgical repair was recommended to treat the expanding abdominal aortic aneurysm, which now measured approximately 15.5 cm due to vascular endoleak.

During surgery, the neck of the aneurysm was found to be just below the renal arteries. A size 22 Vascutek Gelsoft Bifurcated Graft (Terumo, Shibuya, Tokyo) was anastomosed end-to-end to the neck of the aneurysm utilizing Prolene (Ethicon, Blue Ash, OH) sutures. The patient tolerated the procedure well with no complications and remained asymptomatic during planned follow-up in clinic.

Discussion

The risk of abdominal aortic aneurysm increases after 60 years of age, and is present in approximately 1% of men between ages 55 through 64 with its prevalence increasing by 2% to 4% each decade thereafter.^{1,2} Furthermore, abdominal aortic aneurysms are four to six times more common in males than females.^{3,4} Diagnosis of abdominal aortic aneurysm can be difficult, as the majority of cases are generally asymptomatic and are often incidental findings on imaging studies. A symptomatic aneurysm producing pain and tenderness upon palpation is generally at an increased risk for rupture. Patients with ruptured abdominal aortic aneurysm classically present with a pulsatile abdominal mass as well as shooting

Figure 1. CT angiogram of abdomen revealing fractured endovascular stent with endoleak.

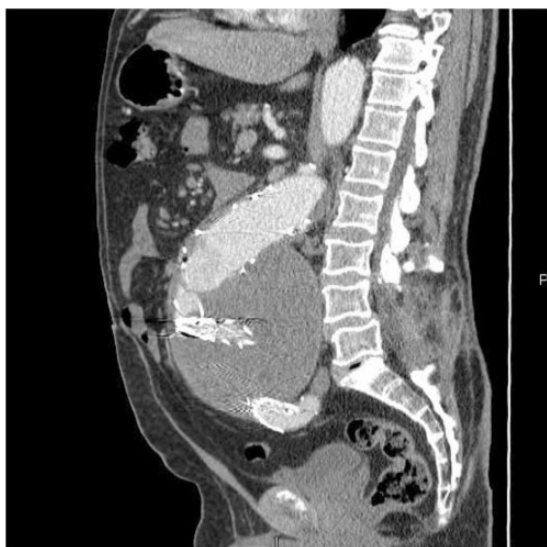

pain in the abdominal or lower back areas.⁵ Acute abdominal aortic aneurysm rupture is a serious clinical emergency and is responsible for roughly 4% to 5% of deaths in the United States.⁶ On average, only 50% of patients with ruptured abdominal aortic aneurysm reach the hospital alive; of those who do reach the hospital, only 50% survive surgery.⁷ Abdominal ultrasonography (USG) is considered the screening tool of choice for abdominal aortic aneurysm because of its sensitivity of 95% to 100% and specificity of nearly 100%. Moreover, abdominal ultrasonography (USG) is safe and has a relatively low cost of operation.^{8,9} The American College of Cardiology/American Heart Association (ACC/AHA) recommends that men 60 years of age or older who have siblings or parents with abdominal aortic aneurysm should undergo physical examination and abdominal USG screening. Additionally,

men from the age of 65 to 75 who smoke or have smoked previously should also schedule a physical exam and abdominal USG to screen for abdominal aortic aneurysm.¹⁰ According to the Canadian Society for Vascular Surgery, screening for women older than 65 years of age is unnecessary on a population basis, but rather should be individualized to patients with multiple risk factors.¹¹ There are a wide range of management strategies for abdominal aortic aneurysm including cessation of smoking, β -Blockers, and various forms of surgical intervention.⁵

Surgical management of abdominal aortic aneurysm is generally through endovascular or open surgical repair. Endovascular aneurysm repair (EVAR) was first reported in 1991 by Juan Parodi and marked the shift to minimally invasive abdominal aortic aneurysm repair from open surgical repair.¹² EVAR involves insertion of an endograft into the

Figure 2. Sagittal CT angiogram of abdomen demonstrating mechanical fragmentation and displacement of stent.



lumen of the aorta, which essentially reroutes blood flow and effectively excludes an aneurysm from further expansion. The procedure is less expensive and invasive than open repair, and short-term success rate ranges from 83% to 95%.^{13,14} Other benefits include reduced blood loss and shorter hospital stay due to quicker recovery time. For these reasons, the ACC/AHA recommends endovascular repair for abdominal aortic aneurysm in patients who are at high risk for complications or may not tolerate open repair.¹⁰ From 1991 to 2006, there were 21,725 EVAR cases in the United States, exceeding the number of open repairs. Furthermore, since 2006, approximately 70% of elective abdominal aortic aneurysm repairs in the United States have been completed by EVAR.¹⁵ However, this therapeutic strategy is not unassailable, as certain complications are relatively common post-stent deployment. EVAR is complicated by endoleak in approximately 20% to 25% of patients.^{16,17} There are five different types of endoleak, each classified by the source that causes blood flow into the aneurysm sac. Type I endoleak is found at the proximal or distal attachment sites of the stent graft, whereas Type II endoleak is caused by retrograde flow through collateral vessels. As seen in the case above, Type III endoleak is caused by holes, separations, or mechanical defects in the stent graft. Type IV endoleak is caused by porous graft walls and Type V endoleak is attributed to endotension by an enlarging aneurysm sac.¹⁸ Other major complications that have been reported during stent placement include vascular injury during deployment, inadequate attachment of

the graft to the vessel wall, stent frame fractures, and degradation of graft material.¹⁹ Along with endoleaks, long-term complications of endovascular repair range from graft migration/kinking and spontaneous thrombosis to risk of re-intervention due to aneurysm rupture.^{20,21} In a study following 625 patients, the major complications of EVAR comprised proximal migration (n = 60; 9.7%), and progressive kinking (n = 59; 9.6%) of the stent graft. Late Type III endoleak (n = 12; 1.9%) was noted as a relatively rare complication of endovascular repair.²² Secondary management strategies for complications post EVAR include, transabdominal surgery (with or without preservation of the endograft), extra anatomic bypass, or transfemoral endovascular re-intervention.²⁰

Conclusion

Acute abdominal aortic aneurysm rupture is a clinical emergency and must be managed in a timely manner to prevent patient mortality. Diagnosis is difficult as the majority of abdominal aortic aneurysms are asymptomatic until rupture. A variety of risk factors including age, sex, and smoking habits increase the risk for abdominal aortic aneurysm.⁵ Patients who are at high risk should be screened using abdominal USG.^{8,9} Surgical intervention for abdominal aortic aneurysm is generally completed by EVAR or open surgical repair. Although EVAR does offer certain advantages over open surgery, there are a number of possible complications including endoleak.^{16,17} Secondary management strategies following endoleak include transabdominal surgery, extra anatomic bypass, or transfemoral endovascular reintervention.²⁰

Declarations

Competing interests: None declared

Funding: None declared

Guarantor: SRS

Ethical approval: Written informed consent for publication was obtained from the patient.

Contributorship: The case report was reviewed, drafted, and edited by SS and ZS. SRS was responsible for providing overall guidance at each stage of the process, as well as editing and providing feedback to better improve the manuscript with each draft.

Acknowledgement: None

Provenance: Not commissioned; peer-reviewed by Ramar Kannan

References

1. Singh K, Bonna KH, Jacobsen BK, Bjork L and Solberg S. Prevalence of and risk factors for abdominal aortic

- aneurysms in a population-based study: the Tromso Study. *Am J Epidemiol* 2001; 154: 236–244.
2. Powell JT and Greenhalgh RM. Clinical practice. Small abdominal aortic aneurysms. *N Engl J Med* 2003; 348: 1895–1901.
 3. Scott RA, Wilson NM, Ashton HA and Kay DN. Influence of screening on the incidence of ruptured abdominal aortic aneurysm: 5-year results of a randomized controlled study. *Br J Surg* 1995; 82: 1066–1070.
 4. Lederle FA, Johnson GR and Wilson SE. Abdominal aortic aneurysm in women. *J Vasc Surg* 2001; 34: 122–126.
 5. Aggarwal S, Qamar A, Sharma V and Sharma A. Abdominal aortic aneurysm: a comprehensive review. *Exp Clin Cardiol* 2011; 16: 11–15.
 6. Schermerhorn M. A 66-year-old man with an abdominal aortic aneurysm: review of screening and treatment. *JAMA* 2009; 302: 2015–2022.
 7. Harris LM, Faggioli GL, Fiedler R, Curl GR and Ricotta JJ. Ruptured abdominal aortic aneurysms: factors affecting mortality rates. *J Vasc Surg* 1991; 14: 812–818; discussion 9–20.
 8. LaRoy LL, Cormier PJ, Matalon TA, Patel SK, Turner DA and Silver B. Imaging of abdominal aortic aneurysms. *AJR* 1989; 152: 785–792.
 9. Screening for abdominal aortic aneurysm: recommendation statement. *Ann Int Med* 2005; 142: 198–202.
 10. Hirsch AT, Haskal ZJ, Hertzner NR, Bakal CW, Creager MA, Halperin JL, et al. ACC/AHA Guidelines for the Management of Patients with Peripheral Arterial Disease (lower extremity, renal, mesenteric, and abdominal aortic): a collaborative report from the American Associations for Vascular Surgery/Society for Vascular Surgery, Society for Cardiovascular Angiography and Interventions, Society for Vascular Medicine and Biology, Society of Interventional Radiology, and the ACC/AHA Task Force on Practice Guidelines (writing committee to develop guidelines for the management of patients with peripheral arterial disease) – summary of recommendations. *JVIR* 2006; 17: 1383–1397; quiz 98.
 11. Mastracci TM and Cina CS. Screening for abdominal aortic aneurysm in Canada: review and position statement of the Canadian Society for Vascular Surgery. *J Vasc Surg* 2007; 45: 1268–1276.
 12. Parodi JC, Palmaz JC and Barone HD. Transfemoral intraluminal graft implantation for abdominal aortic aneurysms. *Ann Vasc Surg* 1991; 5: 491–499.
 13. Criado FJ, Wilson EP, Fairman RM, Abul-Khoudoud O and Wellons E. Update on the talent aortic stent-graft: a preliminary report from United States phase I and II trials. *J Vasc Surg* 2001; 33: S146–S149.
 14. Elkouri S, Gloviczki P, McKusick MA, Panneton JM, Andrews JC, Bower TC, et al. Endovascular repair of abdominal aortic aneurysms: initial experience with 100 consecutive patients. *Mayo Clin Proc* 2003; 78: 1234–1242.
 15. Schwarze ML, Shen Y, Hemmerich J and Dale W. Age-related trends in utilization and outcome of open and endovascular repair for abdominal aortic aneurysm in the United States, 2001–2006. *J Vasc Surg* 2009; 50: 722–729.e2.
 16. Hellinger JC. Endovascular repair of thoracic and abdominal aortic aneurysms: pre- and postprocedural imaging. *Tech Vasc Interv Radiol* 2005; 8: 2–15.
 17. Veith FJ, Baum RA, Ohki T, et al. Nature and significance of endoleaks and endotension: summary of opinions expressed at an international conference. *J Vasc Surg* 2002; 35: 1029–1035.
 18. Rosen RJ and Green RM. Endoleak management following endovascular aneurysm repair. *JVIR* 2008; 19: S37–S43.
 19. Hallett JW, Jr., Marshall DM, Petterson TM, et al. Graft-related complications after abdominal aortic aneurysm repair: reassurance from a 36-year population-based experience. *J Vasc Surg* 1997; 25: 277–284; discussion 85–86.
 20. Laheij RJ, Buth J, Harris PL, Moll FL, Stelter WJ and Verhoeven EL. Need for secondary interventions after endovascular repair of abdominal aortic aneurysms. Intermediate-term follow-up results of a European collaborative registry (EUROSTAR). *Br J Surg* 2000; 87: 1666–1673.
 21. Blankensteijn JD, de Jong SE, Prinssen M, van der Ham AC, Buth J, van Sterkenburg SM, et al. Two-year outcomes after conventional or endovascular repair of abdominal aortic aneurysms. *N Engl J Med* 2005; 352: 2398–2405.
 22. Pitoulias GA, Schulte S, Donas KP and Horsch S. Secondary endovascular and conversion procedures for failed endovascular abdominal aortic aneurysm repair: can we still be optimistic? *Vascular* 2009; 17: 15–22.