



Case report

Variations in West Nile Virus neuroinvasive infection: A case series of three patients in West Phoenix



Aniket Mody^a, Monider Singh^a, Chandra D. Chhetri^b, Michael Castro^a,
Perminder Sanghera^{a,*}

^a Department of Internal Medicine, Abrazo Arrowhead Hospital, Glendale, AZ 85308, United States

^b Arizona College of Osteopathic Medicine, Midwestern University, Glendale, AZ 85308, United States

ARTICLE INFO

Article history:

Received 7 December 2020

Received in revised form 27 January 2021

Accepted 9 March 2021

Keywords:

West Nile Virus

Cerebrospinal fluid analysis

Encephalopathy

Meningitis

Viral meningitis

Sepsis

ABSTRACT

West Nile Virus (WNV) is the most common mosquito-borne virus in the United States and North America. Although WNV disease occurs on a spectrum ranging from a relatively benign febrile illness to life-threatening neuroinvasive disease, the clinical presentations can vary widely and thus necessitates a high degree of suspicion. Here we describe three such cases where each individual presented with a unique constellation of symptoms that made the diagnosis challenging. It is essential for physicians to be well informed on the differing symptomatology so early diagnosis and supportive management can mitigate poor prognosis.

© 2021 The Authors. Published by Elsevier Ltd. This is an open access article under the CC BY-NC-ND license (<http://creativecommons.org/licenses/by-nc-nd/4.0/>).

Introduction

The West Nile Virus is a flavivirus in the family of Flaviviridae. These viruses enter host cells through clathrin-mediated endocytosis and release their genetic material from the endosome into the cytosol after acidification mediated membrane fusion [1]. The WNV genome is comprised of an ~11 kb long, single-stranded, positive sense RNA genome that encodes a single open reading frame. By exploiting host machinery, the viral RNA is translated as a polyprotein which is then cleaved into ten functional proteins by both cellular and viral proteases – three are structural proteins (capsid, pre-membrane, and envelope) and seven are non-structural proteins [2]. Recent studies have shown that additional proteins may also be produced via different mechanisms including ribosomal frameshifting [3]. WNV induces lysis by promoting apoptosis in a variety of cell types including neurons. In humans, infections can be asymptomatic or lead to severe neuroinvasive illness. Although there have been significant research efforts dedicated to WNV pathophysiology, there are still no approved vaccines or antivirals available for human use, and supportive care for clinical management remains the gold standard.

Epidemiology

WNV transmission is perpetuated in a cycle between *Culex* mosquitoes, the primary vector, and various birds, the principal reservoir hosts. Other vertebrates, including humans and horses, can be infected with the virus through bite of an infected mosquito but are considered to be “dead-end hosts” because infection does not produce a lasting viremia to re-infect biting mosquitoes. The Center for Disease Control and Prevention (CDC) states that most people infected with WNV (80 %) are asymptomatic, and about 20 % of those infected develop a transient febrile illness with symptoms including headaches, myalgias, arthralgias, vomiting, and diarrhea. In 1999, WNV was introduced in North America after an outbreak occurred in New York, and within three years had made its way to most of the continental US and surrounding countries in North America [4,5]. WNV has spread across to six of seven continents, including Africa, Asia, Europe, Australia, North America and South America, and is today considered to be one of the most prominent causative pathogens of viral encephalitis worldwide [5]. Since 1999, the virus has been estimated to cause more than 6 million infections, producing over 24,000 cases of neurological disease and 2300 deaths in the US [5]. These numbers support the urgency required to better understand the pathogenesis of WNV and develop treatments.

* Corresponding author.

E-mail address: permindersanghera@yahoo.com (P. Sanghera).

Pathophysiology

The mechanisms by which WNV enters the CNS are still not well understood, although there have been many proposed explanations. Current literature suggests multiple potential pathways by which WNV gains entry, including direct entry through the blood-brain-barrier (BBB) tight junctions, infection of endothelial cells, infection of olfactory neurons, infected leukocytes that “carry” WNV to the CNS, and axonal retrograde transport from the infected periphery (Fig. 1).

WNV replication in the periphery leads to viremia in blood which may promote CNS entry, after which the patient can experience a host of complications including meningitis, encephalitis, and acute flaccid paralysis (WNV poliomyelitis). One possible way by which this may occur is through the expression of inflammatory cytokines including TNF- α , MIF, MMP9, ICAM-1 and Opn, which through direct or indirect means may increase permeability of the BBB [6]. Another plausible entry is through direct infection of endothelial cells in cerebral vasculature, following which viral progeny are released in the CNS. WNV may also enter through olfactory bulbs [7] and infected neurons of the nasal pathway, or through lymphocyte-infected transport [8–11] to the CNS. It may also be carried through infected peripheral nerves. Once inside, the viral progeny induces a proinflammatory state that leads to production of multiple cytokines, promoting cell apoptosis and necrosis [12,13]. Some of these molecules may remain persistently elevated, causing post-infectious sequelae and autoimmune phenomena such as Myasthenia Gravis [14,15].

Treatment and management

There currently exists four licensed WNV vaccines in the veterinary world, yet there are still no approved vaccines or antivirals available for human use. Despite the many challenges in creating a vaccine, clinical research has supplied ample evidence that administration of high dose intravenous (IV) steroids may yield significant clinical improvement in patients who suffer marked neuroinvasive disease. Experimental studies conducted have shown that pro-inflammatory molecules may be a principal contributing factor to viral pathogenesis in the CNS [16]. Treatment of infected neurons with antibodies blocking these cytokines resulted in profound reduction of neuronal death in vitro [16,17]. There is also a growing body of evidence that a prolonged post-infectious state may promote lasting neurological deficits and autoimmune disorders, and strategies to mitigate this inflammatory cascade may be beneficial.

In a trial of 14 patients with acute WNV meningoencephalitis, IV dexamethasone was implicated to play a crucial role in reducing the duration of disease and prompting an increased rate of recovery [18]. Another report describes the turnaround in patient symptoms of two patients with acute flaccid paralysis and CN VII palsies, who within 24 h of treatment with high-dose IV methylprednisolone rapidly improved [19]. Though it may seem that steroids, with the potent immunosuppressive effects they exert, may promote viremia and worsen outcome, there is compelling evidence that they ought to be used in WNV neuroinvasive disease [20]. These accounts indicate the necessity in conducting large-scale clinical trials to definitively confirm the

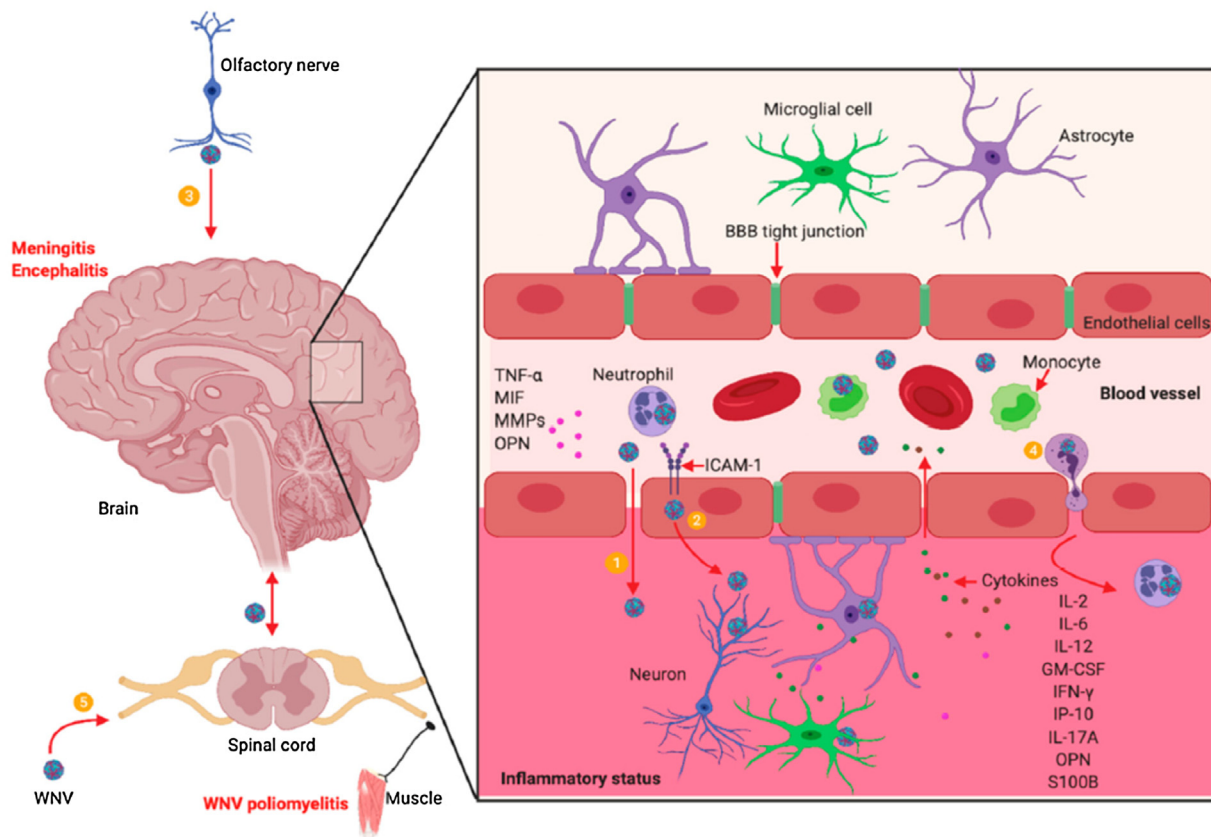


Fig. 1. Five possible mechanisms for WNV neuroinvasion and pathogenesis [21].

therapeutic benefits of corticosteroids in the context of WNV illness.

Case presentation

Case 1 is a 69-year-old male who presented in July 2019 with a past medical history of enlarged prostate status post TURP (transurethral resection of the prostate), left knee replacement, and alcohol use who was brought to the emergency room for confusion and altered speech. He was unable to respond appropriately to questions. However, he was able to obey commands. His wife said that his symptoms began 2 days ago. He did not have nausea, vomiting, fever, and chills. Vitals were significant for tachypnea. On physical exam the patient had left sided hemiparesis. Labs on admission were significant for leukocytosis, elevated creatine, elevated transaminases, lactic acidosis, and elevated creatine kinase. CT head and MRI brain did not show any intracranial abnormality or stroke. An EEG was significant for moderate encephalopathy. He was started on rocephin and vancomycin and placed on a BiPAP. Blood cultures remained negative. A lumbar puncture yielded the following: WBC 28 (0–5), PMN 11 %, lymphocytes 45 %, monocytes 44 %, protein 114 (15–45), and glucose 85 (45–70). He was empirically started on antibiotics including meropenem, linezolid, fluconazole, and acyclovir. CSF HSV and cocci serology were negative and acyclovir and fluconazole was discontinued. CSF bacterial culture was negative. Serum and CSF serologies were positive for West Nile Virus IgG and IgM. At this point all antibiotics were discontinued. The patient remained encephalopathic and a trial of steroids were administered with no benefit. The patient received a tracheostomy and gastrostomy tube with tube feeding and transferred to a long-term acute care facility.

Case 2 is a 76-year-old male who presented in May 2019 with a past medical history of glaucoma who arrived to the hospital with a fever of 104 °F. According to the patient's wife he has had a fever for a week. In addition, the patient was experiencing nausea, shaking, incontinence, confusion, and weakness. He did not have headache, neck stiffness, abdominal pain, chest pain, and SOB. His wife stated that there are numerous mosquitoes where they live and he has been bitten multiple times. In addition, they had been recently been to a wedding where multiple guests at the wedding also became sick. Vitals were significant for bradycardia, hypotension, and fever. Labs were significant for leukocytosis and elevated creatine kinase. The patient was started on zosyn, rocephin, and vancomycin in addition to dopamine and IV fluids. It was thought his bradycardia might be secondary to increased intracranial pressure due to encephalitis. CT head and MRI brain did not show any intracranial abnormality. CSF analysis showed WBC of 55 (0–5) with 58 % PMN, 25 % lymphocytes, 17 % monocytes, protein 96 (14–55), and glucose 62 (45–70). At this point his antibiotics were switched to vancomycin, ceftriaxone, ampicillin, and acyclovir. The patient continued with severe shaking and was intubated and sedated. EEG was obtained and did not show evidence of subclinical seizures. His West Nile Virus IgM CSF was positive. At this point antibiotics and acyclovir was discontinued. The patient was extubated and his mental status slowly improved over the course of the next few days. He was discharged to acute rehab.

Case 3 is a 77-year-old male who presented in July 2019 with a history of myoclonic seizures with VNS (vagus nerve stimulator) implant, coronary artery disease status post CABG, and transient ischemic attack. He had reported fevers, chills, and headache for one day. His temperature taken at home was 101 °F. He admitted to experiencing hallucinations, vision problems, nausea, dry heaves, neck stiffness, and shortness of breath. He has never had these constellation of symptoms before. He denied hemiparesis. Vitals were significant for fever to 104 °F, tachypnea, and elevated blood

pressure. On physical exam the patient had pain when his neck was flexed. The patient did not present with leukocytosis. CT head and MRI Brain did not show any intracranial abnormality. Lumbar puncture and CSF analysis revealed WBC 1166 (0–5), PMN 85 %, Lymphocyte 10 %, and Monocyte 5%, protein 115 (14–55), glucose 116 (45–70). He was started on ceftriaxone, vancomycin, ampicillin, and dexamethasone. The patient's encephalopathy continued to worsen and he was started on acyclovir. Because of the patient's seizure history lamictal was continued, VNS implant was interrogated, and an EEG was obtained. The EEG showed bilateral global cerebral dysfunction with no evidence of seizures. Cocci and HSV serologies were negative. Serum was positive for West Nile virus IgM and CSF serologies were positive for West Nile Virus IgG and IgM. Antibiotics and acyclovir were discontinued. The patient's headache, encephalopathy, and neck stiffness improved with supportive care over the next 2 weeks. He was discharged to a skilled nursing facility.

Discussion

The clinical manifestations of WNV infection are wide-ranging, symptoms occur in about 20–40 % of infected patients, and risk factors for developing persistent neurologic sequelae include advancing age, malignancy, organ transplantation, and immunosuppression [5]. The most dreaded complication is the polio-like paralysis syndrome, which is a concern because Maricopa County in Arizona is one of several counties nationwide experiencing one of the highest WNV burdens on record. CDC reports that 1/3 fully recover to baseline, while 10 % of patients who develop severe illness have increased mortality.

Although our cases of WNV at Abrazo Community Health Network were infected at a predictable time in a WNV hotspot, their symptoms did not resemble the classic triad of fever, headache, and neck stiffness present in 44 % of patients. Despite the patients presenting with diverse symptomology, one common factor in the course of their illnesses was that every patient demonstrated nonspecific neurological symptoms and signs of sepsis.

As per meningitis protocol based on their presenting symptoms, droplet precautions were initiated for risk of bacterial meningitis and patients were assessed for risk of cerebral herniation including CT imaging before CSF was drawn to determine the cause of the illness. Overall, WNV meningitis accounts for a very small (<1.1 %) portion of all viral meningitis, but the high prevalence in the state of Arizona, combined with its varying clinical presentations, makes it a cause for concern.

Though out patients had different presentations, they all carried a common thread of nonspecific neurological findings and sepsis, illustrating the importance for physicians to be well informed and to maintain a high index of suspicion. Future studies are needed to analyze the benefit of early lumbar puncture in these patients, especially in places with a high incidence of WNV such as Arizona.

Author statement

All authors provided critical feedback and helped shape the research, analysis and manuscript.

Aniket Mody: conceived and designed the analysis; collected the data; performed analysis, and wrote the paper

Monider Singh: conceived and designed the analysis; collected the data; and performed analysis

Chandra D. Chhetri: conceived and designed the analysis; collected the data; performed analysis, and wrote the paper

Michael Castro: Other Contribution- supervised the project

Perminder Sanghera: Other Contribution- supervised the project

Conflicts of interest

None.

Sources of funding

None.

Ethical approval

None.

Consent

All 3 patients in this case series has consented for there information to be used in this publication

References

- [1] Hackett BA, Cherry S. Flavivirus internalization is regulated by a size-dependent endocytic pathway. *Proc Natl Acad Sci U S A* 2018;115:4246–51.
- [2] Mazeaud C, Freppel W, Chatel-Chaix L. The multiple fates of the flavivirus RNA genome during pathogenesis. *Front Genet* 2018;9:595.
- [3] EFirth A, Atkins JF. A conserved predicted pseudoknot in the NS2A-encoding sequence of West Nile and Japanese encephalitis flaviviruses suggests NS1' may derive from ribosomal frameshifting. *Virology* 2009;6:14.
- [4] Mostashari F, Fine A, O'Leary D, Huang A, Sherman M, Wong S, et al. The outbreak of west nile virus infection in the New York City Area in 1999. *N Engl J Med* 2001;344:1807–14.
- [5] Chancey C, Grinev A, Volkova E, Rios M. The global ecology and epidemiology of west nile virus. *Biomed Res Int* 2015;2015:1–20.
- [6] Wang T, Town T, Alexopoulou L, Anderson JF, Fikrig E, Flavell RA. Toll-like receptor 3 mediates West Nile virus entry into the brain causing lethal encephalitis. *Nat Med* 2004;10:1366–73.
- [7] Brown AN, Kent KA, Bennett CJ, Bernard KA. Tissue tropism and neuroinvasion of West Nile virus do not differ for two mouse strains with different survival rates. *Virology* 2007;368:422–30.
- [8] Wang S, Welte T, McGargill M, Town T, Thompson J, Anderson JF, et al. Drak2 contributes to West Nile virus entry into the brain and lethal encephalitis. *J Immunol* 2008;181:2084–91.
- [9] Cardosa MJ. Complement receptor mediates enhanced flavivirus replication in macrophages. *J Exp Med* 1983;158:258–63.
- [10] Samuel MA, Diamond MS. Pathogenesis of West Nile virus infection: a balance between virulence, innate and adaptive immunity, and viral evasion. *J Virol* 2006;80:9349–60.
- [11] Paul AM, Acharya D, Duty L, Thompson EA, Le L, Stokic DS, et al. Osteopontin facilitates West Nile virus neuroinvasion via neutrophil "Trojan horse" transport. *Sci Rep* 2017;7:4722.
- [12] Yang J-S, Ramanathan MP, Muthumani K, Choo AY, Jin S-H, Yu Q-C, et al. Induction of inflammation by West Nile virus capsid through the Caspase-9 apoptotic pathway. *Emerg Infect Dis* 2002;8:1379–84.
- [13] Parquet MDC, Kumatori A, Hasebe F, Morita K, Igarashi A. West Nile virus-induced bax-dependent apoptosis. *FEBS Lett* 2001;500:17–24.
- [14] Leis AA, Szatmary G, Ross MA, Stokic DS. West nile virus infection and myasthenia gravis. *Muscle Nerve* 2013;49:26–9.
- [15] Hawkes MA, Hocker SE, Leis AA. West Nile virus induces a post-infectious pro-inflammatory state that explains transformation of stable ocular myasthenia gravis to myasthenic crises. *J Neurol Sci* 2018;395:1–3.
- [16] Kumar M, Verma S, Nerurkar VR. Pro-inflammatory cytokines derived from West Nile virus (WNV)-infected SK-N-SH cells mediate neuroinflammatory markers and neuronal death. *J Neuroinflamm* 2010;7:73.
- [17] Verma S, Kumar M, Nerurkar VR. Cyclooxygenase-2 inhibitor blocks production of West Nile Virus-induced neuroinflammatory markers in astrocytes. *J Gen Virol* 2011;92:507–15.
- [18] Narayanaswami PEL, Hyde C, Page C, Hastings NE. West Nile meningitis/encephalitis: experience with corticosteroid therapy. *Neurology* 2004;62:A404.
- [19] Leis AA, Stokic DS. Neuromuscular manifestations of West Nile virus infection. *Front Neurol* 2012;3:37.
- [20] Huang C, Slater B, Rudd R, Parchuri N, Hull R, Dupuis M, et al. First isolation of West Nile virus from a patient with encephalitis in the United States. *Emerg Infect Dis* 2002;8:1367–71.
- [21] Bai F, Thompson EA, Vig PJS, Leis AA. Current understanding of West Nile virus clinical manifestations, immune responses, neuroinvasion, and immunotherapeutic implications. *Pathogens* 2019.