






Risk factors for poor hemostasis of prophylactic uterine artery embolization before curettage in cesarean scar pregnancy

Hongan Tian^{1,2} , Shunzhen Li¹ ,
Wanwan Jia¹ , Kaihu Yu¹  and
Guangyao Wu² 

Abstract

Objective: To observe the hemostatic effect of prophylactic uterine artery embolization (UAE) in patients with cesarean scar pregnancy (CSP) and to examine the risk factors for poor hemostasis.

Methods: Clinical data of 841 patients with CSP who underwent prophylactic UAE and curettage were retrospectively analyzed to evaluate the hemorrhage volume during curettage. A hemorrhage volume ≥ 200 mL was termed as poor hemostasis. The risk factors of poor hemostasis were analyzed and complications within 60 days postoperation were recorded.

Results: Among the 841 patients, 6.30% (53/841) had poor postoperative hemostasis. The independent risk factors of poor hemostasis were gestational sac size, parity, embolic agent diameter ($> 1000 \mu\text{m}$), multivessel blood supply, and incomplete embolization. The main postoperative complications within 60 days after UAE were abdominal pain, low fever, nausea and vomiting, and buttock pain, with incidence rates of 71.22% (599/841), 47.44% (399/841), 39.12% (329/841), and 36.39% (306/841), respectively.

Conclusions: Prophylactic UAE before curettage in patients with CSP is safe and effective in reducing intraoperative hemorrhage. Gestational sac size, parity, embolic agent diameter, multivessel blood supply, and incomplete embolization of all arteries supplying blood to the uterus are risk factors of poor hemostasis.

¹Department of Radiology, Xianning Central Hospital, The First Affiliated Hospital of Hubei University of Science and Technology, Xianning, P.R. China

²Department of Radiology, Zhongnan Hospital of Wuhan University, Wuhan, P.R. China

Corresponding author:

Guangyao Wu, Department of Radiology, Zhongnan Hospital of Wuhan University, No. 169 East Lake Road, Wuchang District, Wuhan 430071, P.R. China.
Email: wuguangyao2002@126.com



Keywords

Ectopic pregnancy, uterine artery, embolization, multivessel, hemorrhage, cesarean section

Date received: 1 April 2020; accepted: 14 September 2020

Introduction

Cesarean scar pregnancy (CSP) is a type of ectopic pregnancy that refers to implantation of the gestational sac in a uterine scar after cesarean section.¹ The prevalence of CSP in a scarred uterus is 1/531, accounting for 4.2% of ectopic pregnancies.² For the past few years, the incidence of CSP has gradually increased with an elevation of the cesarean section rate. CSP is rich in blood supply and thin in the muscular layer.³ Traditional curettage can easily lead to massive hemorrhage, resulting in a relatively difficult clinical treatment.⁴

Uterine artery embolization (UAE) is widely applied in the clinic for its safety, minimal trauma, and few complications. UAE has also achieved remarkable curative effects in treating acute uterine hemorrhage, uterine leiomyoma, cervical cancer, and other diseases.⁵ Prophylactic UAE before CSP curettage can significantly reduce the hemorrhage volume during curettage by blocking the blood supply of bilateral uterine arteries and it is widely used.^{6,7} However, with an increase of treated patients, some patients still have poor hemostasis, and even experience massive hemorrhage during curettage that threatens life. Therefore, identifying the causes and risk factors of poor hemostasis of UAE is particularly important. Previous studies considered that the external iliac artery supply is an important factor for hemostasis of UAE, but most of them were case reports and lacked statistical power from a large dataset.^{8,9} There have also been few studies on the risk factors of hemostasis of UAE,¹⁰ especially from the perspective of interventional surgery. In this study, we

aimed to determine hemostasis of prophylactic UAE in treating CSP before curettage, examine the risk factors of poor hemostasis, and summarize related complications, thus providing a reference for clinical decision-making.

Materials and methods

General information

Clinical data of 1057 patients with CSP who underwent prophylactic UAE and curettage in Xianning Central Hospital from January 2013 to December 2018 were retrospectively analyzed. Xianning Central Hospital is a comprehensive top third-grade hospital in Xianning City, Hubei Province, China, and it treats a large number of CSP patients every year. The present retrospective study was approved by the Institutional Review Board of Xianning Central Hospital (Xianning, China). Verbal consent was obtained for the telephone interviews performed in the present study.

Inclusion criteria were as follows: (1) diagnosis of CSP by ultrasound; (2) adherence to the definition of time limit agreed by experts on diagnosis and treatment of CSP after cesarean section (2016), and gestational of ≤ 12 weeks.¹¹ Exclusion criteria were as follows: (1) incomplete clinical and follow-up data; (2) with contraindications for interventional embolization; and (3) emergency UAE was performed for non-CSP massive hemorrhage.

Instruments and methods

The Philips Allura Xper FD20 instrument (Philips, Eindhoven, The Netherlands) for

digital subtraction angiography was used. The contrast used was ioversol injection (320 mg I/mL). Gelfoam particles were used as the embolic agent (Alicon Corporation, Hangzhou, China), with a diameter in the range of 350 to 1400 μm . Prophylactic UAE was performed by two interventional specialists (attending physician with 1 decade of working experience and a deputy chief physician with two decades of working experience). Conventional bilateral internal iliac artery angiography was carried out after puncture and catheter insertion of the femoral artery. After finding the opening of the uterine artery, the catheter was superselectively inserted into the uterine artery and embolized with gelfoam particles (a few patients were perfused with methotrexate 50 mg). In uterine arteriography, the pressure of a high-pressure syringe was set at 150 psi, the flow rate was 4 mL/s, and the total volume was 8 mL. All arteries that supplied blood to the uterus were then found and embolized by internal iliac artery and external iliac artery angiography. Incomplete embolization was defined as when all branches of the uterine blood supply found by angiography could not be embolized owing to technical or other reasons, or angiography still displayed blood vessels after embolization. Multivessel blood supply was defined as the presence of blood vessels that supply blood to the uterus in addition to the bilateral uterine arteries. Obstetricians or gynecologists completed curettage within 48 to 72 hours after UAE.

Observed indicators

Attending physicians with more than 5 years of experience in curettage evaluated the amount of intraoperative hemorrhage. A hemorrhage volume ≥ 200 mL was classified as poor hemostasis and a hemorrhage volume > 500 mL as massive hemorrhage. We recorded ultrasonic CSP typing

(typing standard in the *Expert Consensus on Diagnosis and Treatment of Uterine Scar Pregnancy after Cesarean Section [2016]* of the Family Planning Group of the Obstetrics and Gynecology Credit Association of the Chinese Medical Association),¹¹ human chorionic gonadotropin levels, gestational sac size (maximum diameter), embolic agent diameter, whether multiple blood vessels were found in intraoperative angiography, whether all blood vessels were completely embolized, and other indicators. We also analyzed the risk factors of poor hemostasis.

The incidence of complications, such as postoperative syndrome (e.g., nausea, vomiting, pain, low fever), ectopic embolism (e.g., skin ulcer, ovarian necrosis, lower limb artery ischemia), deep vein thrombosis, and allergic reactions, within 60 days after UAE were analyzed.

Statistical analysis

Statistical analysis was performed by using IBM SPSS Statistics for Windows version 25.0 (IBM Corp., Armonk, NY, USA). All raw data were assessed for normality using the Kolmogorov–Smirnov test. Data that conformed to a normal distribution are expressed as mean \pm standard deviation and those that were not normally distributed are shown as the median (minimum, maximum). Between-group comparisons were carried out with the chi-square test, Student's *t*-test, or Mann–Whitney U test. Multivariate logistic regression analysis was used to estimate odds ratios and 95% confidence intervals for potential risk factors. $P < 0.05$ was considered statistically significant.

Results

Clinical characteristics of the patients

After applying the inclusion and exclusion criteria, we included 841 patients in the

study. The median age was 32 years (19–48 years). Other detailed information of the patients is shown in Table 1.

Hemostatic effect and risk factors

The median hemorrhage volume was 40 mL (20–1200 mL) in patients after UAE. The hemorrhage volume ranged from 20 to 50 mL in 601 (71.46%) patients, 50 to 200 mL in 187 (22.23%) patients, 200 to 500 mL in 41 (4.88%) patients, and 500 to 1200 mL in 12 (1.43%) patients. Of the 841 patients, only 6.30% (53/841) had poor postoperative hemostasis. Age, human chorionic gonadotropin levels, the pregnancy period, and gravidity were not significantly different between the group of patients who had satisfactory hemostasis and those who had poor hemostasis. However, gestational sac size was significantly higher ($P < 0.001$) and embolic agent diameter ($P = 0.013$) was significantly lower in the poor hemostasis group than in the satisfactory hemostasis group. A significantly lower rate of patients did not have multivessel blood supply and had incomplete embolization in the poor hemostasis group than in the satisfactory hemostasis group (both $P < 0.001$). Ultrasonic CSP typing and parity were also significantly different between the groups (both $P < 0.05$, Table 1).

Univariate analysis showed that gestational sac size, parity, embolic agent diameter ($>1000 \mu\text{m}$), multivessel blood supply, incomplete embolization, and ultrasonic CSP typing were significantly related to poor hemostasis (all $P < 0.05$). Multivariate regression analysis showed that gestational sac size, parity, embolic agent diameter ($>1000 \mu\text{m}$), multivessel blood supply, and incomplete embolization were significant independent risk factors for poor hemostasis (all $P < 0.05$, Table 2).

Complications

The main postoperative complications within 60 days after UAE were abdominal pain, low fever, nausea and vomiting, and buttock pain, with incidence rates of 71.22% (599/841), 47.44% (399/841), 39.12% (329/841), and 36.39% (306/841), respectively (Figure 1). Urinary system symptoms, such as hematuria and urinary tract obstruction, were present in eight patients, mild to moderate allergic reaction of contrast agent in four patients, deep venous thrombosis of the lower limbs in two patients, and ovarian necrosis in one patient (Figure 2).

Multivariate regression analysis was carried out on the complications of lower abdominal pain and low fever. We found that the diameter of the embolic agent was an independent risk factor for lower abdominal pain and low fever (all $P < 0.01$, Table 3).

Discussion

In this study, a large sample size was retrospectively analyzed for CSP treated by UAE and curettage. We found that prophylactic UAE was safe and effective for patients with CSP before curettage, and only 6.30% of patients had postoperative blood loss $> 200 \text{ mL}$. The main risk factors for poor hemostasis were gestational sac size, parity, embolic agent diameter ($>1000 \mu\text{m}$), multivessel blood supply, and incomplete embolization.

CSP can easily lead to uterine rupture, hemorrhage, and even death of patients.^{12,13} At present, there are many ways to treat CSP. In 2016, the Obstetrics and Gynecology Branch of the Chinese Medical Association published the *Expert Consensus on Diagnosis and Treatment of Uterine Scar Pregnancy after Cesarean Section*, which determined the role of prophylactic UAE in treatment for CSP,

Table 1. General information of patients and comparison between the satisfactory and poor hemostasis groups.

Clinical data	Group		Statistical value (t or χ^2)	P value
	Overall	Satisfactory Hemostasis group		
Number	841	788	53	
Age (years)	31.52 ± 7.25	31.51 ± 7.25	31.70 ± 7.30	0.857*
Pregnancy period (days)	52.64 ± 8.65	52.58 ± 8.57	53.53 ± 9.85	0.438*
HCG (IU/L)	46213.35 ± 22381.79	46298.89 ± 22412.66	45032.74 ± 21220.13	0.689*
Gestational sac size (cm)	4.58 ± 2.14	4.49 ± 2.08	5.93 ± 2.56	<0.001*
Embolic agent diameter (μm), n (%)				0.013
350–560	119 (14.15)	115 (14.59)	4 (7.55)	
560–710	231 (27.47)	224 (28.43)	7 (13.21)	
710–1000	282 (33.53)	260 (32.99)	22 (41.51)	
1000–1400	209 (24.85)	189 (23.98)	20 (37.74)	
Multivessel blood supply, n (%)				<0.001
No	796 (94.65)	770 (97.72)	26 (49.06)	
Yes	45 (5.35)	18 (2.28)	27 (50.94)	
Incomplete embolization, n (%)				<0.001
No	818 (97.27)	785 (99.62)	33 (62.26)	
Yes	23 (2.73)	3 (0.38)	20 (37.74)	
CSP typing, n (%)				<0.001
Type I	145 (17.24)	136 (17.26)	9 (16.98)	
Type II	493 (58.62)	477 (60.53)	16 (30.19)	
Type III	203 (24.14)	175 (22.21)	28 (52.83)	
Parity, n (%)				0.027
1	480 (57.07)	456 (57.87)	24 (45.28)	
2	353 (41.97)	326 (41.37)	27 (50.94)	
3	8 (0.95)	6 (0.76)	2 (3.77)	
Gravidity, n (%)				0.859
2	307 (36.50)	284 (36.04)	23 (43.40)	
3	252 (29.96)	239 (30.33)	13 (24.53)	

(continued)

Table 1. Continued.

Clinical data	Group			Statistical value (t or χ^2)	P value
	Overall	Satisfactory Hemostasis group	Poor hemostasis group		
4	254 (30.20)	238 (30.20)	16 (30.19)		
5	11 (1.31)	11 (1.40)	0 (0.00)		
6	11 (1.31)	10 (1.27)	1 (1.89)		
7	4 (0.48)	4 (0.51)	0 (0.00)		
8	2 (0.24)	2 (0.25)	0 (0.00)		

Data are shown as mean \pm standard deviation or number (%). HCG, human chorionic gonadotropin; CSP, cesarean scar pregnancy

*The Student's t-test was used to analyze data. The remaining data were analyzed by the chi-square test

especially for patients with CSP II/III.^{11,14} The exact pathogenesis of CSP remains unclear. Some studies have shown that occurrence of CSP is related to scar defects after cesarean section.^{15,16} Women who have undergone multiple cesarean sections have severe scar defects, which easily lead to CSP. The patients enrolled in this study had two to eight pregnancies and one to three parities. A total of 42% (361 patients) had a history of multiple cesarean sections (\geq two times), which is consistent with a previous report.¹⁷ Multivariate regression analysis showed that the main reasons for poor hemostasis during curettage after UAE were the presence of multiple blood vessels in the uterus, incomplete embolization of all uterine blood vessels, embolic agent diameter ($>1000\ \mu\text{m}$), parity, and gestational sac size.

Uterine blood supply is mainly derived from bilateral internal iliac artery–uterine artery branches. However, with growth of fetus, a large number of collateral circulations are established, and these are mainly derived from the external iliac artery and thickened ovarian artery.^{8,9,18} Our study showed 45 patients with multiple uterine arteries supplying blood, which mainly originated from the deep circumflex iliac artery, the artery of the round ligament of uterus, the accessory uterine artery, and the ovarian artery. Of these, 27 patients had a hemorrhage volume $>200\ \text{mL}$ during curettage. Twenty-three patients were not completely embolized because the vascular diameter was too thin or there was a tortuous opening, of whom 20 (86.96%) had poor hemostasis after the operation. These findings suggest that complete embolization of all arteries supplying blood to the uterus is a fundamental factor affecting hemostasis, which is similar to the results of previous studies.^{8,9} Leluep et al.⁹ performed secondary interventional surgery in 11 patients with postpartum hemorrhage with poor hemostasis of UAE, of whom

Table 2. Univariate and multivariate regression analyses of risk factors for poor hemostasis.

Variables	Univariate analysis		Multivariate analysis	
	OR (95% CI)	P value	OR (95% CI)	P value
Age	1.00 (0.97, 1.04)	0.857		
Pregnancy period	1.01 (0.98, 1.05)	0.438		
Parity	1.76 (1.04, 2.98)	0.035	2.20 (1.09, 4.43)	0.028
Gravidity	0.88 (0.66, 1.19)	0.407		
HCG	1.00 (1.00, 1.00)	0.702		
Gestational sac size	1.32 (1.17, 1.48)	<0.001	1.22 (1.05, 1.42)	0.012
Embolitic agent diameter				
350–560 μm	I			
560–710 μm	0.90 (0.26, 3.13)	0.867		
710–1000 μm	2.43 (0.82, 7.22)	0.109		
1000–1400 μm	3.04 (1.01, 9.12)	0.047	4.89 (1.12, 21.45)	0.035
Multivessel blood supply				
No	I			
Yes	44.42 (21.77, 90.63)	<0.001	17.89 (5.69, 56.27)	<0.001
Incomplete embolization				
No	1.00			
Yes	158.59 (44.87, 560.48)	<0.001	16.46 (2.82, 96.19)	0.002
CSP typing				
Type I	I			
Type II	0.51 (0.22, 1.17)	0.112		
Type III	2.42 (1.10, 5.29)	0.027	1.58 (0.59, 4.25)	0.360

OR, odds ratio; CI, confidence interval.

10 achieved satisfactory hemostasis after embolization of a total of 16 uterine round ligament arteries. Liang et al.¹⁹ successfully embolized six patients with CSP and a blood supply from branches of the external iliac artery, and the hemostasis rate was as high as 100%. Therefore, when patients with CSP undergo prophylactic UAE, external iliac arteriography should be performed to identify and embolize all arteries supplying blood to the uterus as much as possible. Our finding of poor hemostasis of patients with an embolic agent diameter >1000 μm may be related to failure to achieve peripheral embolization.²⁰ Additionally, the poor hemostatic effect induced by increased parity may be related to thinning of uterine myometrium and an increase in arteries supplying blood to the uterus.²¹ Wang et al.²² showed that a mass

>5 cm was a risk factor for patients with CSP who have curettage or for those with UAE combined with curettage. Our study also showed similar results. The size of the pregnancy sac in the poor hemostasis group was 5.93 ± 2.56 cm. The reason for this finding may be associated with increased blood supply from multiple vessels with enlargement of the fetal sac.

In this study, the postoperative complications of patients were mainly lower abdominal pain, low fever (temperature <38.5°C), and nausea and vomiting. These complications are collectively referred to as post-embolization syndrome, which may be related to an aseptic inflammatory reaction caused by uterine ischemia after embolization.²³ Lower abdominal pain usually occurs 2 to 12 hours after UAE, and the duration of pain is related to the type of

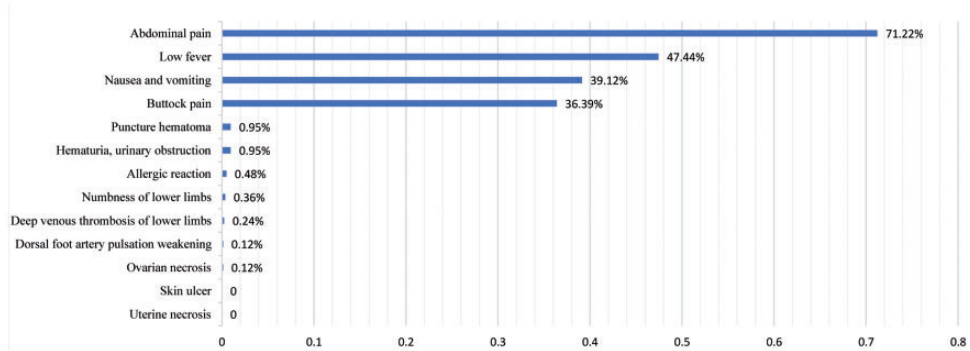


Figure 1. Bar chart of the incidence of adverse reactions and complications

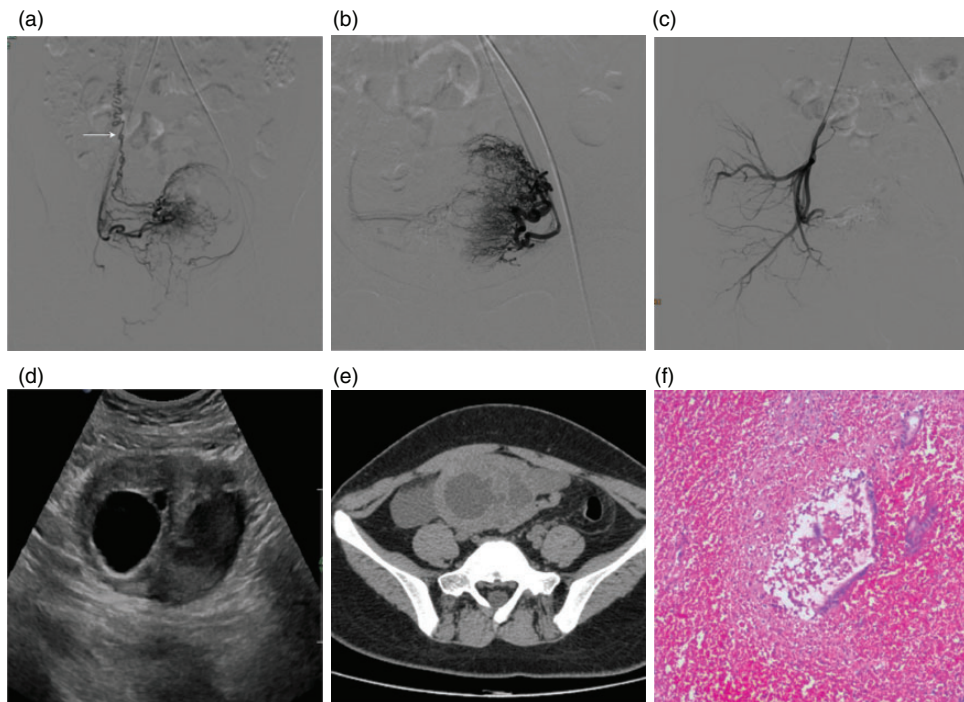


Figure 2. Representative cases of ovarian necrosis. (a) Right uterine arteriography shows retrograde development of the right ovarian artery (arrow). (b) Left uterine arteriography shows vascular tortuosity and thickening. (c) The ovarian artery was invisible after right uterine artery embolization. (d) Twenty days after the operation, ultrasound shows cystic and solid mixed echoes in the right ovarian region. (e) Computed tomography shows a cystic solid mass at the pelvic entrance. (f) Pathology is diagnosed as ovarian necrosis (hematoxylin and eosin stain, $\times 40$)

embolization agent and dosage, and the degree of embolization. In this study, the diameter of the embolic agent was significantly negatively correlated with

postoperative lower abdominal pain and fever. Therefore, a smaller diameter of the embolic agent is associated with a higher incidence of postoperative lower abdominal

Table 3. Multivariate regression analysis of embolic agent diameter, lower abdominal pain, and low fever.

Embolic agent diameter	Lower abdominal pain		Low fever	
	OR (95% CI)	P value	OR (95% CI)	P value
350–560 μm	1		1	
560–710 μm	1.57 (0.84, 2.94)	0.155	0.37 (0.23, 0.59)	<0.001
710–1000 μm	0.40 (0.23, 0.69)	0.001	0.38 (0.24, 0.61)	<0.001
1000–1400 μm	0.24 (0.14, 0.42)	<0.001	0.26 (0.16, 0.42)	<0.001
Total [†]	0.71 (0.62, 0.81)	<0.001	0.53 (0.44, 0.62)	<0.001

OR, odds ratio; CI, confidence interval.

In regression analysis of the embolic agent diameter, the diameter was first analyzed according to categorical variables (category 4). [†]Analysis of the embolic agent diameter according to continuous variables.

pain and fever, which may be related to the capability of a small-diameter embolic agent to achieve peripheral embolism. In a randomized, controlled study, Kim et al.²³ found that intravenous application of small doses of dexamethasone effectively relieved post-embolization syndromes, such as pain, nausea, and vomiting. A similar phenomenon was also observed in this study in that patients who had been injected with a small dose of dexamethasone had less postoperative pain, but this was only based on clinical observation and experience, and lacked statistical analysis.

Ectopic embolization is the most serious complication of UAE. This complication mainly manifests as ischemia and necrosis of ectopic embolized organs or tissues, such as local necrosis of the gluteal muscle, ureter, bladder, rectum, and ovary.²⁴ In our study, buttock pain was a main complication of ectopic embolism, with an incidence rate of 36.39% (306 patients). Additionally, urinary tract obstruction was found in eight patients, ovarian necrosis in one patient, and weakening of dorsal foot artery pulsation in one patient (Figure 1). The direct cause of buttock pain is embolism of the superior gluteal artery or inferior gluteal artery. We used gelfoam particles as the embolic agent in our study. Green et al.²⁵ did not report any cases of gluteal muscle necrosis. In our

study, eight patients had urinary tract obstruction with dysuria and hydronephrosis. All of these patients improved after spasmolytic treatment. The causes of urinary tract obstruction might be related to communication between the uterine artery, ureter, and bladder artery. In our patients with ureteral obstruction, the injection pressure was too large and the diameter of the embolic agent was too small during embolization, resulting in ischemic spasm of the ureter. The ovary is supplied by the uterine artery and ovarian artery. Whether uterine-ovarian anastomosis should be embolized during UAE is still controversial.^{26,27} Reports of ovarian necrosis induced by UAE are extremely rare. However, during the follow-up in the current study, one patient had right ovarian necrosis (Figure 2), which may have been related to the small diameter of the embolic agent (350–560 μm). To prevent serious complications of ectopic embolism, the authors suggest the following. (1) Superselective intubation embolization treatment must be carried out, and blood supply branches, such as in the bladder and rectum, should especially be avoided. (2) The appropriate size of the embolic agent should be selected, and we suggest that the diameter of the embolic agent should be $>560 \mu\text{m}$.²⁰ If ovarian branches are present, an embolic agent with a larger diameter is

recommended. (3) When injecting an embolic agent, the whole process should be supervised under fluoroscopy to avoid necrosis of organs due to reflux of the embolic agent.

This study has some limitations as follows. There was a lack of an accurate method for diagnosing whether the uterus was supplied by multiple vessels. Digital subtraction angiography as an evaluation method still has a probability of missed detection. Further studies are required to determine whether more clinical and examination results will increase the risk of hemorrhage, such as application of methotrexate.

Conclusion

Prophylactic UAE can reduce the risk of massive hemorrhage during curettage. Gestational sac size, parity, embolic agent diameter, multivessel blood supply, and incomplete embolization of all arteries supplying blood to the uterus are risk factors of poor hemostasis. Finding and embolizing all arteries supplying blood to the uterus will guarantee hemostatic efficacy of UAE. Furthermore, selecting appropriate embolic agents can reduce the occurrence of complications.

Declaration of conflicting interest

The authors declare that there is no conflict of interest.

Funding


This study was supported by Xianning Science and Technology Bureau (Grant no. 2018043).

ORCID iDs

Hongan Tian  <https://orcid.org/0000-0001-6887-8598>

Shunzhen Li  <https://orcid.org/0000-0001-7110-9570>

Wanwan Jia  <https://orcid.org/0000-0002-8395-6459>

Kaihu Yu  <https://orcid.org/0000-0001-5689-8401>

Guangyao Wu  <https://orcid.org/0000-0002-3966-9268>

References

1. Ying X, Zheng W, Zhao L, et al. Clinical characteristics and salvage management of persistent cesarean scar pregnancy. *J Obstet Gynaecol Res* 2017; 43: 1293–1298. DOI: 10.1111/jog.13367.
2. Birch Petersen K, Hoffmann E, Rifbjerg Larsen C, et al. Cesarean scar pregnancy: a systematic review of treatment studies. *Fertil Steril* 2016; 105: 958–967. DOI: 10.1016/j.fertnstert.2015.12.130.
3. Shu SR, Luo X, Wang ZX, et al. Cesarean scar pregnancy treated by curettage and aspiration guided by laparoscopy. *Ther Clin Risk Manag* 2015; 11: 1139–1141. DOI: 10.2147/TCRM.S86083.
4. Riaz RM, Williams TR, Craig BM, et al. Cesarean scar ectopic pregnancy: imaging features, current treatment options, and clinical outcomes. *Abdom Imaging* 2015; 40: 2589–2599. DOI: 10.1007/s00261-015-0472-2.
5. Cao GS, Liu RQ, Liu YY, et al. Menstruation recovery in scar pregnancy patients undergoing UAE and curettage and its influencing factors. *Medicine (Baltimore)* 2018; 97: e9584. DOI: 10.1097/MD.0000000000009584.
6. Maheux-Lacroix S, Li F, Bujold E, et al. Cesarean Scar Pregnancies: A Systematic Review of Treatment Options. *J Minim Invasive Gynecol* 2017; 24: 915–925. DOI: 10.1016/j.jmig.2017.05.019.
7. Feng Y, Chen S, Li C, et al. Curettage after uterine artery embolization combined with methotrexate treatment for caesarean scar pregnancy. *Exp Ther Med* 2016; 12: 1469–1475. DOI: 10.3892/etm.2016.3489.
8. Tokue H, Tokue A, Tsushima Y, et al. Risk factors for massive bleeding based on angiographic findings in patients with placenta previa and accreta who underwent balloon occlusion of the internal iliac artery during

- cesarean section. *Br J Radiol* 2019; 92: 20190127. DOI: 10.1259/bjr.20190127.
9. Leleup G, Fohlen A, Dohan A, et al. Value of Round Ligament Artery Embolization in the Management of Postpartum Hemorrhage. *J Vasc Interv Radiol* 2017; 28: 696–701. DOI: 10.1016/j.jvir.2017.01.016.
 10. Du YJ, Zhang XH and Wang LQ. Risk Factors for Haemorrhage during Suction Curettage after Uterine Artery Embolization for Treating Caesarean Scar Pregnancy: A Case-Control Study. *Gynecol Obstet Invest* 2015; 80: 259–264. DOI: 10.1159/000381263.
 11. Family Planning Group of the Obstetrics and Gynecology Credit Association of the Chinese Medical Association. Expert opinion of diagnosis and treatment of cesarean scar pregnancy (2016). *Chin J Obstet Gynecol* 2016; 51: 568–572. DOI: 10.3760/cma.j.issn.0529-567X.2016.08.003.
 12. Khan KS, Wojdyla D, Say L, et al. WHO analysis of causes of maternal death: a systematic review. *Lancet* 2006; 367: 1066–1074. DOI: 10.1016/S0140-6736(06)68397-9.
 13. Gonzalez N and Tulandi T. Cesarean Scar Pregnancy: A Systematic Review. *J Minim Invasive Gynecol* 2017; 24: 731–738. DOI: 10.1016/j.jmig.2017.02.020.
 14. Guo J, Yu J, Zhang Q, et al. Clinical efficacy and safety of uterine artery embolization (UAE) versus laparoscopic cesarean scar pregnancy debridement surgery (LCSPDS) in treatment of cesarean scar pregnancy. *Med Sci Monit* 2018; 24: 4659–4666. DOI:10.12659/MSM.907404.
 15. Roberge S, Boutin A, Chaillet N, et al. Systematic review of cesarean scar assessment in the nonpregnant state: imaging techniques and uterine scar defect. *Am J Perinatol* 2012; 29: 465–471. DOI: 10.1055/s-0032-1304829.
 16. Antila-Langsjö RM, Maenpää JU, Huhtala HS, et al. Cesarean scar defect: a prospective study on risk factors. *Am J Obstet Gynecol* 2018; 219: 458.e1–458.e8. DOI: 10.1016/j.ajog.2018.09.004.
 17. Xie RH, Guo X, Li M, et al. Risk factors and consequences of undiagnosed cesarean scar pregnancy: a cohort study in China. *BMC Pregnancy Childbirth* 2019; 19: 383. DOI: 10.1186/s12884-019-2523-0.
 18. Sheikh GT, Najafi A, Cunier M, et al. Angiographic Detection of Utero-Ovarian Anastomosis and Influence on Ovarian Function After Uterine Artery Embolization. *Cardiovasc Intervent Radiol* 2020; 43: 231–237. DOI: 10.1007/s00270-019-02305-7.
 19. Liang H, Yan L, Han X, et al. The application value of external iliac artery angiography in uterine artery embolization for postpartum hemorrhage in delivery women with scarred uterus. *Journal of Interventional Radiology (China)* 2018; 27: 481–484. DOI: 10.3969/j.issn.1008-794X.2018.05.020.
 20. Song Y, Woo Y and Kim CW. Uterine artery embolization using progressively larger calibrated gelatin sponge particles. *Minim Invasive Ther Allied Technol* 2015; 25: 1–8. DOI: 10.3109/13645706.2015.1092449.
 21. DeMeritt J, Wajswol E, Wattamwar A, et al. Serial Uterine Artery Embolization for the Treatment of Placenta Percreta in the First Trimester: A Case Report. *Cardiovasc Intervent Radiol* 2018; 41: 1280–1284. DOI: 10.1007/s00270-018-1929-9.
 22. Wang M, Yang Z, Li Y, et al. Conservative management of cesarean scar pregnancies: a prospective randomized controlled trial at a single center. *Int J Clin Exp Med* 2015; 8: 18972–18980.
 23. Kim SY, Koo BN, Shin CS, et al. The effects of single-dose dexamethasone on inflammatory response and pain after uterine artery embolisation for symptomatic fibroids or adenomyosis: a randomised controlled study. *BJOG* 2016; 123: 580–587. DOI: 10.1111/1471-0528.13785.
 24. Keung JJ, Spies JB and Caridi TM. Uterine artery embolization: A review of current concepts. *Best Pract Res Clin Obstet Gynaecol* 2018; 46: 66–73. DOI: 10.1016/j.bpobgyn.2017.09.003.
 25. Green AN, Goldberg L and Balica AC. Unilateral Gluteal Necrosis: A Rare Complication of Uterine Artery Embolization.

- J Minim Invasive Gynecol* 2019; 26: 354–355. DOI: 10.1016/j.jmig.2018.05.015.
26. OuYang ZB, Wu JW and Tian ZF. The Value of Utero-Ovarian Anastomosis in Uterine Artery Embolization is Still Controversial. *Cardiovasc Intervent Radiol* 2020; 43: 350–351. DOI: 10.1007/s00270-019-02377-5.
27. Jain V. Ovarian Artery Embolization in a Case of Refractory Obstetric Hemorrhage. *J Clin Imaging Sci* 2019; 9: 30. DOI: 10.25259/JCIS-39-2019.