

Subretinal drusenoid deposits versus drusen on multicolor imaging

Ramesh Venkatesh, Arpitha Pereira, Sherina Thomas, Sajjan Sangai, Kushagra Jain, Vivek Singh, Nikhita G Reddy, Naresh K Yadav

Key words: Drusen, multicolor imaging, optical coherence tomography, subretinal drusenoid deposits

Case 1

A 73-year-old man presented with a visual acuity of 6/6, N6 in the right eye (RE) and 6/36, N18 in the left eye (LE). Anterior segment examination of both eyes (BE) was normal. RE fundus showed multiple large, fluffy yellow posterior pole drusen. LE fundus showed a macular scar secondary to wet age-related macular degeneration (ARMD). Drusenoid material within the pigment epithelial detachment was noted as being picked up better on infrared reflectance (IR) image [Fig. 1a-e].

Case 2

A 53-year-old man with 6/9, N6 in BE was diagnosed with dry ARMD in BE. Examination showed drusen at the posterior pole. The optical coherence tomography (OCT) scans delineate the sub-retinal pigment epithelium (RPE) drusen which are further visualized clearly on the IR image [Fig. 1f-o].

Case 3

Fundus examination of a 71-year-old lady with visual acuity was 6/6 showed multiple, flat, pale-yellow posterior pole deposits located in the retinal deeper layers, more along the superotemporal arcade suggestive of intermediate ARMD. The OCT showed multiple hyperreflective spots between retina and RPE, suggestive of SDDs. The SDDs were also well-visualized on the green reflectance (GR) and blue reflectance (BR) images compared to IR image [Fig. 2a-e].

Case 4

A 79-year-old lady presented with visual acuity of 6/9, N6 in BE. Examination of BE showed multiple, yellow dots at the posterior pole, concentrated superior to macula. The dot-like

SDDs were visualized on the GR and BR images and were not seen on the IR image [Fig. 2f-j].

Discussion

Subretinal drusenoid deposits (SDD), also known as reticular pseudo drusen are identified on optical coherence tomography (SD-OCT) as hyperreflective spots located between neurosensory retina and RPE.^[1] The clinical relevance of SDDs lies in their association with the late forms of ARMD.^[1,2] SD-OCT is an important and valuable tool to differentiate between the SDD and drusen. MCI utilizes three laser colors: blue (488 nm); green (515 nm); and infrared (820 nm) that penetrate the tissue at different depths and captures the reflectance strengths from different retinal structures and represent the information as en face images.^[3] The IR image visualizes structures at the level of the outer retina, RPE and choroid. In this report, we found both varieties were identified on the multicolor image. The identification of the SDD on GR image and to a lesser extent on the BR image contributed to its visualization of the composite MCI. The SDDs were not visualized on the IR image. On the contrary, soft sub-RPE drusen were highlighted on the IR image, but not readily identifiable on the GR and BR images. This contributed to its visualization as yellow-orange colored lesions on the composite MCI. In certain instances, they may be identified on the GR and BR images too as a consequence of their composition or the elevation produced by the drusenoid pigment epithelium detachment and the overlying RPE status. This contrasting reflectance pattern between the SDD and drusen could possibly be explained by the absent esterified cholesterol in SDD and the light absorption characteristics of cholesterol.^[4]

To conclude, SDD can be distinguished from drusen on the basis of its appearance and identification on the GR images. The addition of MCI to SD-OCT imaging could further assist in the accurate diagnosis of SDD.

Declaration of patient consent

The authors certify that they have obtained all appropriate patient consent forms. In the form the patient(s) has/have given his/her/their consent for his/her/their images and other clinical information to be reported in the journal. The patients understand that their names and initials will not be published and due efforts will be made to conceal their identity, but anonymity cannot be guaranteed.

Financial support and sponsorship

Nil.

Access this article online	
Quick Response Code:	Website: www.ijjo.in
	DOI: 10.4103/ijjo.IJO_1900_19

Department of Retina and Vitreous, Narayana Nethralaya, #121/C, 1st R Block, Chord Road, Rajaji Nagar, Bengaluru, Karnataka, India

Correspondence to: Dr. Ramesh Venkatesh, Narayana Nethralaya, Department of Retina and Vitreous, #121/C, 1st R Block, Chord Road, Rajaji Nagar, Bengaluru, Karnataka - 560 010, India. E-mail: vramesh80@yahoo.com

Received: 16-Oct-2019

Revision: 02-Nov-2019

Accepted: 31-Jan-2020

Published: 25-Jun-2020

This is an open access journal, and articles are distributed under the terms of the Creative Commons Attribution-NonCommercial-ShareAlike 4.0 License, which allows others to remix, tweak, and build upon the work non-commercially, as long as appropriate credit is given and the new creations are licensed under the identical terms.

For reprints contact: reprints@medknow.com

Cite this article as: Venkatesh R, Pereira A, Thomas S, Sangai S, Jain K, Singh V, *et al.* Subretinal drusenoid deposits versus drusen on multicolor imaging. Indian J Ophthalmol 2020;68:1450-1.

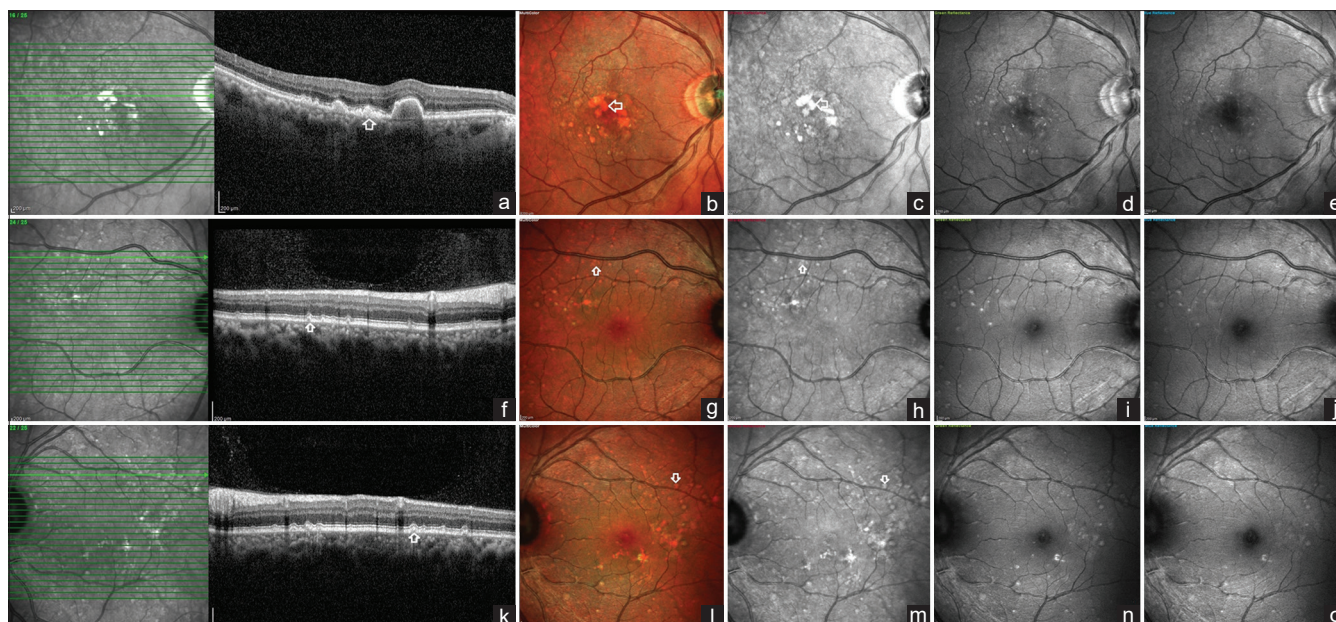


Figure 1: SD-OCT and Multicolor imaging characteristics in sub-RPE drusen (case 1 and 2): (a-e) Spectral-domain optical coherence tomography (SD-OCT) scan of case 1 shows the presence of sub-retinal pigment epithelium (RPE) drusen in the right eye (RE) (white arrow). Multicolor image and infrared reflectance (IR) images identify the drusen as bright-orange colored and white hyperreflective lesions, respectively (white arrows). On the blue reflectance (BR) and green reflectance (GR) images, the drusen are not visualized. (f-o) SD-OCT imaging of BE in case 2 shows the presence of drusen at the sub-RPE level. The drusen stands out prominently on multicolor and infrared reflectance images (white arrows) compared to BR and GR images

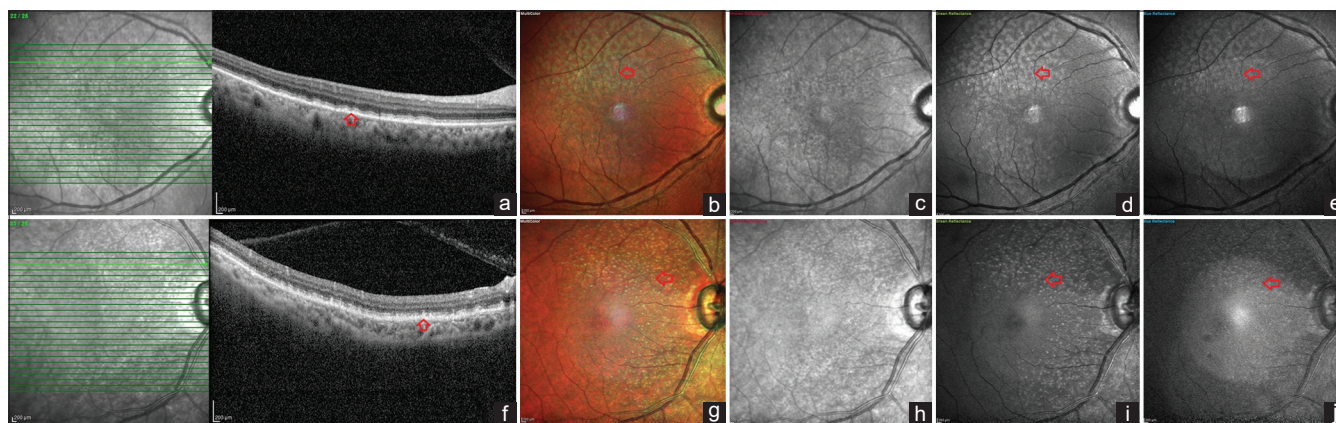


Figure 2: SD-OCT and Multicolor imaging characteristics in sub drusenoid deposits (case 3 and 4): (a-e) SD-OCT imaging shows the presence of drusenoid deposits at the subretinal space, above the RPE (red arrow) in the RE of case 3. On the multicolor image, the SDD is seen as multiple pale-yellow ribbon-like lesions close to the vascular arcades. On the infrared reflectance image, the lesions are not identified. Corresponding hyper-reflective white lesions are noted on the GR image and less so on the BR image (red arrows). (f-j) SD-OCT imaging shows the presence of drusenoid deposits at the subretinal space, above the RPE (red arrow) in the RE of case 4. On the multicolor image, the SDD is seen as multiple pale-yellow dot-like lesions close to the vascular arcades. On the infrared reflectance image, the deposits are not identified. Corresponding hyper-reflective white lesions are noted on the GR image and less so on the BR image (red arrows)

Conflicts of interest

There are no conflicts of interest.

References

- Spaide RF, Ooto S, Curcio CA. Subretinal drusenoid deposits AKA pseudodrusen. *Surv Ophthalmol* 2018;63:782-815.
- Balaratnasingam C, Cherepanoff S, Dolz-Marco R, Killingsworth M, Chen FK, Mendis R, *et al*. Cuticular drusen: Clinical phenotypes and natural history defined using multimodal imaging. *Ophthalmology* 2018;125:100-18.
- Tan ACS, Fleckenstein M, Schmitz-Valckenberg S, Holz FG. Clinical application of multicolor imaging technology. *Ophthalmologica* 2016;236:8-18.
- Zhu W-H, Zhao Z-M, Guo X, Chen H. [Study of cholesterol concentration based on serum UV-visible absorption spectrum]. *Guang Pu Xue Yu Guang Pu Fen Xi Guang Pu* 2009;29:1004-7.