

# Fractal dimension, lacunarity, and cortical thickness in the mandible: Analyzing differences between healthy men and women with cone-beam computed tomography

Ingrid Garcia Santos<sup>1</sup>, Fernanda Ramos de Faria<sup>1</sup>, Marcio José da Silva Campos<sup>1</sup>,  
Beatriz Álvares Cabral de Barros<sup>2</sup>, Gustavo Davi Rabelo<sup>1,2,\*</sup>, Karina Lopes Devito<sup>1</sup>

<sup>1</sup>School of Dentistry, Universidade Federal de Juiz de Fora, Juiz de Fora, Minas Gerais, Brazil

<sup>2</sup>Department of Dentistry, Universidade Federal de Santa Catarina, Florianópolis, Santa Catarina, Brazil

## ABSTRACT

**Purpose:** The objective of this study was to assess the fractal dimension, lacunarity, trabecular microarchitecture parameters, and cortical linear measurements in the mandibles of male and female individuals to identify differences between them.

**Materials and Methods:** In total, 116 cone-beam computed tomography scans of healthy individuals of different ages (57 men and 59 women, aged between 20 and 60 years) were selected. The following bone parameters were measured: 1) buccal, lingual, and basal cortical bone thickness in 5 standard parasagittal sections (the midline, the left and right sides of the lower lateral incisors, and the left and right sides of the lower canines); 2) the bone volume fraction of 10 sequential axial sections from each patient by creating a volume of interest in the area between the lower canines; and 3) fractal dimension and lacunarity using grayscale images of the same region of the volume of interest in the anterior mandible. Spearman correlation coefficients and the Mann-Whitney test were used.

**Results:** A significant and positive correlation was found between age and cortical thickness, especially in the region of the central incisors. Significant differences between sexes in terms of fractal dimension, lacunarity, and bone volume were found. Women revealed lower fractal dimension values and higher lacunarity and bone volume ratio values than men.

**Conclusion:** Fractal dimension, lacunarity, trabecular bone volume, and cortical thickness were different between men and women of different ages. (*Imaging Sci Dent* 2023; 53: 153-9)

**KEY WORDS:** Mandible; Bone and Bones; Fractals; Cone-Beam Computed Tomography

## Introduction

Morphological and morphometric differences between male and female individuals are evident in anatomical, biological, and physiological analyses of bone,<sup>1</sup> which are conducted for forensic and other purposes. The mandible is one of the most reliable structures for determining sex in humans.<sup>2,3</sup> The mandibular bone is usually analyzed according to standard morphometric measurements, such as man-

dibular ramus height and width, body length, and symphyseal height.<sup>4,5</sup> However, little is known about the microstructural differences that show substantial differences between sexes besides pathologic conditions. Generally, the bone microarchitecture of the mandible is assessed to diagnose and monitor diseases, such as osteoporosis and other metabolic alterations,<sup>6</sup> and the bone microarchitecture can be used to distinguish male from female individuals in these conditions.

Most studies have used X-ray imaging exams to assess bone microarchitecture.<sup>7</sup> Conventional radiography, although it has good clinical applicability, has some limitations, mainly related to its 2-dimensionality and overlapping structures. Cone-beam computed tomography (CBCT) offers some advantages over these limitations, since it has excellent

The authors thank the Coordenação de Aperfeiçoamento de Pessoal de Nível Superior - Brasil (CAPES) - Finance Code 001, for the scholarships.

Received February 18, 2023; Revised April 11, 2023; Accepted April 14, 2023

Published online May 19, 2023

\*Correspondence to : Prof. Gustavo Davi Rabelo

Departamento de Odontologia, Universidade Federal de Santa Catarina, Rua Delfino Conti, 1240, Bairro Trindade, Florianópolis, SC, CEP: 88040-900, Brazil

Tel) 55-48-3721-9520, E-mail) drgustavorabelo@yahoo.com.br

Copyright © 2023 by Korean Academy of Oral and Maxillofacial Radiology

This is an Open Access article distributed under the terms of the Creative Commons Attribution Non-Commercial License (<http://creativecommons.org/licenses/by-nc/3.0>) which permits unrestricted non-commercial use, distribution, and reproduction in any medium, provided the original work is properly cited.

Imaging Science in Dentistry · pISSN 2233-7822 eISSN 2233-7830

resolution, allows the assessment of multiple images, and provides a 3-dimensional reconstruction of the bones.<sup>8</sup>

Fractal dimension (FD) and lacunarity (Lac), which are assessed based on radiographs and other imaging techniques, are regarded as important research tools in bone investigation. These parameters relate to bone irregularity (meaning irregular patterns with self-similarity at different scales) and “gappiness” (from the Latin word *lacuna*, referring to gap or hole variability), respectively.<sup>9,10</sup> Several studies have used FD and Lac to assess the differences between groups of individuals with different diseases and conditions.<sup>6,11,12</sup> Briefly, FD measures how the bone fills a metric space, and Lac measures the distribution of gaps in the bone.<sup>10</sup> In addition to these parameters, quantitative methods can also be used to assess the bone microarchitecture, usually by calculating the bone volume fraction (BV/TV), which corresponds to the bone volume in a given area (i.e., the volume of mineralized bone per volume unit in the sample).<sup>13-15</sup>

In sex differentiation, age should also be considered, since structural alterations in both cortical and trabecular bone are associated with aging.<sup>6,10</sup> Sex determination, which can be done through bone texture analysis using X-ray images, is of great interest. Therefore, the present study aimed to measure the trabecular parameters of FD, Lac, and BV/TV, together with the cortical thickness, in the mandibles of healthy adults from 20 to 60 years of age to determine their sex.

## Materials and Methods

### Study design and sample selection

This retrospective observational cross-sectional study was approved by the Institutional Research Ethics Committee (CAAE 87082818.4.0000.5147, approval number 2.642.813). The CBCT exams were selected from the archives of the dental radiology service. The institutional protocol was followed when performing the CBCT exams. The equipment (i-Cat Next Generation, Imaging Sciences International, Hatfield, PA, USA) had the following specifications: 120 kV, 8 mA, rotation time of 26.9 s, voxel size of 0.25 mm, and minimum field of view of 7 × 23 cm. CBCT scans were selected from patients of both sexes, aged from 20 to 60 years, who had all lower anterior teeth (central and lateral incisors, and canine). All individuals who had a previous history of mandibular surgery, mandibular trauma, bone pathologies in the anteroinferior region, bone-metabolic systemic diseases, or use of drugs that interfere with bone metabolism were excluded.

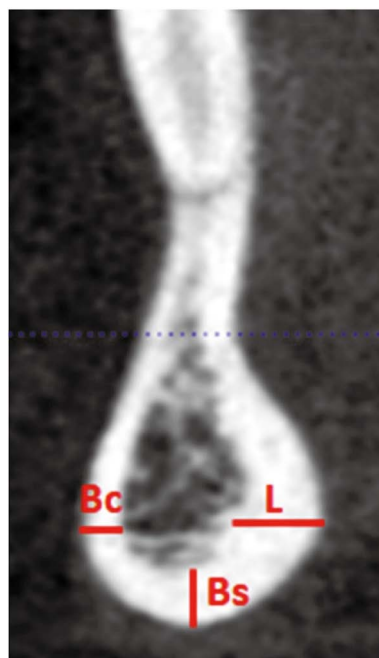
The patients were divided into 2 groups according to sex: male and female. Each group was subdivided into 4 subgroups according to age: 21 to 30, 31 to 40, 41 to 50, and 51 to 60 years old. To determine the number of patients, a sample calculation was performed, which indicated a minimum value of 114 exams, considering  $N = 660$  (the number of CBCT exams that met the inclusion criteria) and  $Z = 1.65$ , with a confidence level of 90% and a margin of error of 7%.

### Compliance with ethical standards

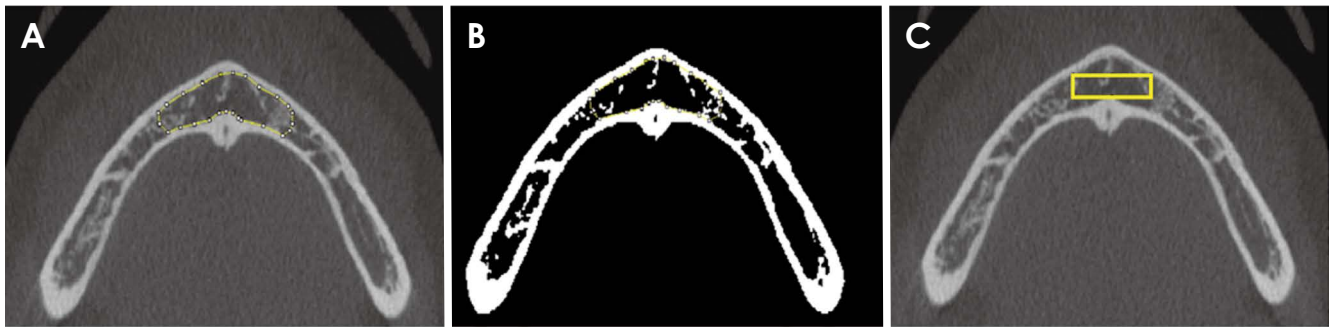
All procedures performed involving human participants were in accordance with the ethical standards of the institutional and/or national research committee and with the 1964 Helsinki Declaration and its later amendments or comparable ethical standards, as described in the Materials and Methods section.

### Cortical bone thickness

The CBCT scans of 5 parasagittal sections were assessed with the following reference lines: 1) over the midline of the mandible, between the lower central incisors; 2) in the center of the right lateral incisor; 3) in the center of the lower-right canine; 4) in the center of the left lateral incisor; 5) in the center of the lower-left canine. Linear measurements of the buccal, lingual, and basal cortices were



**Fig. 1.** The cortical bone thickness in the buccal (Bc), lingual (L), and basal (Bs) aspects is measured on a parasagittal section of cone-beam computed tomography.



**Fig. 2.** A. Axial section of cone-beam computed tomography (CBCT) with a region of interest (ROI) for assessing the bone volume fraction (BV/TV) in the trabecular bone. B. Binary image to assess the BV/TV. C. Axial section of CBCT with an ROI for evaluating the trabecular bone texture, such as the fractal dimension and lacunarity.

performed in each parasagittal section. To determine the measurements on the outer surface of the cortical bone, the i-CAT Vision software (Imaging Sciences International, Hatfield, PA, USA) was used (Fig. 1).

#### Assessment of the bone volume fraction

To assess the trabecular bone volume, the ImageJ software (National Institutes of Health, Bethesda, MD, USA) was used. Initially, 10 sequential axial sections were selected from each patient. The first section did not show the dental apex of the roots of the anterior teeth and only revealed the trabecular and cortical bone structure. A region of interest (ROI) was manually drawn to highlight the trabecular bone between the lower canines on all selected axial sections (Fig. 2A). The ROIs were then interpolated to create the 3D volume. For the binarization process, a global threshold of 111/255 (Fig. 2B) was selected. From the binary images of the volume, the following parameters were assessed: BV (the number of voxels represented by the trabecular bone), TV (the total number of voxels of the entire volume), and BV/TV (the bone volume fraction, i.e., the volume of mineralized bone per volume unit in the sample). The BoneJ plugin was used to obtain the BV, TV, and BV/TV (available at: <https://bonej.org/volume-fraction>).

#### Fractal dimension and lacunarity

FD and Lac were determined using the same sections used to determine the BV/TV. However, these sections were not binarized and remained in grayscale. A rectangular ROI was defined between the lower canines over the trabecular bone (Fig. 2C). The FracLac plugin was used with the box-counting method and the “Gray 1: Differential” option. This plugin finds the average intensity of pixels per box on a grayscale image. The differential type uses a method that is very similar to mass box counting.<sup>16</sup> The

method for FD analysis in grayscale images was based on the study of da Silva et al.<sup>17</sup> The FD and Lac values of 3 different sections were calculated (the first, sixth, and 10th CBCT sections, the same sections used for BV/TV), and then the average of each value across the 3 sections was calculated.

#### Statistical analysis

The Mann-Whitney test was applied to identify the differences between the sexes in terms of the assessed parameters. In addition, Spearman correlation coefficients were calculated to determine the correlation between age and said parameters. SPSS version 21.0 for Windows (IBM Corp., Armonk, NY, USA) was used for the statistical analysis. Intraclass correlation coefficients were also calculated. The significance level was defined at 5% ( $P < 0.05$ ).

## Results

Two previously calibrated examiners with expertise in CBCT interpretation assessed the cortical bone thickness separately. To determine intra-examiner agreement, 20% of the sample was randomly reassessed. Statistical significance ( $P < 0.05$ ) was observed for the intraclass correlation coefficients (ICCs), which showed moderate to strong agreement (0.52-0.90, with the only 2 ICC values under 0.6 being for the lower central and lateral incisors, at the buccal and lingual walls, respectively).

In total, 116 CBCT exams of healthy individuals were analyzed, from 57 men and 59 women, ranging from 20 to 60 years old, who were divided into subgroups according to sex and age (Table 1). As there was no significant difference in age between men and women ( $P = 0.23$ , Table 2), all following comparisons (trabecular analysis of FD, Lac, and BV/TV; cortical linear measurements) were considered

**Table 1.** Sample distribution in relation to sex and age groups

Sex	Age				Total
	21 to 30	31 to 40	41 to 50	51 to 60	
Female	14 (12.1%)	15 (12.9%)	15 (12.9%)	15 (12.9%)	59 (50.9%)
Male	15 (12.9%)	15 (12.9%)	14 (12.0%)	13 (11.2%)	57 (49.1%)
Total	29 (25.0%)	30 (25.9%)	29 (25.0%)	28 (24.1%)	116 (100.0%)

**Table 2.** Comparison between men and women regarding age, texture analysis, and cortical thickness

Parameters	Men	Women
Age (years)	37.9 ± 13.9	40.1 ± 12.5
Bone texture analysis		
Fractal dimension	1.02 ± 0.23	0.97 ± 0.17*
Lacunarity	0.12 ± 0.04	0.15 ± 0.04*
BV/TV	0.28 ± 0.14	0.36 ± 0.12*
Cortical thickness (mm)		
Central incisor		
Buccal	2.85 ± 0.50	2.83 ± 0.61
Lingual	4.95 ± 0.94	4.69 ± 1.29*
Basal	3.45 ± 1.16	4.30 ± 2.18
Lateral incisor		
Buccal	2.75 ± 0.44	2.81 ± 0.50
Lingual	4.83 ± 1.07	4.57 ± 1.06*
Basal	3.61 ± 1.05	4.12 ± 1.34*
Canine		
Buccal	3.00 ± 0.48	2.91 ± 0.46*
Lingual	4.45 ± 1.13	4.19 ± 0.83
Basal	3.88 ± 0.98	3.77 ± 0.73

\*:  $P < 0.05$  by the Mann-Whitney test, BV: bone volume, TV: total volume

to compare all male subjects versus all female subjects.

Comparisons between the sexes for each parameter are shown in Table 2. The values for FD, Lac, and BV/TV were significantly different between men and women. Regarding the analysis in grayscale (without binarization), men revealed higher FD and lower Lac values than women. The values for bone volume through binarization were higher in women. Significant differences were also found between the sexes in terms of cortical thickness linear measurements. In men, the lingual wall in the central and lateral incisor areas and the buccal wall in the canine area were thicker than in women (Table 2).

A statistically significant and positive correlation was found between age and all linear measurements of the cortical bone in the central incisor area. A correlation was also

**Table 3.** Spearman correlation coefficient ( $r_s$ ) between age and each texture parameter and cortical thickness

Parameters	Correlation with age - $r_s$ value
Bone texture analysis	
Fractal dimension	-0.16
Lacunarity	-0.01
BV/TV	0.11
Cortical thickness (mm)	
Central incisor	
Buccal	0.32*
Lingual	0.25*
Basal	0.33*
Lateral incisor	
Buccal	0.19
Lingual	0.18
Basal	0.28*
Canine	
Buccal	0.11
Lingual	0.08
Basal	0.27*

\*Significant correlation with  $P < 0.05$ , BV: bone volume, TV: total volume

identified between age and the cortical thickness in the basal part of the mandible in the 3 analyzed areas. Although these correlations were statistically significant and positive (i.e., the direction of association between the variables was such as one increased, so did the other), they were not strong, with correlation coefficients less than 0.4 (Table 3).

## Discussion

In the present study, men and women with a wide range of ages showed differences in terms of FD and Lac. BV/TV was also different between the sexes, as women presented higher values of trabecular volume in the anterior mandible than men. According to the literature, bone loss is mainly observed in female individuals, as has been demonstrated in several studies. Research on postmenopausal osteopo-

rosis, usually diagnosed in the lumbar spine and proximal femur of woman > 50 years of age, has revealed that an imbalance in bone formation and resorption affects trabecular bone (loss of connectivity) and cortical bone (cortical thinning and porosity).<sup>18,19</sup> However, some facts need to be considered when comparing those studies with the results of the present study, as follows: the difference in the ossification process (intramembranous in the mandible and endochondral in the long bones);<sup>20</sup> differences in the turnover rates (in the jaw bones, turnover could be 10 times more active, mostly considering the masticatory behavior and the related biomechanics);<sup>21</sup> the age of the women included in other studies (bone loss is more evident in postmenopausal woman,<sup>18,19</sup> while our study included young women, with an age range starting at 20 years); and finally, in general (regarding all bones at different ages, considering sexual dimorphism), androgen hormones are more related to the longitudinal growth of bones in the cortical area (mostly because of the delay in growth plate closure), whereas estrogen favors the growth of trabecular bone.<sup>22</sup>

Besides trabecular bone volume, the additional parameters evaluated in our study (FD and Lac) showed statistically significant differences in men and women from 20 to 60 years of age, implying that they might be useful parameters for sex determination when combined with conventional parameters such as bone volume and thickness. Regarding mandible thickness, both sexes presented differences in terms of cortical thickness in some areas of the anterior mandible, but not in all analyzed areas. Measuring the cortical thickness of the lingual wall in the central incisor area of the mandible seems to be a reliable method for sex determination, mainly because it is easy to access this area using CBCT.

Sex determination is very important for the forensic process of human identification. Sex is usually the second out of the 4 parameters that are addressed in biological profile assessments (population affinity, sex, age, and height) since many methods for estimating age and height rely on sex identification. There are only 2 possible results for sex determination: male or female. In contrast, the results of the other parameters are much more diverse.<sup>2,23</sup> Forensic anthropological analyses for sex determination can use qualitative characteristics (i.e., morphological and osteological analysis) or quantitative characteristics (i.e., osteometric analysis).<sup>2,3</sup> Sex determination based on the skeleton depends on the available bones and their state of preservation, and it can be particularly difficult when the bones are fragmented.

The mandible is the largest and hardest facial bone. It usually resists postmortem damage and is thus an import-

ant indicator of sexual dimorphism.<sup>2,3,24,25</sup> The mandibular bone can reveal sexual dimorphism<sup>2,3</sup> through standard morphometric measurements, such as the mandibular angle, ramus height, and mandibular symphysis.<sup>2,3,24,25</sup> However, little is known about the microstructural bone differences between the sexes and how those differences can be used for sex determination.

Parameters related to bone complexity could yield new insights into sexual dimorphism in addition to conventional linear measurements. FD analysis is a mathematical method for analyzing complex shapes and structural patterns. A meta-analysis<sup>26</sup> revealed that FD assessments based on dental radiographs were unable to distinguish healthy individuals from patients with osteoporosis based on dental images. The authors concluded that a standardized FD calculation is needed. In addition to radiographs, analyses of CBCT images could be improved, including other parameters, such as bone microarchitecture. The present study calculated FD and Lac based on CBCT images to obtain data that could later be used in sex determination. FD was assessed based on grayscale CBCT images because it was considered a good option for an *in vivo* high-resolution assessment of the trabecular microstructure of the mandible. Gaalaas et al.<sup>27</sup> performed a texture analysis based on CBCT images of healthy individuals, but did not find a significant difference between the sexes. In contrast, other authors,<sup>28</sup> who assessed FD in healthy individuals, found significant differences between the sexes, similar to the present study. When comparing men and women over the age of 40, those authors found a significant difference in the area of the mandibular first premolars and condyle. When comparing individuals younger than 40, they found a significant difference in the area of the maxillary premolars and the mandibular lateral incisors.

A systematic review<sup>29</sup> revealed that, out of 15 studies that assessed FD based on CBCT, all of them analyzed the trabecular bone, and 14 of them used the box-counting method, with values ranging from 0.91 to 2.4. Our study found a mean FD value of 1.02 in men and 0.97 in women. Although these values coincide with the intervals reported by other studies on CBCT, the use of grayscale images, without binarization, was a new approach conducted in the present study. This approach is less time-consuming since it excludes the preprocessing that is required for binarization. It can be recommended that future studies on CBCT-based FD compare the values found in this study with healthy control individuals. FD values that represent bone complexity should be considered for differentiating men and women.

Another interesting approach for assessing bone organi-

zation is measuring the Lac index, which shows how pixels and voxels are spatially organized within an image.<sup>10</sup> Lac refers to the distribution and size of empty spaces on an image.<sup>9,10</sup> In this study, the Lac index was assessed using grayscale images without binarization, similar to how FD was measured. Lac was significantly different between men and women. The mean values were 0.15 and 0.12, respectively. Women presented larger void spaces in the mandibular trabecular bone than men. These results suggest that Lac can be used for sex determination. However, further studies should be carried out on other populations using the same preprocessing methods with grayscale images to ensure their reliability for sex determination.

In addition to FD and Lac, assessing the mandibular micro-architecture based on CBCT might be a good option for obtaining more data for sex determination. Nevertheless, the limitations of CBCT in analyzing the trabecular bone should be considered. Even if it has some limitations, Pauwels et al.<sup>30</sup> stated that parameters related to the trabecular bone structure are strongly affected by voxel size. Van Dessel et al.<sup>31</sup> demonstrated that most CBCT equipment could quantitatively assess alveolar bone quality with a level of accuracy and reliability approaching that of micro-computed tomography (CT). However, they reported that the tomography equipment used in this study (i-Cat Next Generation) overestimated bone quantity and presented a different structural pattern from the images obtained by other CBCT equipment. He et al.<sup>15</sup> evaluated several CBCT image post-processing protocols to approximate the results obtained by CBCT images with those of micro-CT. The authors concluded that post-processing approaches can be used to increase the effectiveness of CBCT when assessing trabecular bone parameters. However, regardless of the type of processing, the CBCT images yielded significantly different results from those measured on micro-CT images.

Anthropological analyses of human remains provide information for the reconstruction of the biological profile. These analyses comprise 4 major parameters: probable geographic origin (also known as ancestry or population affinity), sex, age at the time of death, and height. Generally, in sex determination, the options are male, female, or undefined (when the results are inconclusive).<sup>23</sup> Schmitt et al.<sup>32</sup> stated that sex determination is more problematic when the body is skeletonized than when the body still has soft tissues. Sex determination is conducted in the paleoanthropological and criminal investigation fields, which require a high level of reliability and face biological and methodological limitations. The reliability and accuracy of sex determination of human remains depend on the available

anatomical area and, most importantly, the integrity of the bones. Sex determination can be reliable, as it usually stems from observable features in the hip bones, skull, and long bones of the upper and lower limbs, if the bones are not fragmented.

It is important to develop and study methods that facilitate sex determination in different environments, with the available materials (in some cases, fragmented bones), either for research or professional purposes, at universities or by expert services. The present study presents a possible approach to sex determination through the assessment of FD, Lac, trabecular BV/TV, and cortical thickness in the mandible of healthy adults of different ages based on mandibular sections. These parameters can at least partially facilitate sex determination during the human identification process.

The major limitation of this study is that it was retrospective. Furthermore, FD was not assessed through binarization, although this is the most frequently used method in the literature. However, a simpler method, such as the one adopted in this study, would be less time-consuming and require fewer steps for image processing.

In conclusion, the mandible trabecular parameters of FD, Lac, and bone volume were different between healthy men and women from 20 to 60 years of age. Cortical thickness in the anterior mandible also revealed differences between males and females. Therefore, these parameters could be useful for sex determination based on an intact mandibular bone or its fragments.

**Conflicts of Interest:** None

## References

1. Seeman E. Pathogenesis of bone fragility in women and men. *Lancet* 2002; 359: 1841-50.
2. Mello-Gentil T, Souza-Mello V. Contributions of anatomy to forensic sex estimation: focus on head and neck bones. *Forensic Sci Res* 2021; 7: 11-23.
3. Spradley MK, Jantz RL. Sex estimation in forensic anthropology: skull versus postcranial elements. *J Forensic Sci* 2011; 56: 289-96.
4. Hazari P, Hazari RS, Mishra SK, Agrawal S, Yadav M. Is there enough evidence so that mandible can be used as a tool for sex dimorphism? A systematic review. *J Forensic Dent Sci* 2016; 8: 174.
5. Tunis TS, Sarig R, Cohen H, Medlej B, Peled N, May H. Sex estimation using computed tomography of the mandible. *Int J Legal Med* 2017; 131: 1691-700.
6. Sindaux R, Figueiredo PT, de Melo NS, Guimarães AT, Lazarte L, Pereira FB, et al. Fractal dimension and mandibular cortical width in normal and osteoporotic men and women. *Maturitas* 2014; 77: 142-8.

7. Kavitha MS, Park SY, Heo MS, Chien SI. Distributional variations in the quantitative cortical and trabecular bone radiographic measurements of mandible, between male and female populations of Korea, and its utilization. *PLoS One* 2016; 11: e0167992.
8. Scarfe WC, Farman AG, Sukovic P. Clinical applications of cone-beam computed tomography in dental practice. *J Can Dent Assoc* 2006; 72: 75-80.
9. Smith TG Jr, Lange GD, Marks WB. Fractal methods and results in cellular morphology - dimensions, lacunarity and multifractals. *J Neurosci Methods* 1996; 69: 123-36.
10. Irie MS, Rabelo GD, Spin-Neto R, Dechichi P, Borges JS, Soares PB. Use of micro-computed tomography for bone evaluation in dentistry. *Braz Dent J* 2018; 29: 227-38.
11. Alman AC, Johnson LR, Calverley DC, Grunwald GK, Lezotte DC, Hokanson JE. Diagnostic capabilities of fractal dimension and mandibular cortical width to identify men and women with decreased bone mineral density. *Osteoporos Int* 2012; 23: 1631-6.
12. Rabelo GD, Coutinho-Camillo C, Kowalski LP, Portero-Muzy N, Roux JP, Chavassieux P, et al. Evaluation of cortical mandibular bone in patients with oral squamous cell carcinoma. *Clin Oral Investig* 2018; 22: 783-90.
13. Kim JE, Yi WJ, Heo MS, Lee SS, Choi SC, Huh KH. Three-dimensional evaluation of human jaw bone microarchitecture: correlation between the microarchitectural parameters of cone beam computed tomography and micro-computer tomography. *Oral Surg Oral Med Oral Pathol Oral Radiol* 2015; 120: 762-70.
14. Panmekiate S, Ngonphloy N, Charoenkarn T, Faruangsang T, Pauwels R. Comparison of mandibular bone microarchitecture between micro-CT and CBCT images. *Dentomaxillofac Radiol* 2015; 44: 20140322.
15. He RT, Tu MG, Huang HL, Tsai MT, Wu J, Hsu JT. Improving the prediction of the trabecular bone microarchitectural parameters using dental cone-beam computed tomography. *BMC Med Imaging* 2019; 19: 10.
16. Karperien A. Welcome to the User's Guide for FracLac, V. 2.5 [Internet]. Bathurst: Charles Sturt University; 2007-2012 [cited 29 Jan 2023]. Available from: <http://rsb.info.nih.gov/ij/plugins/fraclac/FLHelp/Introduction.htm>.
17. da Silva ME, Dos Santos HS, Ruhland L, Rabelo GD, Badaró MM. Fractal analysis of dental periapical radiographs: a revised image processing method. *Oral Surg Oral Med Oral Pathol Oral Radiol* 2023; 135: 669-77.
18. Eastell R, O'Neill TW, Hofbauer LC, Langdahl B, Reid IR, Gold DT, et al. Postmenopausal osteoporosis. *Nat Rev Dis Primers* 2016; 2: 16069.
19. Nishiyama KK, Macdonald HM, Hanley DA, Boyd SK. Women with previous fragility fractures can be classified based on bone microarchitecture and finite element analysis measured with HR-pQCT. *Osteoporos Int* 2013; 24: 1733-40.
20. Blumer MJ. Bone tissue and histological and molecular events during development of the long bones. *Ann Anat* 2021; 235: 151704.
21. Jonasson G, Skoglund I, Rythén M. The rise and fall of the alveolar process: dependency of teeth and metabolic aspects. *Arch Oral Biol* 2018; 96: 195-200.
22. Almeida M, Laurent MR, Dubois V, Claessens F, O'Brien CA, Bouillon R, et al. Estrogens and androgens in skeletal physiology and pathophysiology. *Physiol Rev* 2017; 97: 135-87.
23. Li Y, Zhao H, Liang WB, Deng ZH, Zhang L. Research progress on computer-aided skeleton-based individual identification in forensic radiology. *Fa Yi Xue Za Zhi* 2021; 37: 239-47.
24. Indira AP, Markande A, David MP. Mandibular ramus: an indicator for sex determination - a digital radiographic study. *J Forensic Dent Sci* 2012; 4: 58-62.
25. Vinay G, Mangala Gowri SR, Anbalagan J. Sex determination of human mandible using metrical parameters. *J Clin Diagn Res* 2013; 7: 2671-3.
26. Franciotti R, Moharrami M, Quaranta A, Bizzoca ME, Piattelli A, Aprile G, et al. Use of fractal analysis in dental images for osteoporosis detection: a systematic review and meta-analysis. *Osteoporos Int* 2021; 32: 1041-52.
27. Gaalaas L, Henn L, Gaillard PR, Ahmad M, Islam MS. Analysis of trabecular bone using site-specific fractal values calculated from cone beam CT images. *Oral Radiol* 2014; 30: 179-85.
28. Ling H, Yang X, Li P, Megalooikonomou V, Xu Y, Yang J. Cross gender-age trabecular texture analysis in cone beam CT. *Dentomaxillofac Radiol* 2014; 43: 20130324.
29. Kato CN, Barra SG, Tavares NP, Amaral TM, Brasileiro CB, Mesquita RA, et al. Use of fractal analysis in dental images: a systematic review. *Dentomaxillofac Radiol* 2020; 49: 20180457.
30. Pauwels R, Faruangsang T, Charoenkarn T, Ngonphloy N, Panmekiate S. Effect of exposure parameters and voxel size on bone structure analysis in CBCT. *Dentomaxillofac Radiol* 2015; 44: 20150078.
31. Van Dessel J, Nicolielo LF, Huang Y, Coudyzer W, Salmon B, Lambrichts I, et al. Accuracy and reliability of different cone beam computed tomography (CBCT) devices for structural analysis of alveolar bone in comparison with multislice CT and micro-CT. *Eur J Oral Implantol* 2017; 10: 95-105.
32. Schmitt A, Cunha E, Pinheiro J. Forensic anthropology and medicine: complementary sciences from recovery to cause of death. Totowa, NJ: Humana; 2006.