

Available online at [www.sciencedirect.com](http://www.sciencedirect.com)

ScienceDirect

journal homepage: [www.elsevier.com/locate/radcr](http://www.elsevier.com/locate/radcr)

## Case Report

# Perihepatic abscesses caused by dropped appendicoliths in a child

Suprit C. Singh, BS<sup>a</sup>, Fabiola Weber, MD<sup>a,b</sup>, Arthur B. Meyers, MD<sup>a,b</sup>, Cynthia Reyes, MD<sup>c</sup>,  
Monica Epelman, MD<sup>a,b,\*</sup>

<sup>a</sup>University of Central Florida, College of Medicine, 6850 Lake Nona Blvd., Orlando, FL 32827, USA

<sup>b</sup>Department of Medical Imaging/Radiology, Nemours Children's Health System/Nemours Children's Hospital, 13535 Nemours Parkway, Orlando, FL 32827, USA

<sup>c</sup>Department of Pediatric Surgery, Nemours Children's Health System/Nemours Children's Hospital, 13535 Nemours Parkway, Orlando, FL 32827, USA

## ARTICLE INFO

## Article history:

Received 16 August 2018

Revised 1 September 2018

Accepted 3 September 2018

Available online 1 October 2018

## Keywords:

Appendicitis

CT

Dropped appendicolith

Abscess

## ABSTRACT

A dropped appendicolith is a well-known complication of laparoscopic appendectomy that may occur because of stone expulsion from the appendix, before or during surgery, and typically manifests as a focal, subcentimeter area of high attenuation with or without associated abscess. Dropped appendicoliths may act as niduses for infection and may result in the future development of abscess formation. We report the case of a 10-year-old pediatric patient who developed 2 perihepatic abscesses caused by 2 appendicoliths that were inadvertently dropped during laparoscopic surgery.

© 2018 The Authors. Published by Elsevier Inc. on behalf of University of Washington.

This is an open access article under the CC BY-NC-ND license.

(<http://creativecommons.org/licenses/by-nc-nd/4.0/>)

## Introduction

Acute appendicitis is a pediatric surgical emergency with a lifetime risk of 9% in males and 7% percent in females [1]. Laparoscopic appendectomy is gaining broader acceptance and is currently the treatment of choice for acute appendicitis in many institutions in North America [2]. When compared to open appendectomy, laparoscopic appendectomy is superior with regard to incidence of readmission, reoperation, and wound infection [3]. Retained or dropped appendicoliths are

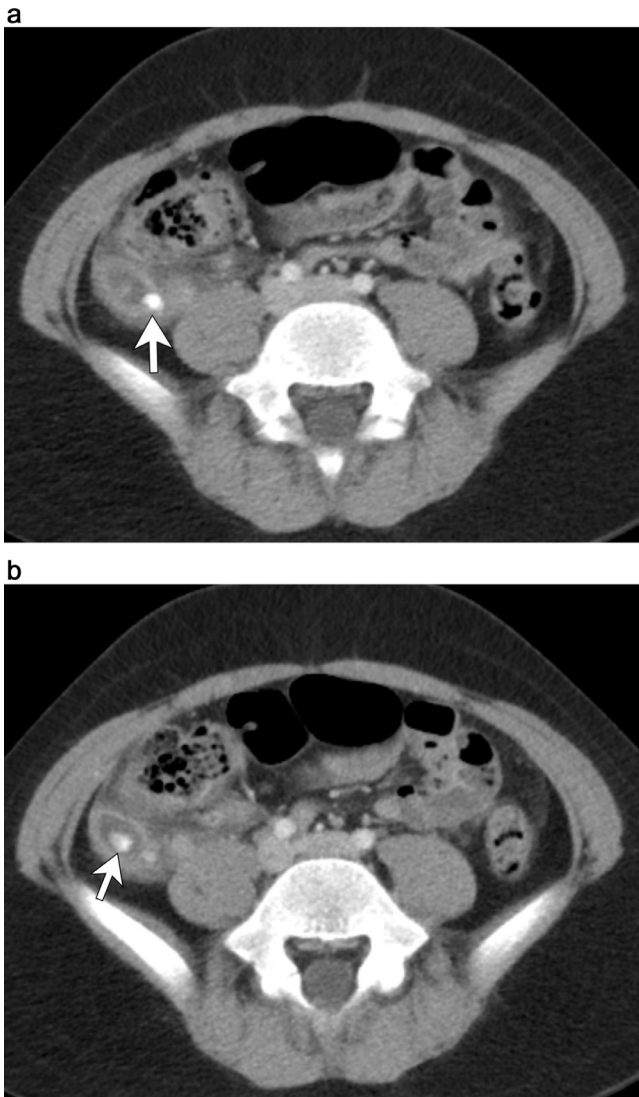
an uncommon complication that may occur as a consequence of stone expulsion from the appendix, before or during laparoscopic appendectomies, and typically manifest as a focal, subcentimeter area of high attenuation with or without an associated abscess close to the cecum or Morison's pouch [4]. However, only a handful of cases of perihepatic abscess formation as a result of dropped appendicoliths have been reported [5–9]. To the best of our knowledge, this is the first reported case with 2 concomitant perihepatic abscesses in a pediatric patient.

\* Corresponding author.

E-mail address: [mepelman@nemours.org](mailto:mepelman@nemours.org) (M. Epelman).

<https://doi.org/10.1016/j.radcr.2018.09.003>

1930-0433/© 2018 The Authors. Published by Elsevier Inc. on behalf of University of Washington. This is an open access article under the CC BY-NC-ND license. (<http://creativecommons.org/licenses/by-nc-nd/4.0/>)



**Fig. 1 – A 10-year-old boy with acute appendicitis. a, b. Initial, contrast-enhanced axial CT images of the pelvis demonstrate 2 calcified appendicoliths (arrows) within an enlarged, fluid-filled appendix with surrounding inflammatory changes.**

## Case report

A 10-year-old male presented to the emergency department as a transfer patient with moderate right lower quadrant (RLQ) tenderness, abdominal pain with no associated nausea or vomiting for 4 days. On examination, he was in acute distress, tachycardic, tachypneic, and there was guarding of the RLQ of the abdomen. Blood tests revealed elevation of the white blood cell count. A contrast-enhanced CT scan of the abdomen and pelvis was performed and confirmed the diagnosis of acute appendicitis (Fig. 1). CT showed inflammatory changes in the RLQ in association to a dilated and fluid-filled appendix. Two appendicoliths were present within the appendix with the appendix measuring up to 13 mm in diameter. A small amount

of free fluid was noted in the pelvis, but no free air or drainable collection was present. Reactive lymph nodes were found in the RLQ.

This patient was then referred for laparoscopic appendectomy. During his appendectomy, the appendix was found to be gangrenous and necrotic as well as densely adherent to the cecum. The appendix broke into 2 pieces during the procedure, and the 2 appendicoliths were not recovered during the initial surgery. No complications were reported perioperatively. He was subsequently discharged the next day.

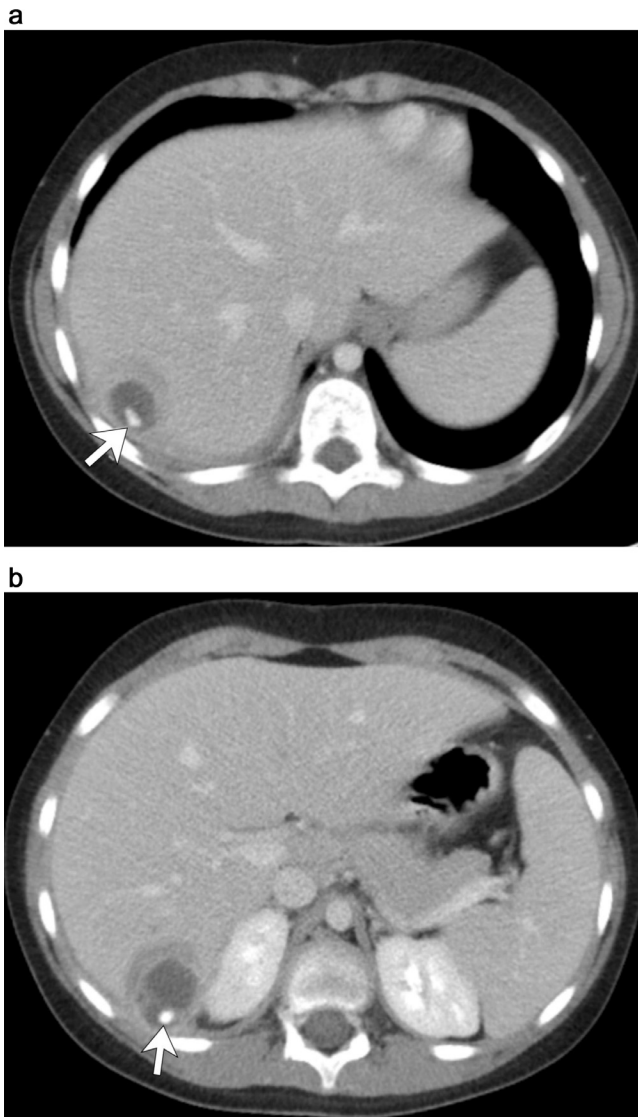
Three days after surgery, he complained of centralized abdominal pain with slight pyrexia (37.5°C), tachypnea, and tachycardia, which resolved over the next few days.

On postop day 18, he began to have a fever of 39.4°C, elevated white blood cell count, and worsening abdominal pain localized to the right upper quadrant. Temperatures spiked to 40.5°C during hospital admission. The region of pain was under the costal margin in the anterolateral and flank area. He also experienced nausea and vomiting. On physical examination, he was slightly tachycardic and tachypneic. Laboratory values revealed leukocytosis, neutrophilia, and elevated absolute neutrophil count. Contrast-enhanced CT imaging of the abdomen and pelvis revealed 2 small, complex fluid collections measuring approximately 3 cm in diameter in the periphery of the posterior right hepatic lobe with surrounding inflammatory changes. Calcified foci in dependent position were noted within these collections corresponding to the dropped appendicoliths (Fig. 2). There was a minimal amount of perihepatic free fluid. The patient was started on IV antibiotics and underwent diagnostic laparoscopy for appendicolith removal and drainage of the perihepatic abscesses. Drainage of the abscesses was successful but only one of the 2 appendicoliths was successfully removed. The second appendicolith could not be found, despite various documented attempts.

Postoperative, repeat contrast-enhanced CT and ultrasound studies of the abdomen (Fig. 3) confirmed the presence of the retained appendicolith. An additional laparoscopic surgery, which included an ultrasound-guided incision was performed for successful removal of the second retained appendicolith (Fig. 4). After this procedure, the patient remained in the hospital until postop day #8. He was then discharged and after 2 months from his initial appendicitis, he was able to return to normal activity with no further complications.

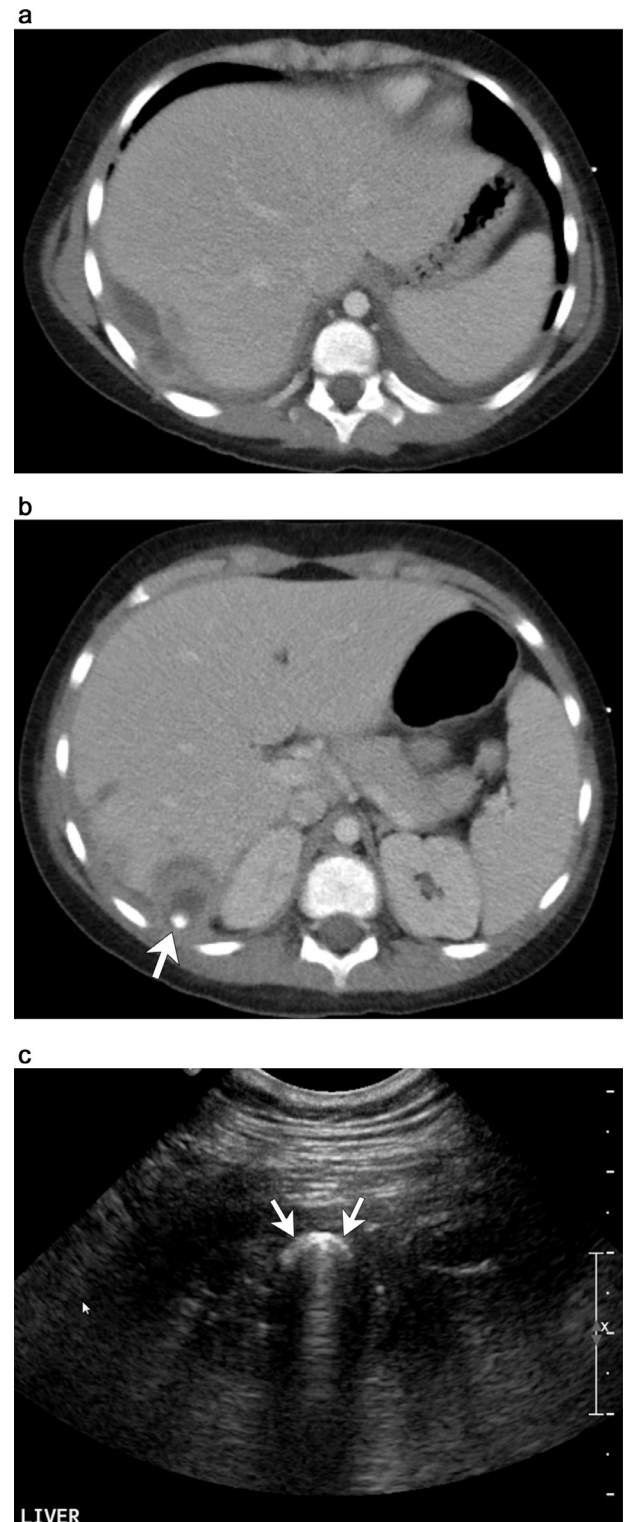
## Discussion

Laparoscopic surgery for appendicitis is a minimally invasive technique resulting in quicker recovery times, fewer wound complications and less pain when compared to open appendectomy [3,10]. Comparatively, laparoscopic surgery and open appendectomy have similar rates for postoperative intraabdominal abscess [3]. Dropped or retained appendicoliths are a well-known complication of laparoscopic appendectomy [10,11]. The incidence of appendicoliths in pediatric patients is higher than that of the adult, and appendicoliths may be found in as many as 50% of appendectomy specimens [10]. Calcified appendicoliths may be seen in imaging studies in up to 30% of the cases of acute appendicitis [12]. Recognition of

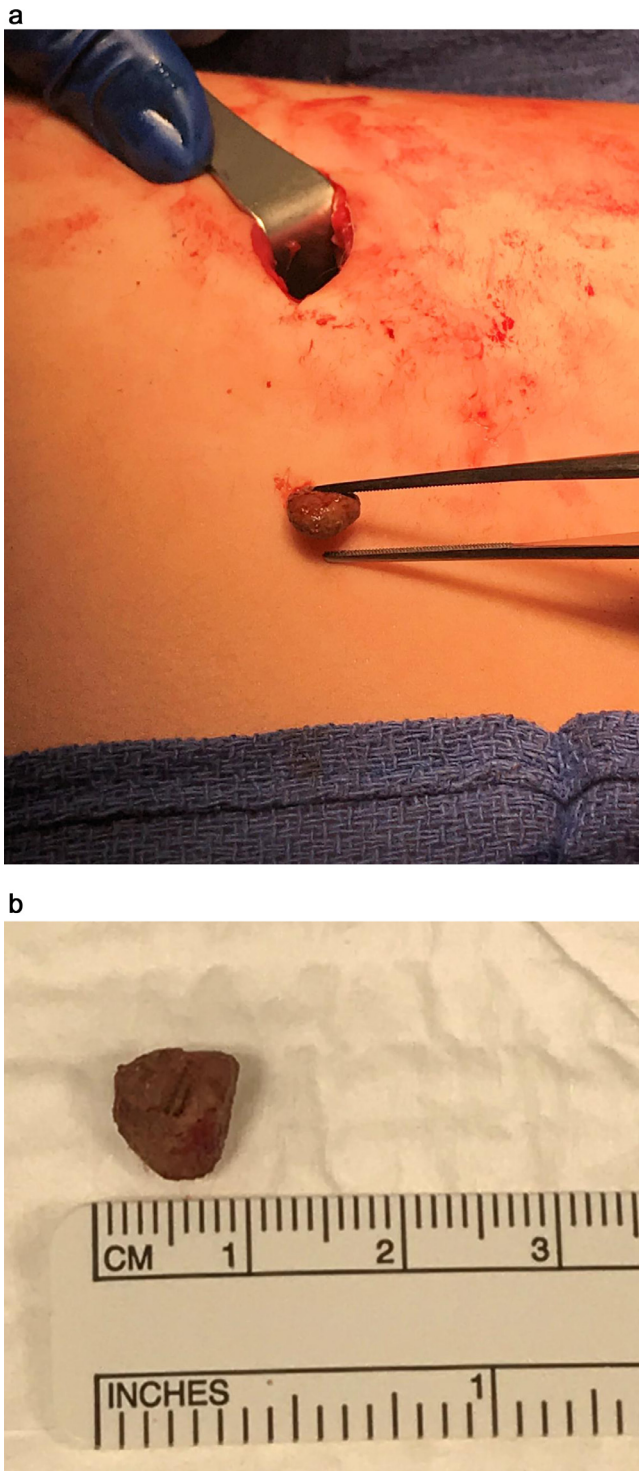


**Fig. 2** – Repeat contrast-enhanced CT images of the abdomen obtained 18 days later at readmission. (a) Axial CT image shows a complex collection in the periphery of the right hepatic lobe containing a focal calcification in dependent position representing the “dropped” appendicolith (arrow). (b) Axial CT image obtained at a lower level than b shows an additional complex collection with a dropped appendicolith (arrow) in dependent location.

dropped appendicoliths is important, as these may act as a nidus for infection and result in the subsequent development of abscesses at the site of the dropped appendicolith at a later stage. The appendicoliths usually drop in the pouch of Douglas or retrovesical space [11]. However, in some cases, the appendicoliths may migrate to less common places, such as in our case. There can be up to a 10-year interval from the index operation to the clinical manifestations of the retained appendicoliths [13]. Due to the high risk of infection and potential for subsequent abscess formation, every effort should be made to remove the appendicoliths at the index operation [9].



**Fig. 3** – Additional CT and US studies performed after failure to retrieve one of the appendicoliths. (a) Axial CT image corresponding to the level of Figure 2a, shows expected postoperative seroma and no retained appendicolith. (b) Axial CT image corresponding to the level of Figure 2b redemonstrates a smaller fluid collection with a retained appendicolith (arrow). (c) US image of the right flank shows a hypoechoic perihepatic abscess containing a calcified focus with posterior acoustic shadowing representing the retained appendicolith (arrow).



**Fig. 4 – (a, b) Photographs of the removed appendicolith.**

Conservative management of perihepatic abscesses with antibiotics has been described for relatively smaller sized abscesses [5]. However, image-guided therapy is usually preferred for larger sized abscesses to avoid subsequent sepsis [7]. In the case of our patient, 2 perihepatic abscesses were discovered surrounding the dropped appendicoliths. However, only 1 appendicolith could be removed through laparoscopic surgery. The patient needed to undergo an additional surgical proce-

dure to retrieve the second retained appendicolith, which was eventually successfully retrieved under ultrasound guidance.

From a radiologic perspective this case illustrates a number of important points regarding dropped appendicoliths. First, radiologists reporting acute appendicitis should describe the presence, number and size of appendicoliths, so that if there is appendiceal rupture prior to or during surgery the surgeon can make an attempt to remove them and avoid possible complications. Also given that patients may present for imaging at a time remote from their initial surgery [13], radiologists need to be aware of and consider the diagnosis in patients with a prior history of appendicitis. There are cases in the medical literature of late presentations of dropped appendicoliths and dropped gallstones, which can have an identical appearance, being misdiagnosed as both inflammatory and metastatic conditions on CT [14,15]. Lastly, this case demonstrates the usefulness of intraoperative ultrasound in the retrieval of these stones, which is of particular importance because if the appendicolith is left after abscess drainage, the abscess will likely recur.

## Conclusion

Dropped appendicolith migration with the formation of perihepatic abscess is highly unusual. This 10-year-old pediatric patient had 2 concomitant perihepatic abscesses from dropped appendicoliths after laparoscopic surgery. To the best of our knowledge, no such case has been previously reported in the literature. Awareness of the imaging findings of this complication will aid better surgical planning and management and avoid misdiagnosis.

## Supplementary materials

Supplementary material associated with this article can be found, in the online version, at [doi:10.1016/j.radcr.2018.09.003](https://doi.org/10.1016/j.radcr.2018.09.003).

## REFERENCES

- [1] Addiss DG, Shaffer N, Fowler BS, Tauxe RV. The epidemiology of appendicitis and appendectomy in the United States. *Am J Epidemiol* 1990;132:910–25.
- [2] Masoomi H, Nguyen NT, Dolich MO, Mills S, Carmichael JC, Stamos MJ. Laparoscopic appendectomy trends and outcomes in the United States: data from the Nationwide Inpatient Sample (NIS), 2004–2011. *Am Surgeon* 2014;80:1074–7.
- [3] Vahdad MR, Troebs RB, Nissen M, Burkhardt LB, Hardwig S, Cernaianu G. Laparoscopic appendectomy for perforated appendicitis in children has complication rates comparable with those of open appendectomy. *J Pediatr Surg* 2013;48:555–61.
- [4] Singh AK, Levenson RB, Gervais DA, Hahn PF, Kandarpa K, Mueller PR. Dropped gallstones and surgical clips after cholecystectomy: CT assessment. *J Comput Assisted Tomography* 2007;31:758–62.

- 
- [5] Black MT, Ha BY, Kang YS, Garland AM. Perihepatic abscess caused by dropped appendicoliths following laparoscopic appendectomy: sonographic findings. *J Clin Ultrasound* 2013;41:366–9.
- [6] Maatouk M, Bunni J, Schuijtvlot M. Perihepatic abscess secondary to retained appendicolith: a rare complication managed laparoscopically. *J Surgical Case Rep* 2011;2011:6.
- [7] Muyltermans K, Brussaard C, Willekens I, de Mey J. Liver abscess due to dropped appendicolith after laparoscopic appendectomy. *J Belgian Soc Radiol* 2015;99:47–9.
- [8] Lambo A, Nchimi A, Khamis J, Khuc T. Retroperitoneal abscess from dropped appendicolith complicating laparoscopic appendectomy. *Eur J Pediatr Surg: Off J Austrian Assoc Pediatr Surgery [et al] = Z Kinderchir* 2007;17:139–41.
- [9] Whalley HJ, Remoundos DD, Webster J, Silva MA. Shortness of breath, fever and abdominal pain in a 21-year-old student; 2013. *BMJ Case Rep* 2013.
- [10] Buckley O, Geoghegan T, Ridgeway P, Colhoun E, Snow A, Torreggiani WC. Imaging of appendicoliths dropped at laparoscopic appendectomy and their complications. *Can Assoc Radiol J = J Assoc Canadienne Radiol* 2007;58:146–51.
- [11] Singh AK, Hahn PF, Gervais D, Vijayraghavan G, Mueller PR. Dropped appendicolith: CT findings and implications for management. *AJR Am J Roentgenol* 2008;190:707–11.
- [12] Parks NA, Schroepfel TJ. Update on imaging for acute appendicitis. *Surg Clin N Am* 2011;91:141–54.
- [13] Sade RM. Very late wound infection due to retained fecalith. *Arch Surg* 1970;101:624–5.
- [14] Sarkar S, Douglas L, Egun AA. A complication of a dropped appendicolith misdiagnosed as Crohn's disease. *Ann R Coll Surg England* 2011;93:e117–18.
- [15] Karabulut N, Tavasli B, Kiroglu Y. Intra-abdominal spilled gallstones simulating peritoneal metastasis: CT and MR imaging features (2008: 1b). *Eur Radiol* 2008;18:851–4.