

Clinical and Electroretinographic Findings of Progressive Retinal Atrophy in Miniature Schnauzer Dogs of South Korea

Man Bok JEONG^{1)**}, Shin Ae PARK^{1)***}, Se Eun KIM¹⁾, Young Woo PARK¹⁾, Kristina NARFSTRÖM²⁾ and Kangmoon SEO^{1)*}

¹⁾Department of Veterinary Clinical Sciences, College of Veterinary Medicine and BK21 Program for Veterinary Science, Seoul National University, 599 Gwanak-ro, Gwanak-gu, Seoul 151-742, Republic of Korea

²⁾Department of Veterinary Medicine and Surgery, College of Veterinary Medicine, University of Missouri-Columbia, Columbia, MO 65211, U.S.A

(Received 10 August 2012/Accepted 15 May 2013/Published online in J-STAGE 30 May 2013)

ABSTRACT. The purpose of the study was to describe the clinical and electroretinographic features of clinical cases of progressive retinal atrophy (PRA) in miniature schnauzer (MS) of South Korea. Sixty-six MS (14 normal and 52 affected) were included. All animals underwent routine ocular examinations. Electroretinogram (ERG) was recorded in the 14 normal and 15 affected dogs. For normal dogs, the mean age \pm SD was 4.1 ± 2.4 years (1 to 9 years), and there were no ocular abnormalities on the basis of ocular examinations and ERG results. For the PRA-affected dogs, it was shown that the mean age \pm SD was 4.3 ± 1.1 years (2 to 7 years), and 44 dogs (84.6%) were 3 to 5 years old. Most of the PRA-affected dogs had abnormal menace responses (98.1%) and pupillary light reflexes (PLRs, 88.5%); some dogs showed normal menace response (1.9%) and PLRs (11.5%). Ophthalmoscopic abnormalities in the affected group included one or more of the following changes: hyperreflectivity and discoloration of the tapetal area, attenuation of retinal vessels, depigmentation in non-tapetal area and optic disc atrophy. ERG in the affected dogs showed non-recordable responses in all cases tested with clinical signs of PRA. The present study showed that PRA in MS was mainly observed between the age of 3 to 5 years. ERG revealed abnormal rod and cone responses in affected dogs at the ages studied.

KEY WORDS: canine, electroretinography, miniature schnauzer, progressive retinal atrophy.

doi: 10.1292/jvms.12-0358; *J. Vet. Med. Sci.* 75(10): 1303–1308, 2013

Canine progressive retinal atrophy (PRA) is a group of inherited retinal diseases that have similar disease phenotypes in both eyes and that primarily affect the photoreceptors, the rods and the cones. Affected dogs typically reveal initial night blindness due to degeneration of rod cells with progression of disease with loss of day vision caused by degeneration of cone cells, leading to complete blindness. PRA is very similar to retinitis pigmentosa (RP) of humans, which could render dogs with specific types of PRA animal models for RP [17].

PRA may be classified into two groups mainly by the age of onset and by the rate of progression of clinical signs in different breeds [17]. One group is the early-onset, photoreceptor dysplasia, which affects photoreceptors before they are fully mature and rapidly leads to progressive retinal

degeneration; while, the other group is the late-onset photoreceptor degeneration, which occurs after normal retinal development, then followed by generalized photoreceptor degeneration [21]. Approximately, 108 canine breeds are currently on the list for potentially being affected by PRA [24]. The former PRA group includes: Irish setters, collies, Cardigan Welsh corgis, Norwegian elkhounds and MS, and the latter includes: toy and miniature poodles, Labrador retrievers, American cocker spaniels and English cocker spaniels.

It has been shown that different types of PRA may affect the same breed, due to mutations in more than one gene or more than one mutation in a specific gene. Examples of different retinal diseases in the same breed include Norwegian elkhounds suffering from rod dysplasia and early rod degeneration [1, 3]. Although the species is different, there are two types of PRA in the Abyssinian cats: one is an autosomal dominant rod-cone dysplasia and the other an autosomal recessive rod-cone degeneration [7, 16]. There have been several reports in regards to PRA in MS. Two previous reports, including histopathologic, electroretinographic, breeding and pedigree studies, were published in regard to MS with PRA in U.S.A. [2, 20]. The gene symbol (*pd*) was assigned for the photoreceptor dysplasia described. The disease also occurred in U.K. as a result of matings between carrier dogs imported from U.S.A. [21]. The ocular problems were characterized as PRA [4]. More recently, a study regarding PRA in the MS was reported in South Korea [13]. It was shown that the putative *phosducin* mutation in American MS would

*CORRESPONDENCE TO: SEO, K., Department of Veterinary Clinical Sciences, College of Veterinary Medicine and BK21 Program for Veterinary Science, Seoul National University, 599 Gwanak-ro, Gwanak-gu, Seoul 151-742, Republic of Korea.
e-mail: kmseo@snu.ac.kr

**PRESENT ADDRESS: Department of Veterinary Clinical Sciences, College of Veterinary Medicine, Iowa State University, 1600 South 16th Street, Ames, IA 50011, U.S.A.

***PRESENT ADDRESS: Department of Surgical and Radiological Sciences, School of Veterinary Medicine, One Shields Ave, University of California Davis, Davis, California 95616, U.S.A.

not be related to MS with PRA from South Korea. Further, the variation in molecular genetic studies in affected dogs from South Korea allowed us to speculate that this type of PRA was different from the types described in U.S.A.

In order to establish criteria for early diagnosis of the inherited retinal diseases and to develop a scheme for the eradication of the disease, it appears necessary to characterize the disorder in each specific breed and country. The purpose of the present study was to investigate clinical and ERG features of the retina in normal and PRA-affected MS in South Korea.

MATERIALS AND METHODS

Experimental animals: A total of 66 MS were included in the present study. Fifty-two of these were brought for examination, because the owner suspected visual impairment, and were diagnosed with PRA at the Veterinary Medical Teaching Hospital, Seoul National University, South Korea, from January 2006 to December 2010. It was considered important to exclude sudden acquired retinal degeneration from the groups. Therefore, medical records were studied, and cases with a history of acute blindness, polyphagia, polydipsia and weight gain were excluded from the study. Fourteen normal MS were presented by their owners for ocular examination in order to exclude PRA before breeding and were selected to be included in the present study to compare retinal function between normal and PRA-affected MS using ERG. The normal MS dogs were divided into 3 age groups for description of normal ERG data: ≤ 2 , 3 to 5 and 6 to 9 years by the retinal maturity and evidence of nuclear sclerosis in dogs [22, 23].

Clinical evaluation: All animals included underwent ocular examinations to diagnose and/or confirm ocular disease. Menace responses were evaluated by making a threatening gesture with a hand toward the eye, taking care not to touch the vibrissae or cause air currents. Results of the test were divided into a normal blink, delayed and a non-blink response. Pupillary light reflexes (PLRs) were evaluated subjectively by using a focal light source (Heine 6-21-301[®], Heine, Berlin, Germany) under scotopic conditions. The results of the test were divided into normal, delayed and dilated/fixed PLRs. Intraocular pressure (IOP) was measured to differentiate PRA from retinal degeneration due to glaucoma using a tonometer (TonoPen XL[®], Mentor, Norwell, MA, U.S.A.). The anterior segments were examined using a slit lamp biomicroscope (SL-202P[®], Shin-nippon commerce, Tokyo, Japan), 20 min after instillation of tropicamide (Mydracil[®], Alcon Inc., Puurs, Belgium), followed by fundus examination, using an indirect ophthalmoscope (Vantage[®], Keeler instruments Inc., Broomall, PA, U.S.A.). Fundus photographs were taken using a fundus camera (Kowa Hand-held Fundus Camera[®], GENESIS[™], Kowa Co., Tokyo, Japan) more than 1 hr prior to the ERG. The diagnosis of PRA was based on the ophthalmoscopic findings and the results of ERG recordings.

Preparation of animals for ERG: Fifteen MS with visual impairment or blindness and 14 normal MS underwent ERG

(RETIport[®], Roland Consult, Brandenburg, Germany) examination after permission by the owner. All animals were fasted for at least 12 hr prior to performing the ERG recordings. Maximal pupillary dilation was obtained by applying 1 drop of 1% tropicamide (Mydracil[®], Alcon Inc.) to the test eye every 30 min from at least 1 hr prior to beginning the ERG session. The canine protocol endorsed by the European College of Veterinary Ophthalmologists was utilized for 28 dogs (14 normal MS and 14 PRA-affected MS) all under general anesthesia [18].

The dogs were premedicated with atropine sulfate (Je-II atropine sulfate[®], Je-II pharmacy, Daegu, Korea) administered subcutaneously at the dose of 0.04 mg/kg. Xylazine (Rompun[®], Bayer Korea, Ansan, Korea) was administered intramuscularly using a sedative dose of 2.0 mg/kg. The dogs were kept in a cage in a silent area under ambient light for approximately 10 min. Generalized anesthesia was induced with ketamine (Yuhan Ketamine[®], Yuhan Corporation, Gunpo, Korea) injected intramuscularly at the dose of 10 mg/kg. After induction of anesthesia, the dogs were positioned on their sternal recumbency throughout the recordings and the head positioned using packs of towels for the ERG recordings.

ERG procedures: ERGs were recorded from the left eye of each dog using the ERG system. Platinum subdermal needle electrodes (Model F-E2[®], Grass Instrument Division, Astro-Med. Inc., West Warwick, RI, U.S.A.) were used to record the ERG; a reference electrode and a ground electrode were placed approximately 2 cm caudal to the lateral canthus of the tested eye and over the external occipital protuberance, respectively. The cornea was anesthetized by topical 0.5% proparacaine hydrochloride (Alcaine[®], Alcon Inc.). A contact lens electrode with built-in white light-emitting diodes (LED, Kooijman/Damhof ERG lens[®], Medical Workshop BV, Groningen, Netherland) was placed on the cornea after application of 0.3% hydroxypropyl methylcellulose (Artear[®], Unimed pharm., Seoul, Korea). A piece of tape was used to keep the contact lens in a correct and stable position on the eye during the recordings. The electrodes were connected to a preamplifier, and signals were amplified with a band pass filter between 1 and 300 Hz. All lights in the examining room were turned off at the initiation of the ERG test.

For the dog protocol, the built-in white LED with a contact lens electrode for the ERG system used in the study delivered white flashes of light 1 cm from the cornea. Signal averaging of ERG responses was not performed. Each ERG session consisted of scotopic and photopic ERGs. Two different responses were evaluated for scotopic ERGs: rod (R) response with scotopic low intensity stimuli (0.025 cd·sec/m²) and standard mixed rod and cone (MRC) responses using scotopic standard intensity (2.5 cd·sec/m²). The R responses were designated R1, R5, R10, R15 and R20 elicited 1, 5, 10, 15 and 20 min after the initiation of dark adaptation, respectively. For the evaluation of the cone system, photopic ERGs were performed with 2 different stimuli after 10 min of light adaptation (background luminance: 25 cd/m²): pure cone (C) responses using photopic single flash and 31 Hz cone

flicker (CF) responses from cones and cone pathways with 2.5 cd·sec/m² flash under the same background luminance. The CF responses lasted for 300 msec and recorded 9 flashes for each dog tested.

ERG evaluation: The amplitude and implicit time were measured for each a- and b-wave ERG component. The a-wave amplitude was measured from the baseline to the first negative peak, and the b-wave amplitude was measured from the negative peak of the a-wave to the following positive peak. Implicit times for a- and b-waves were measured from the onset of light stimulus to the peak of these a- and b-waves, respectively. For the R responses and CF response, only b-waves were obtained and analyzed. Amplitudes of CF responses were measured from the baseline to the positive peak and implicit times from the light onset to the positive peak.

Statistical analysis: Data were analyzed using a commercial statistical package (SPSS for Windows version 12.0, SPSS Inc., Chicago, IL, U.S.A.). Descriptive statistics were reported as mean and standard deviation (SD) for age, and median and range of the 5th and the 95th percentiles for the ERG data to avoid errors by non-normal distribution of data of small sample size [18].

RESULTS

Clinical findings: For normal dogs, the mean age \pm SD was 4.1 \pm 2.4 years (1 to 9 years of age), and there were no ocular abnormalities on the basis of ocular examination.

Table 1. Age distribution in PRA-affected dogs

Age (years)	2	3	4	5	6	7	Total
Number of dogs	2	7	24	13	3	3	52

Six intact females, 4 male neutered and 4 male dogs were included. Menace responses and PLRs were normal in all of these dogs. The mean age \pm SD of dogs with PRA was 4.3 \pm 1.1 years (2 to 7 years of age) at the first presentation for examination; but 44 of 52 dogs with PRA (84.6%) were 3 to 5 years of age (Table 1). The median period between onset and the diagnosis of PRA was 2 months ranging from 0.5 to 24 months in 48 dogs affected. Seven spayed female, 26 female, 11 male neutered and 8 male dogs were examined. All of the dogs diagnosed with PRA showed normal blink (n=1, 1.9%), delayed (n=7, 13.5%) or non-blink (n=44, 84.6%) menace responses. There were no differences in PLRs between left and right eye. They displayed normal (n=6, 11.5%), delayed (n=21, 40.4%) or dilated/fixed (n=25, 48.1%) direct and indirect PLRs (Table 2). There were no abnormalities in the anterior segment or IOP readings in any of the dogs examined. Of the 52 dogs with PRA, posterior subcapsular incipient cataract and incipient nuclear cataract were identified in 3 dogs (2 dogs aged 6 years and 1 dog aged 7 years) and 1 dog aged 4 years, respectively, at the initial presentation. The fundi in all cases with the secondary cataract could be observed.

For the normal dogs, the ophthalmoscopic examination showed normal reflectivity of the tapetal region, normal vascular size and normal coloration of the tapetal fundus. Ophthalmoscopic changes noted in the PRA-affected MS included one or more of the following changes: diffuse hyperreflectivity of the tapetal area (n=52, 100.0%), moderate or severe attenuation of major venules and arterioles (n=52, 100.0%), severe tan-brown discoloration of the tapetal fundus (n=8, 15.4%), depigmentation in non-tapetal area (n=7, 13.5%) and optic disc atrophy (n=9, 17.3%) (Table 3, Fig. 1). The signs of retinal degeneration were symmetrical for both eyes in each dog, and the severity of the ophthalmoscopic fundus abnormalities was somewhat variable among the affected dogs.

Table 2. Results of menace responses and pupillary light reflexes in PRA-affected dogs (n=52)

Age (years)	Menace response			Direct and indirect pupillary light reflexes		
	Normal blink	Delayed	Non-blink	Normal reflex	Delayed	Dilated/fixed
2 (n=2)	0	0	2	0	0	2
3-5 (n=44)	1	7	36	5 ^{a)}	20 ^{b)}	19 ^{c)}
6-7 (n=6)	0	0	6	1	1	4
Total	1	7	44	6	21	25

a) Consisted of 1 delayed and 4 non-blink menace responses; b) 1 normal, 5 delayed and 14 non-blink menace responses; and c) 1 delayed and 18 non-blink menace responses.

Table 3. Ophthalmoscopic findings in PRA-affected dogs at the first presentation (n=52)

Ophthalmoscopic findings	Number of dogs (%)
Diffuse hyperreflectivity in the tapetal area	52 (100.0%)
Attenuation of major venules and arterioles	52 (100.0%)
Severe tan-brown discoloration in the tapetal fundus	8 (15.4%)
Depigmentation in non-tapetal area	7 (13.5%)
Optic disc atrophy	9 (17.3%)

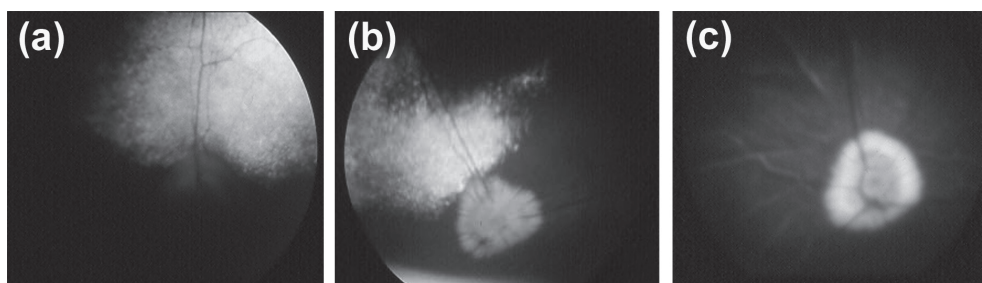


Fig. 1. Fundus photographs of PRA-affected miniature schnauzers at 2 years (a), 4 years (b) and 6 years (c) of age. The fundus abnormalities observed in the affected dogs are: diffuse hyperreflectivity (in a and b) and severe vascular attenuation (in a, b and c).

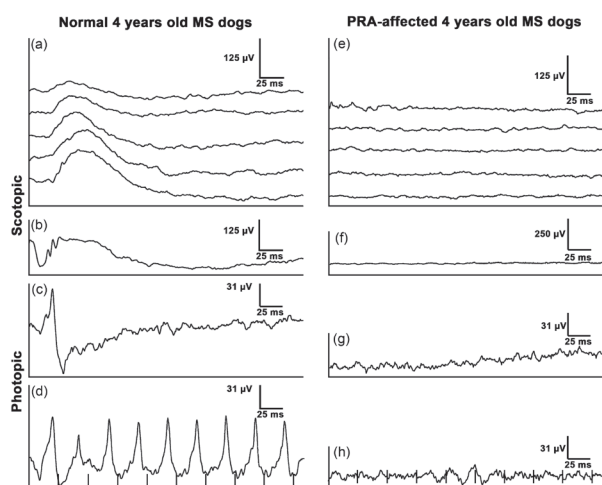


Fig. 2. Representative ERG waveforms recorded using the dog protocol in 4 years old normal and PRA-affected MS. The waveforms of each column were obtained from same MS dogs. Scotopic ERGs (a and b, e and f) and photopic ERGs (c and d, g and h) are shown. R responses ($0.025 \text{ cd}\cdot\text{sec}/\text{m}^2$, a and e), were designated R1 (1 min), R5 (5 min), R10 (10 min), R15 (15 min) and R20 (20 min) after the initiation of dark adaptation (from top to bottom in a and e), and MRC responses ($2.5 \text{ cd}\cdot\text{sec}/\text{m}^2$, b and f). The C responses ($2.5 \text{ cd}\cdot\text{sec}/\text{m}^2$, c and g) and CF responses ($2.5 \text{ cd}\cdot\text{sec}/\text{m}^2$, d and h) were obtained after 10 min of light adaptation using $25 \text{ cd}/\text{m}^2$ of background light. The light stimulus coincides with the y-axis of each recording. Please note that the time scale varies between some of the photopic recordings.

Electroretinography: Figure 2 displays examples of typical normal and non-recordable ERG responses obtained from two 4-year-old normal MS dogs and PRA-affected MS, respectively, for the scotopic and photopic ERGs. For the ERG waveforms of normal MS, the R responses had a prominent b-wave that increased in amplitude and in implicit time during the 20-min of dark adaptation. The a-wave was not recordable using this low light intensity. The MRC responses had prominent a- and b-waves, and oscillatory potentials were observed during the ascending phase of the b-wave for

the normal dogs. The C response had a smaller but faster b-wave than that of the R response, and the CF responses consisted of b-waves only. The ERG data with age-related change of normal MS dogs were shown (Table 4). For the ERG recordings of PRA-affected MS tested, all ERG responses were non-recordable in all of the PRA-affected dogs for all light intensities used.

DISCUSSION

Canine PRA is a group of inherited retinal diseases with genetic heterogeneity in different breeds and even within breeds [17]. This study was performed to investigate the clinical and electroretinographic features of the retina in normal MS dogs and in groups of MS diagnosed with PRA in South Korea. The PRA in MS dogs of South Korea was associated with visual impairment up to the age of 7 years and was mostly observed at the age of 3 to 5 years in the present study. This result may be caused by the comparatively small group of imported dogs used for breeding purposes, and further inbreeding's performed, including parent and offspring matings. Clinical and ERG findings from the present study are comparable with the clinical findings of PRA cases reported in the breed mainly in U.S.A. [2, 20].

Previous investigations in the breed including histopathologic and electroretinographic findings showed that the type of PRA found was an early-onset disorder [20]. Functional and morphologic abnormalities were shown to be evident at an age when the normal retina is approaching the end of post-natal differentiation. Therefore, the disease was described as a photoreceptor dysplasia (*pd*), because it affects both rod and cone photoreceptors, and well before the time of retinal maturation. The MS previously studied were night blind and had compromised day vision by 3 years of age. The blindness observed in affected MS by the previous investigators did not develop until after 4 to 5 years of age. There was no evidence for any sex predilection for the disease [2, 20]. In the present study, the age range of dog with PRA was 2 to 7 years, with a mean age \pm SD was 4.3 ± 1.1 years; 44 of 52 dogs with PRA (84.6%) were 3 to 5 years of age.

The present study showed that there was a presence of the menace responses and PLRs in some dogs suffering from visual impairment due to PRA. Comparison of both

Table 4. Median and 5th and 95th percentiles of amplitude (μV) and implicit time (msec) of a-and b-waves by dog protocol in normal MS dogs (n=14)

Response	Wave	≤ 2 years (n=2)		3–5 years (n=9)		6–9 years (n=3)	
		Amplitude	Implicit time	Amplitude	Implicit time	Amplitude	Implicit time
R1	b	62.8 (59.9–65.6)	45.5 (38.8–52.3)	49.8 (25.6–70.5)	43.0 (41.0–57.2)	50.3 (39.8–65.9)	46.0 (40.6–50.5)
R 5	b	81.3 (46.4–116.1)	47.0 (42.5–51.5)	86.9 (38.0–126.0)	54.0 (39.6–63.6)	84.0 (43.1–88.9)	51.0 (46.5–64.5)
R 10	b	135.5 (110.8–160.3)	55.0 (50.5–59.5)	134.0 (62.4–163.4)	55.0 (48.8–67.8)	106.0 (73.0–113.2)	61.0 (52.0–71.8)
R 15	b	192.0 (183.0–201.0)	63.0 (56.7–69.3)	161.0 (91.7–188.4)	62.0 (55.0–70.0)	129.0 (84.1–138.9)	73.0 (66.7–75.7)
R 20	b	229.5 (227.3–231.8)	64.0 (63.1–64.9)	203.0 (97.9–221.8)	64.0 (54.8–70.0)	127.0 (79.5–157.6)	74.0 (68.6–74.9)
MRC	a	108.6 (97.4–119.8)	12.5 (12.1–13.0)	121.0 (53.4–153.8)	12.0 (11.0–15.0)	79.0 (67.2–127.6)	15.0 (11.4–19.5)
	b	310.0 (286.6–333.4)	60.5 (57.4–63.7)	246.0 (115.8–298.4)	55.0 (33.6–64.8)	147.0 (102.5–225.3)	65.0 (61.4–66.8)
C	a	14.7 (10.7–18.6)	10.0 (8.2–11.8)	11.7 (7.9–21.5)	10.0 (8.0–12.0)	11.2 (10.8–13.5)	11.0 (10.1–12.8)
	b	60.1 (53.4–66.7)	25.5 (24.2–26.9)	45.5 (42.2–58.6)	25.0 (22.0–26.0)	33.2 (30.1–56.1)	25.0 (23.2–25.9)
CF	b	75.9 (71.1–80.7)	25.0 (25.0–25.0)	72.7 (56.9–84.6)	23.2 (19.8–23.2)	66.3 (56.7–75.9)	23.2 (21.6–23.2)

Rod (R) responses were obtained using $0.025 \text{ cd} \cdot \text{sec}/\text{m}^2$ of light stimulation during 20 min of dark adaptation, which was designated R1, R5, R10, R15, and R20. Standard mixed rod cone (MRC) responses were thereafter obtained at $2.5 \text{ cd} \cdot \text{sec}/\text{m}^2$. Photopic ERGs consisted of a photopic single flash cone (C) response and 31 Hz cone flicker (CF) responses, both at $2.5 \text{ cd} \cdot \text{sec}/\text{m}^2$ after 10 min of light adaptation using $25 \text{ cd}/\text{m}^2$ of background light.

types of observations used in the present study showed that the menace response gave much better estimation for loss of retinal function than the PLRs. The results of both observations allowed us to deduce that conventional retinal testing routinely performed in the clinic was not always trustworthy; also, it emphasized the importance of more objective testing techniques, such as use of the ERG. The PLR required fewer intact axons than conscious perception of vision, and therefore, in partial lesions of the proximal visual pathway, the situation may exist where there is loss of vision but the PLR is spared [8]. Detailed studies have shown that a full PLR can still occur in mice lacking both rod and cone photoreceptors, even when there is reduced sensitivity [14]. Recently, a new theory on the PLR-induced retinal cells was presented: both the vitamin-based photosensitive pigment (melanopsin) in retinal ganglion cells and rod-cone photoreceptive systems were associated with PLRs in mice [11]. It was also described in another study that there was a presence of intrinsic melanopsin-mediated PLR activity induced by high light-intensity and an absence of rod-cone-mediated PLR elicited by low light intensities in dogs with retinal degeneration [10]. This phenomenon could explain why there was a presence of PLRs in dogs with PRA in the present study.

Posterior subcapsular cataracts commonly occur secondarily to advanced stages of PRA in many canine breeds [15] and in RP in humans [5]. Results of several previous studies showed that the lipid peroxidation mechanism might be associated with lens opacity due to retinal diseases, such as PRA and RP [6, 9]. The differences in metabolic accumulation may give rise to variations in the age of onset of the secondary cataracts in different canine breeds. Tibetan terriers and miniature poodles with late-onset forms of PRA have lens opacities at older ages [15]. The mean age of cataract onset in MS of South Korea was at the age of 5.4 years which was significantly lower than that seen in other breeds [19].

According to the previous studies, even though ophthalmoscopic abnormalities can be detected in some affected

animals as early as at 14 months of age conclusive ophthalmoscopic lesions were not found in affected dogs until 2 to 5 years of age [20]. It appears that a misdiagnosis could be made in early stages of the disease process, due to variable clinical findings in affected MS dogs. Therefore, ERG is a valuable tool that gives an objective evaluation of retinal function and is readily available for clinicians or retinal researchers.

ERG can be used to show if photoreceptors achieve functional maturity, and whether development is normal or not. Further, the process of phototransduction can be monitored using this equipment [12]. According to previous studies regarding the MS, ERG recordings showed that PRA-affected MS had functional deficits as early as at 8 weeks of age [20]. Further, conclusive changes in ERG parameters were clearly recognized at 15 to 19 weeks of age. Comparing the time point of the ophthalmoscopic abnormalities mentioned above with the ERG changes observed, it is clear that ERG can be objectively used to detect the subtle changes in the fundus very early and prior to the onset of fundoscopic abnormalities. It is an established concept that configuration of the ERG waveform is changed when phototransduction is abnormal.

In summary, it was shown that the mean age \pm SD of MS affected with PRA was 4.3 ± 1.1 years at the first presentation for examination, and most of the PRA-affected dogs had no menace responses and/or PLRs. Ophthalmoscopic abnormalities noted in PRA-affected dogs included several retinal changes previously described in conjunction with PRA. ERG responses in the PRA-affected dogs tested were non-recordable for all levels of light stimuli used in the dark and light adapted states. The present study showed that PRA in the MS was observed in adult dogs at 3 to 5 years of age and that there were functional abnormalities of both the rod and the cone systems at the ages studied.

ACKNOWLEDGMENTS. The study was supported by the Research Institute for Veterinary Science and the BK21

Program for Veterinary Science, College of Veterinary Medicine, Seoul National University, Republic of Korea.

REFERENCES

- Acland, G. M. and Aguirre, G. D. 1987. Retinal degenerations in the dog: IV. Early retinal degeneration (erd) in Norwegian elkhounds. *Exp. Eye Res.* **44**: 491–521. [[Medline](#)] [[CrossRef](#)]
- Aguirre, G. D., Parshall, C. J., Acland, G. M., Notarfrancesco, K., Nitroy, S. and Chader, G. 1985. Progressive retinal atrophy in the miniature schnauzer. *Proc. Am. Coll. Vet. Ophthalmol.* **16**: 226–237.
- Aguirre, G. D. and Rubin, L. F. 1971. The early diagnosis of rod dysplasia in the Norwegian Elkhound. *J. Am. Vet. Med. Assoc.* **159**: 429–433. [[Medline](#)]
- Aguirre- Hernandez, J. and Sargan, D. R. 2005. Evaluation of candidate genes in the absence of positional information: a poor bet on a blind dog! *J. Hered.* **96**: 475–484. [[Medline](#)] [[CrossRef](#)]
- Auffarth, G. U., Tetz, M. R., Krastel, H., Blankenagel, A. and Volcker, H. E. 1997. Complicated cataracts in various forms of retinitis pigmentosa. Type and incidence. *Ophthalmologie* **94**: 642–646. [[Medline](#)] [[CrossRef](#)]
- Babizhayev, M. A. and Deyev, A. I. 1989. Lens opacity induced by lipid peroxidation products as a model of cataract associated with retinal disease. *Biochim. Biophys. Acta* **1004**: 124–133. [[Medline](#)] [[CrossRef](#)]
- Curtis, R., Barnett, K. C. and Leon, A. 1987. An early-onset retinal dystrophy with dominant inheritance in the Abyssinian cat. Clinical and pathological findings. *Invest. Ophthalmol. Vis. Sci.* **28**: 131–139. [[Medline](#)]
- Ferreira, F. M. and Peterson-Jones, S. 2002. Neuro-ophthalmology. pp. 258–275. *In: BSAVA Manual of Small Animal Ophthalmology*, 2nd ed. (Peterson-Jones S. M. and Crispin S. M. eds.), BSABA., Gloucester.
- Goosey, J. D., Tuan, W. M. and Garcia, C. A. 1984. A lipid peroxidative mechanism for posterior subcapsular cataract formation in the rabbit: a possible model for cataract formation in tapetoretinal diseases. *Invest. Ophthalmol. Vis. Sci.* **25**: 608–612. [[Medline](#)]
- Grozdanic, S. D., Matic, M., Sakaguchi, D. S. and Kardon, R. H. 2007. Evaluation of retinal status using chromatic pupil light reflex activity in healthy and diseased canine eyes. *Invest. Ophthalmol. Vis. Sci.* **48**: 5178–5183. [[Medline](#)] [[CrossRef](#)]
- Hattar, S., Lucas, R. J., Mrosovsky, N., Thompson, S., Douglas, R. H., Hankins, M. W., Lem, J., Biel, M., Hofmann, F., Foster, R. G. and Yau, K. W. 2003. Melanopsin and rod-cone photoreceptive systems account for all major accessory visual functions in mice. *Nature* **424**: 76–81. [[Medline](#)] [[CrossRef](#)]
- Hood, D. C. and Birch, D. G. 1996. Assessing abnormal rod photoreceptor activity with the a-wave of the electroretinogram: applications and methods. *Doc. Ophthalmol.* **92**: 253–267. [[Medline](#)] [[CrossRef](#)]
- Jeong, M. B., Han, C. H., Narfström, K., Awano, T., Johnson, G. S., Min, M. S., Seong, J. K. and Seo, K. M. 2008. A phosducin (PDC) gene mutation does not cause progressive retinal atrophy in Korean miniature schnauzers. *Anim. Genet.* **39**: 455–456. [[Medline](#)] [[CrossRef](#)]
- Lucas, R. J., Douglas, R. H. and Foster, R. G. 2001. Characterization of an ocular photopigment capable of driving pupillary constriction in mice. *Nat. Neurosci.* **4**: 621–626. [[Medline](#)] [[CrossRef](#)]
- Millichamp, N. J., Curtis, R. and Barnett, K. C. 1988. Progressive retinal atrophy in Tibetan terriers. *J. Am. Vet. Med. Assoc.* **192**: 769–776. [[Medline](#)]
- Narfström, K. 1985. Progressive retinal atrophy in the Abyssinian cat. Clinical characteristics. *Invest. Ophthalmol. Vis. Sci.* **26**: 193–200. [[Medline](#)]
- Narfström, K. and Petersen-Jones, S. M. 2007. Diseases of the canine ocular fundus. pp. 944–1025. *In: Veterinary ophthalmology*, 4th ed. (Gelatt K. N. ed.), Blackwell Publishing, Oxford.
- Narfström, K., Ekesten, B., Rosolen, S. G., Spiess, B. M., Percicot, C. L. and Ofri, R. 2002. Guidelines for clinical electroretinography in the dog. *Doc. Ophthalmol.* **105**: 83–92. [[Medline](#)] [[CrossRef](#)]
- Park, S. A., Yi, N. Y., Jeong, M. B., Kim, W. T., Kim, S. E., Chae, J. M. and Seo, K. M. 2009. Clinical manifestations of cataracts in small breed dogs. *Vet. Ophthalmol.* **12**: 205–210. [[Medline](#)] [[CrossRef](#)]
- Parshall, C. J., Wyman, M., Nitroy, S., Acland, G. M. and Aguirre, G. D. 1991. Photoreceptor dysplasia: an inherited progressive retinal atrophy of miniature schnauzer dogs. *Prog. Vet. Comp. Ophthalmol.* **1**: 187–203.
- Petersen-Jones, S. M. 1998. A review of research to elucidate the causes of the generalized progressive retinal atrophies. *Vet. J.* **155**: 5–18. [[Medline](#)] [[CrossRef](#)]
- Ropstad, E. O., Bjerkas, E. and Narfström, K. 2007. Electroretinographic findings in the Standard Wire Haired Dachshund with inherited early onset cone-rod dystrophy. *Doc. Ophthalmol.* **114**: 27–36. [[Medline](#)] [[CrossRef](#)]
- Samuelson, D. A. 2007. Ophthalmic anatomy. pp. 37–248. *In: Veterinary Ophthalmology*, 4th ed. (Gelatt K. N. ed.), Blackwell Publishing Ltd., Oxford.
- Whitley, R. D., McLaughlin, S. A. and Gilger, B. C. 1995. Update on eye disorders among purebred dogs. *Vet. Med.* **90**: 574–592.