

Treatment of unicameral bone cyst: systematic review and meta analysis

Muayad Kadhim · Mihir Thacker · Amjed Kadhim · Laurens Holmes Jr.

Received: 7 October 2013 / Accepted: 31 January 2014 / Published online: 26 February 2014
© The Author(s) 2014. This article is published with open access at Springerlink.com

Abstract

Purpose Different treatment modalities have been utilized to treat unicameral bone cyst (UBC), but evidence has not been fully described to support one treatment over another and the optimal treatment is controversial. The aim of this quantitative systematic review was to assess the effectiveness of different UBC treatment modalities.

Methods We utilized Pubmed to isolate retrospective studies on patients with UBC who received any kind of treatment. The included studies needed to have a minimum sample size of 15 patients, and have provided data on radiographic healing outcome.

Results Sixty-two articles were selected for the meta-analysis from a total of 463 articles. The cumulative sample size was 3,211 patients with 3,217 UBC, and male to female ratio was 2.2:1. The summary or pool estimate of methylprednisolone acetate (MPA) injection resulted in a healing rate of (77.4 %) that was comparable to bone marrow injection (77.9 %). A higher healing rate was observed with MPA injection when inner wall disruption was performed. The pool estimate of bone marrow with demineralized bone matrix injection was high (98.7 %).

UBC healing rate after surgical curettage was comparable whether autograft or allograft was utilized (90 %). UBC treatment with flexible intramedullary nails without curettage provided almost 100% healing rate, while continuous decompression with cannulated screws provided 89 % healing rate. Conservative treatment indicated a healing rate of 64.2, 95 % CI (26.7–101.8).

Conclusions Active treatment for UBC provided variable healing rates and the outcomes were favorable relative to conservative treatment. Due to the heterogeneity of the studies and reporting bias, the interpretation of these findings should be handled with caution.

Keywords Unicameral Bone Cyst · Success and failure rate · Treatment modalities · Healing · Persistence and recurrence

Introduction

Unicameral bone cyst (UBC) is a benign lesion that mostly affects children and adolescents, and represents about 3 % of primary tumors in the first two decades of life [1–3]. UBC is also known as solitary or simple bone cyst and radiographically is seen as mildly expansile, lytic thin-walled bone lesion without periosteal reaction. The typical location is in the metaphysis adjacent to the growth plate of the tubular bones, mostly the humerus and femur [3]. Based on the distance between the cyst and the growth plate, UBC is classified as active when the distance is less than 5 mm, and latent when the distance is larger than 5 mm [4]. Other locations of UBC may include the pelvis, ribs, vertebrae and the tarsal bones, especially calcaneus. Several theories have been postulated to explain the origin of UBC, including trauma and inflammation; however, none has been conclusive [5].

M. Kadhim · M. Thacker · L. Holmes Jr. (✉)
Department of Orthopaedic Surgery, Alfred I. DuPont Hospital
for Children, 1600 Rockland Road, Wilmington, DE 19803,
USA

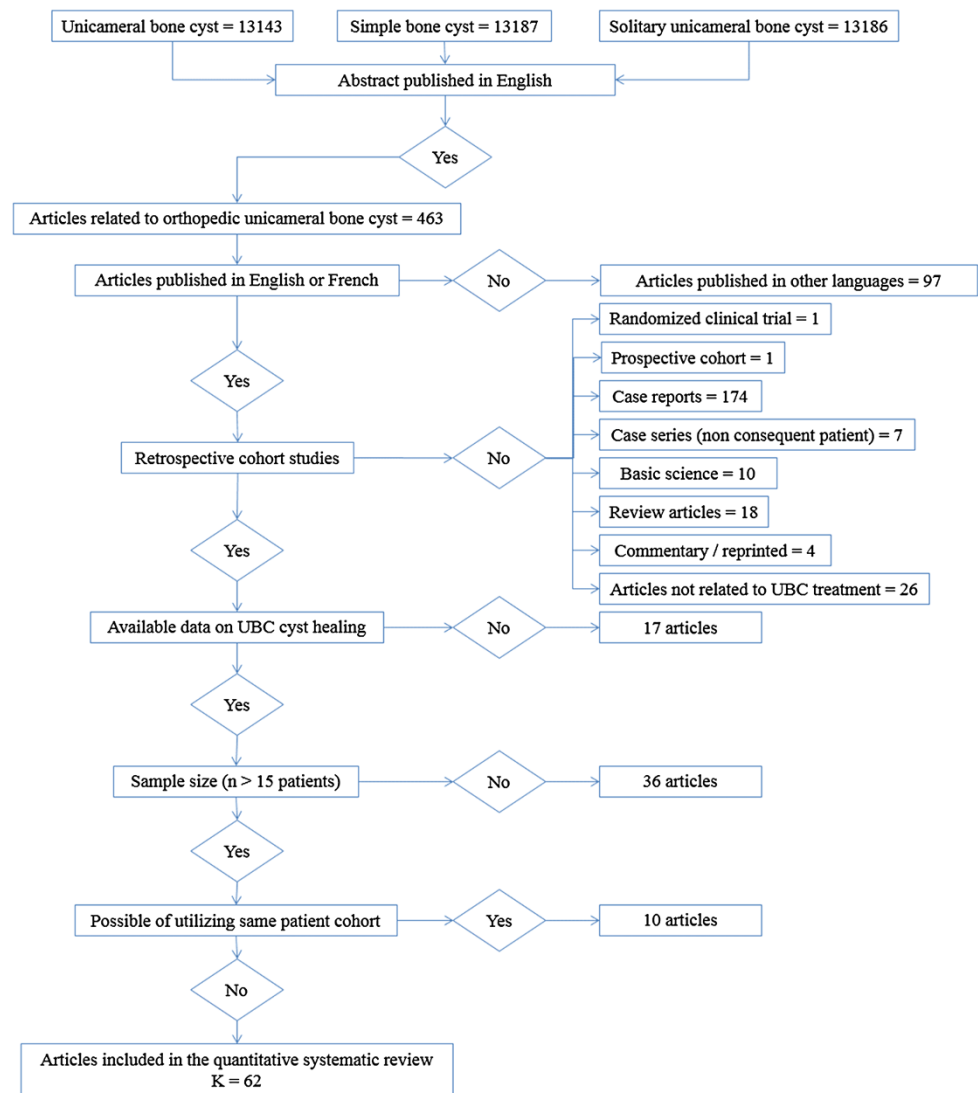
e-mail: lholmes@nemours.org

M. Kadhim
e-mail: muayadkadhim@hotmail.com

M. Thacker
e-mail: mihir.thacker@nemours.org

A. Kadhim
Sawaf Institute for Medical Imaging, Victoria Bridge,
Damascus, Syria
e-mail: amjedkadhim@hotmail.com

Fig. 1 Schema illustrating the details of the articles for the systematic review and the meta-analysis



The purpose of treatment is to restore bone strength, cortical thickness and obliteration of the cyst; and based on these criteria, healing of UBC was classified by Neer [3] and Capanna [6]. Complete filling of the cyst with restoration of cortical thickness was described as healed cyst. When small radiolucent areas persist with good bone strength, the cyst was described as partially healed. When the UBC had continuous bone lucency and thin or broken cortex and did not respond to the treatment, the cyst was considered persistent. Cyst recurrence was defined when a cavity and expansile remodelling and thinning of the cortex develop after full obliteration.

Various treatment modalities have been utilized to treat UBC, including surgical and nonsurgical interventions with variable reported healing rates. UBC has frequently been examined in the literature, yet no clearcut evidence supports one modality over another. The aim of this current study was to review the literature and examine the

published articles referenced in Pubmed about the healing outcome of UBC management with every treatment modality. A qualitative systematic review was performed to screen all the articles and to select eligible articles for a meta-analysis on UBC treatment outcome. We postulated that treatment of UBC leads to better rates of cyst healing.

Materials and methods

Search techniques and terms:

The studies were identified from Pubmed until 2012 using the following search terms: unicameral bone cyst, simple bone cyst and solitary bone cyst. The articles were searched by a single investigator (MK), but were reviewed by two investigators (MK, AK) independently and data were extracted during the review. The articles selected were

reviewed and screened for pertinent information based on specific criteria (Fig. 1).

Eligibility criteria

The extracted articles were examined based on: (a) non-experimental retrospective studies on unicameral bone cyst in any anatomical location and any kind of treatment, (b) studies conducted in any geographic location, (c) studies with abstracts published in English, (d) studies that examined consecutive patients with sample size equal or greater than 15 patients, (e) studies with follow up more than 6 months, and (f) studies that demonstrated the radiographic outcome of treatment that can be classified into (healed, partially healed, persistence or recurrence).

Studies with sample size smaller than 15 were excluded in order to avoid sparse data bias; implying negative finding as a result of small sample size and limited statistical power. Case reports were excluded, as they did not examine consecutive patients. When more than one study was conducted in the same institution, the articles were examined for a possibility of duplicate report on the same patient sample, and data were retrieved from the most complete or recent study.

Study quality assessment

The included studies were assessed for study design, sampling techniques and data on patients' characteristics and radiographic healing status. We determined the objectivity of each study, whether the aims or the purposes were clearly stated, and whether the studies presented factual results. We also examined for adequate statistical analysis and how the outcomes were determined. Studies were assessed for confounding factors that might have influenced the outcome and for any bias, including selection, information and misclassification biases. This quality assessment provided comparable measures to the preferred reporting for systematic reviews and meta-analysis (PRISMA statement) [7].

Study variables

Each study was identified by the first author's last name and the year of publication. Study populations were stratified by sex, age at treatment, cyst location, cyst activity (active or latent), follow-up time and radiographic healing classified by Neer [3] and Capanna [6] criteria. The cohort of each study was categorized into two groups based on the final healing status of UBC: success—good outcome included healed and partially healed UBCs, and failure—poor outcome included persistence and recurrent UBCs.

Treatment groups

All treatment modalities were included in this study (conservative and surgical intervention). Studies that utilized injection as a method of treatment were categorized in one treatment group and subgroups were identified based on the material utilized for injection, including; methylprednisolone acetate (MPA) injection, bone marrow injection, combined MPA with bone marrow, combined bone marrow with demineralized bone matrix (DBM), and combined bone marrow with MPA and DBM. The technique of injection procedure was reviewed in each article to identify whether inner wall disruption was performed or not, and based on this criterion, every injection subgroup was subcategorized into injection with and without inner wall disruption. Studies on surgical treatment were examined and subgroups were identified, including: curettage only, curettage with bone graft (autograft versus allograft), curettage with bone substitution (calcium sulphate pellets, calcium phosphate pellets, Hydroxyapatite, ceramic substitute), curettage with myoplasty, cyst excision, flexible intramedullary nailing (IM nail) and continuous decompression with cannulated screws.

Comparative studies

Retrospective comparative studies that presented outcome of different treatment modalities were selected for further evaluation by combining the patients of each treatment group. Comparative assessment performed included: MPA vs. bone marrow injection, MPA injection with vs. without inner wall disruption, curettage with autograft vs. curettage with allograft, MPA injection vs. curettage with autograft, MPA injection vs. curettage with allograft.

Anatomical location

We identified the studies that provided a list of UBC cases demonstrating age, sex, cyst location treatment modality and radiographic healing outcome. The UBC cases were categorized based on the anatomic location for further assessment.

Sample size and power estimation

Four hundred and sixty-three articles published between 1942 and 2012 were identified for the qualitative systematic review. The number of studies included in the quantitative systematic review (meta-analysis or quantitative evidence synthesis) was represented by $K = 62$. The combination of study sizes (UBC) that constituted this meta-analysis was represented by $n = 3,217$ cysts. To estimate the power of this meta-analysis, we used 95 %

confidence interval (5 % error), effect size of 20 % (0.2), and a random effect meta-analytic technique (DerSimonian and Laird). With these parameters, and with the combined sample sizes from the individual studies (n) for each treatment group, we obtained sufficient power (>80 %) to detect a difference between success (good) and failure (poor) outcomes in terms of UBC healing.

Statistical analysis

Frequency and percentages were employed to summarize nominal variables, while mean and standard deviation were used to describe the continuous variables, including age and follow-up.

We tested the hypotheses to determine the effectiveness of different treatment modalities. Both the fixed method of Peto and Mantel–Haenszel, and the random effect method of Dersimonian-Laird meta-analytic techniques were utilized. The fixed effect method was applicable to the summary point estimate when the studies that constituted the meta-analysis were assessed to be homogenous (implying heterogeneity test I with a significance level >0.05). Unless the homogeneity test was performed, the fixed method was inapplicable. The random effect method was utilized when the homogeneity assumption was not met.

The significance level was <0.05 and all tests were two-tailed. All analyses were performed using STATA 12.0 (StataCorp LP, College Station, TX).

Results

The results of this meta-analysis consisted of two parts, descriptive and inferential. Four hundred and sixty-three articles were identified for the qualitative systematic review. Sixty-two articles were eligible for the quantitative systematic review [3, 6, 8–67]. The rest of the articles were excluded, including: 97 articles that were not in English or French [68–164], one randomized clinical trial [165], one prospective study [166], seven case series [167–173], 174 case reports [2, 174–346], 10 basic science articles [5, 347–355], 26 articles that did not discuss UBC treatment [1, 356–380], 17 articles that did not represent clear data on healing [381–397], 18 review articles [4, 398–414], one article that was a reprint [415], three commentary articles [416–418], 36 articles with a sample size smaller than 15 [419–454], and ten articles with possibility of shared cohort [455–464] (Fig. 1).

The 62 studies of the meta-analysis generated 3,211 patients with 3,217 UBCs. There were 1,709 boys and 765 girls. While some studies did not provide enough data on gender and the proportions did not add up to 100 %, the estimated male to female ratio was 2.2:1. The clinical

Table 1 Number of UBC cases stratified by the anatomic location

Anatomic location	Number of UBC
Humerus ^a	1,629
Proximal humerus	691
Mid humerus	123
Distal humerus	13
Radius	29
Ulna	7
Scapula	1
Clavicle	3
Pelvis ^a	26
Ilium	14
Ischium	3
Pubis	5
Femur ^a	712
Proximal femur	303
Mid femur	22
Distal femur	27
Tibia ^a	111
Proximal tibia	19
Distal tibia	24
Fibula ^a	40
Proximal fibula	9
Mid fibula	3
Distal fibula	3
Calcaneus	166
Talus	3
Metatarsus	6
Other locations	20

^a The exact location of the cyst was not determined in all the papers; therefore, the count did not add up to 100 %

presentation was with a pathologic fracture in 1,107 UBCs, pain in 204 cysts, and incidental finding in 133 UBCs (the clinical presentation was not specified in all studies). Seven hundred and twenty-four UBC were classified as active and 535 cysts were latent. The overall average age at treatment was 10.9 ± 2.9 years, and the average follow up was 6.1 ± 4.2 years (not all the studies provided data on age at surgery and follow-up).

The most common location of UBC was in the humerus (59.2 %), followed by the femur (25.9 %). The calcaneus was affected in 6 %, the tibia in 4 %, the fibula in 1.5 %, the radius in 1.1 %, the pelvis in 0.9 %, and the other locations were affected in 1.4 % (Table 1).

Based on radiographic healing classification, 2,448 UBCs (76.1 %) were classified as healed or partially healed (success), while 769 cysts (23.9 %) were classified as persistent or recurrent (failure).

Table 2 Outcome of UBC stratified by the treatment modalities

Treatment modality	n = UBC	Treatment outcome		Reference articles
		Success	Failure	
Injection (MPA)	1,128	806	322	[6, 12, 14, 16, 19, 22, 25–29, 33, 37–39, 41, 44, 47, 50, 55, 64, 66]
Injection (bone marrow)	114	88	26	[19, 26, 38–40, 45]
Injection (bone marrow + DBM)	85	73	12	[15, 21, 33, 45]
Injection (MPA + bone marrow)	9	3	6	[23]
Injection (bone marrow + MPA + DBM)	34	17	17	[37]
Only curettage	31	16	15	[9, 18, 38, 43, 46, 47]
Curettage with allograft	353	271	82	[8, 9, 14, 25, 27, 29, 35, 37, 53, 57–60]
Curettage with allograft + bone marrow	23	21	2	[56]
Curettage with autograft	128	96	32	[9, 14, 19, 25, 27, 36, 43, 46, 47, 58, 59]
Curettage with allograft + autograft	3	3	0	[14, 59]
Curettage with pellets	115	104	11	[19, 23, 24, 42, 47, 48, 59, 63]
Curettage with hydroxyapatite	25	22	3	[47, 48]
Curettage with ceramic	12	12	0	[8]
Curettage + Zinc cauterization of the cyst	9	8	1	[43]
Curettage with osteoset pellets + autograft	1	1	0	[59]
Curettage with myoplasty	35	32	3	[10]
Curettage with bone graft + Kuntcher stabilization (rinsing the cyst cavity with peroxide)	12	9	3	[64]
Curettage with bone graft + plate stabilization	10	9	1	[66]
Curettage with pellets + plate stabilization	7	6	1	[23]
Minimal invasive curettage + ethanol cauterization + calcium sulfate pellet + cannulated screw	12	11	1	[23]
Curettage + autograft + allograft with IM nail stabilization	19	11	8	[51]
Papers with different surgical techniques ^a	528	426	102	[3, 12, 13, 17, 18, 28, 34, 52, 62, 64]
Cyst excision	83	76	7	[9, 14, 36, 54, 65, 66]
Cyst wall trepanation	26	26	0	[9, 49]
IM nail without curettage	205	196	9	[11, 16, 19, 20, 30–32, 67]
Continuous decompression with cannulated screws	61	47	14	[13, 29, 61]
Conservative treatment	149	58	91	[9, 12, 13, 36, 44, 47, 52, 58–60, 66]
Overall number of cysts	3,217	2,448	769	

^a These papers were not included in the subcategories for treatment modalities, because healing classification was not stratified based on the treatment

Treatment

Primarily three treatment modalities were assessed; injection, surgery and conservative treatment (observational management) (Table 2). Overall injection was utilized in 1,370 cysts. Of the injection cases, 1,128 cysts were treated with MPA, while 114 cysts were injected with bone marrow. Surgical treatment included several surgical techniques as presented in Table 2. Curettage as a separate treatment was done in 31 UBCs. Curettage with allograft was performed in 353 UBCs, while 128 cysts were treated with curettage and autograft. Flexible IM nail was used in 205 UBCs and cannulated screws for continuous

decompression were utilized in 61 UBCs. Conservative treatment implying observational management was utilized in 149 cysts.

Comparative studies

We examined the studies that compared the healing outcome of MPA injection with bone marrow injection [19, 26, 38, 39]. Of 206 patients in this protocol, a higher rate of success was observed in bone marrow injection compared to MPA injection (Fig. 2). Only one study examined MPA injection outcome with and without inner wall disruption [47] and the outcome success was comparable. Five studies

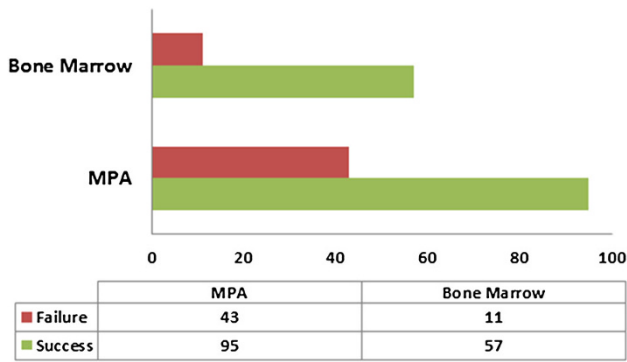


Fig. 2 Bar chart illustrating the studies that compared the difference in healing outcome between bone marrow injection and methylprednisolone (MPA) injection

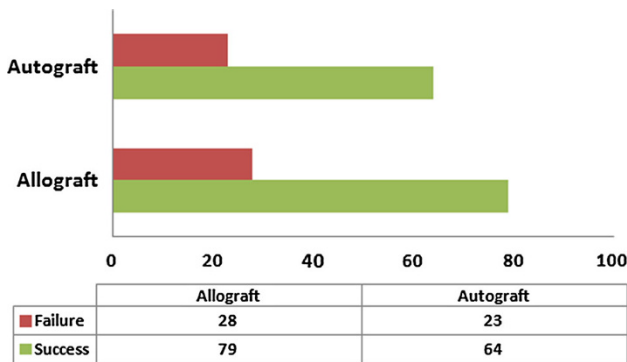


Fig. 3 Bar chart illustrating the studies that compared the difference in healing outcome of surgical curettage between allograft and autograft

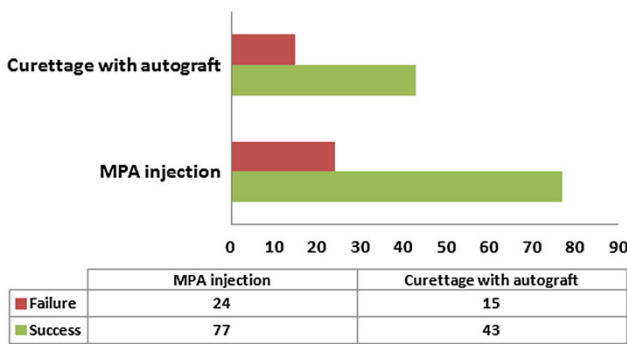


Fig. 4 Bar chart illustrating the studies that compared the difference in healing outcome between methylprednisolone (MPA) injection and surgical curettage with autograft

examined the difference in outcome of curettage with allograft compared to autograft [3, 9, 14, 25, 27], and the success rate was comparable (Fig. 3). Five articles compared the outcome of MPA injection relative to surgical curettage with autograft [14, 19, 25, 27, 47] (Fig. 4), and five articles also examined the outcome of MPA injection compared to surgical curettage with allograft [14, 25, 27, 29, 37] (Fig. 5).

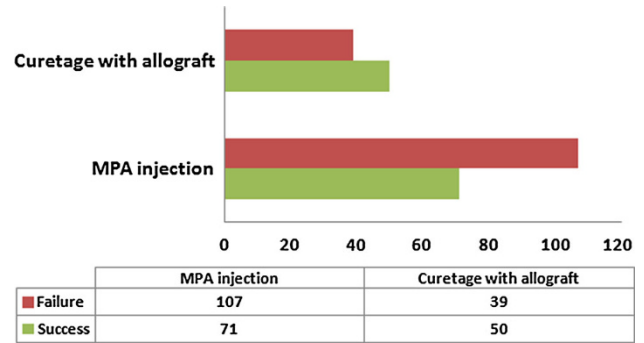


Fig. 5 Bar chart illustrating the studies that compared the difference in healing outcome between methylprednisolone (MPA) injection and surgical curettage with allograft

Outcome of treatment based on the anatomic location

The outcome of treatment based on UBC anatomic location was also examined, including (humerus, femur, calcaneus, fibula, tibia and radius). Some studies did not present healing status for each anatomic location of the cyst; therefore, the numbers and percentages did not add up to 100 % of the total number of UBC of the meta-analysis. Tables 3, 4, 5, and 6 present the findings on healing outcome stratified by sex, activity level and treatment modalities. A few studies examined the fibula, radius, tibia and pelvic locations.

Quantitative results (Pool estimates)

Table 7 illustrates the percentages and 95 % CI of each treatment modality representing the successful outcome (healed and partially healed UBC). The combination of studies in almost all the categories of the meta-analysis indicated satisfactory healing of UBC after each specific treatment. The summary or pool estimate of overall injection category was 81.3, 95 % CI (77.9–84.8), implying a statistically significant 81 % success rate for overall injection ($p < 0.05$). MPA injection resulted in a healing rate of 77.4, 95 % CI (72.7–82.2) (Fig. 6). The effect of inner wall disruption with MPA injection was examined and higher healing rate was observed when the disruption was performed. The pool estimate of bone marrow injection was comparable to MPA injection, 77.9, 95 % CI (65.9–89.9) (Fig. 7). Only one study reported on the outcome of bone marrow injection with inner wall disruption and success rate was 78.6 % [39]; therefore, no pool estimate was performed for bone marrow injection with inner wall disruption. The pool estimate of bone marrow with DBM injection was high, 98.7, 95 % CI (95.7–101.7) relative to injection with either MPA or bone marrow.

Table 3 The characteristics and healing outcome of UBCs located in the humerus (*n* = 497)

	Treatment outcome	
	Success	Failure
Sex ^a		
Male	132 (79.0)	35 (21.0)
Female	51 (82.3)	11 (17.7)
Location ^a		
Metaphysis	145 (73.6)	52 (26.4)
Diaphysis	31 (93.9)	2 (6.1)
Activity ^a		
Active	31 (72.1)	12 (27.9)
Latent	31 (81.6)	7 (18.4)
Treatment		
Surgical curettage	107 (77.0)	32 (23.0)
No graft	12 (63.2)	7 (36.8)
Allograft	23 (95.8)	1 (4.2)
Autograft	35 (74.5)	12 (25.5)
Mix allograft + autograft	11 (57.9)	8 (42.1)
Allograft + bone marrow	7 (78.5)	1 (12.5)
Ceramic	6 (100)	0 (0)
Osteoset pellets	13 (81.2)	3 (18.8)
Injection		
MPA	86 (81.1)	20 (18.9)
Bone marrow	16 (72.7)	6 (27.3)
Bone marrow + DBM	28 (100)	0 (0)
MPA + bone marrow	2 (100)	0 (0)
IM nail	88 (96.7)	3 (3.3)
Screws	12 (85.7)	2 (7.1)
Cyst excision	39 (92.9)	3 (14.7)
Conservative	12 (22.6)	41 (77.3)
Proximal metaphysis	6 (12.8)	41 (78.2)
Diaphysis	4 (100)	0 (0)

Data were retrieved from these references: [6, 8, 9, 12, 13, 15, 21, 24, 25, 27, 30, 31, 38, 42, 43, 45, 46, 51, 54, 61, 65, 67]

MPA methylprednisolone, DBM demineralized bone matrix, IM nail Intramedullary nail, Screws continuous decompression with cannulated screws

^a The exact location of the cyst was not determined in all the papers; therefore, the percentages did not add up to 100 %

Surgical curettage was examined according to the utilization of bone graft or bone substitute, and the pool estimates of all the subcategories were comparable. Other surgical managements were also assessed, including cyst excision, continuous decompression with IM nail or cannulated screws, and cyst wall trepanation (Table 3). The pool estimate of conservative treatment was 64.2, 95 % CI (26.7–101.8) (Fig. 8).

Table 4 The characteristics and healing outcome of UBCs located in the femur (*n* = 211)

	Treatment Outcome	
	Success	Failure
Sex ^a		
Male	37 (75.5)	12 (24.5)
Female	30 (88.2)	4 (11.8)
Location ^a		
Metaphysis	99 (84.6)	18 (15.4)
Diaphysis	6 (100.0)	0 (0)
Activity ^a		
Active	30 (75.0)	10 (25.0)
Latent	16 (84.2)	3 (15.8)
Treatment		
Surgical curettage	63 (81.1)	14 (18.2)
No graft	13 (76.5)	4 (23.5)
Allograft	15 (88.2)	2 (11.8)
Autograft	18 (78.3)	5 (21.7)
Ceramic	7 (100)	0 (0)
Osteoset pellets	6 (85.7)	1 (14.3)
Injection		
MPA	46 (76.7)	14 (23.3)
Bone marrow	10 (76.9)	3 (23.1)
Bone marrow + DBM	10 (100)	0 (0)
IM nail	32 (97.0)	1 (3.0)
Screws	2 (40.0)	3 (60.0)
Cyst excision	2 (100)	0 (0)
Conservative	7 (63.3)	4 (36.4)
Metaphysis	4 (50.0)	4 (50.0)

Data were retrieved from these references: [6, 8, 9, 12, 13, 15, 20, 21, 24, 25, 27, 30, 31, 38, 42–46, 54, 61]

MPA methylprednisolone, DBM demineralized bone matrix, IM nail Intramedullary nail, Screws continuous decompression with cannulated screws

^a The exact location of the cyst was not determined in all the papers; therefore, the percentages did not add up to 100 %

Discussion

The effect of various treatment modalities on UBC management has been repeatedly examined in the literature, but the natural history of UBC and the optimal treatment remain unclear. The conventional knowledge about UBC is that it is a self-limited benign bone lesion [370]; however, the healing rate without treatment (observational management) is undetermined and most of the studies in this review demonstrated better results with active treatment. With the purpose to better understand the role of each treatment modality of UBC, we aimed in this quantitative systematic review to synthesize the literature and assess the

Table 5 The characteristics and healing outcome of UBCs located in the calcaneus ($n = 116$)

	Treatment outcome	
	Success	Failure
Sex ^a		
Male	24 (77.4)	7 (22.6)
Female	19 (95.0)	1 (5.0)
Treatment		
Surgical curettage	76 (96.2)	3 (3.8)
No graft	1 (100)	0 (0)
Allograft	33 (100)	0 (0)
Autograft	17 (94.4)	1 (5.6)
Mix allograft + autograft	2 (100)	0 (0)
Allograft + bone marrow	21 (91.3)	2 (8.7)
Osteoset pellets	2 (100)	0 (0)
Injection (bone marrow + DBM)	1 (100)	0 (0)
Screws	10 (100)	0 (0)
Cyst excision	1 (100)	0 (0)
Conservative	1 (4.0)	24 (96.0)

Data were retrieved from these references: [21, 24, 42, 54, 56–59, 61]

DBM demineralized bone matrix, Screws Continuous decompression with cannulated screws

^a The exact location of the cyst was not determined in all the papers, therefore the percentages did not add up to 100 %

natural history of UBC, as well as evaluate the various treatment methods.

The main purpose of meta-analysis is to improve the power by combining homogeneous studies and arriving at a summary effect or pool estimate. We performed both systematic review and meta-analysis to examine the effect of several treatment modalities on UBC. Specifically, we tested the hypothesis regarding the effectiveness of different treatment modalities on UBC healing. Our meta-analysis has some relevant findings: overall active treatment improves UBC healing, regardless of anatomic site and the type of treatment compared to observational management. In this meta-analysis, observational treatment leads to a healing rate of 64 %. However, due to the variability of the studies, the rate of healing after conservative treatment can be as low as 27 % and as high as 100 %. The healing rate after conservative treatment varied in different anatomic location. Higher failure rate of conservative treatment was found in calcaneal and humeral UBCs compared to femoral UBCs (although the number of femoral UBCs was small, 11 out of 211 cysts were treated conservatively).

The indication to treat UBC is to prevent a pathologic fracture and to manage symptoms, especially pain. Historically, surgical curettage and cyst excision with bone graft were the optimal choices to treat UBCs. Based on this

Table 6 The characteristics and healing outcome of UBCs in other locations

Radius ($n = 8^a$)		
Surgical curettage	6 (100)	0 (0)
Injection		
Bone marrow + DBM	1 (100)	0 (0)
Cyst excision	1 (100)	0 (0)
Fibula ($n = 5^b$)		
Injection		
MPA injection	2 (100)	0 (0)
Bone marrow + DBM	1 (100)	0 (0)
Cyst excision	2 (100)	0 (0)
Tibia ($n = 20^c$)		
Surgical curettage injection	9 (90)	1 (10)
MPA	3 (60)	2 (40)
Bone marrow	2 (100)	0 (0)
IM nail	1 (100)	0 (0)
Screws	1 (100)	0 (0)
Ischium ($n = 3^d$)		
Surgical curettage	1 (100)	0 (0)
Cyst excision	1 (100)	0 (0)
Screws	1 (100)	0 (0)
Ilium ($n = 3^e$)		
Curettage	1 (50)	1 (50)
Screws	0 (0)	1 (100)
Pubis ($n = 1^f$)		
Screw	1 (100)	0 (0)
Talus ($n = 1^g$)		
Injection (bone marrow + DBM)	1 (100)	0 (0)
Clavicle ($n = 1^h$)		
Cyst excision	1 (100)	0 (0)

MPA methylprednisolone, DBM demineralized bone matrix, IM nail intramedullary nail, Screws continuous decompression with cannulated screws

^a The exact location of UBCs in the radius was not specified, reference: [12, 21, 24, 38, 46, 54]

^b Among the UBCs in the fibula, three cysts were in the metaphysis, two were not specified, reference: [6, 9, 21, 27]

^c Among the UBCs in the tibia, 14 cysts were in the metaphysis, two were in the diaphysis and the rest were not specified, reference: [6, 8, 9, 20, 25, 27, 43, 45, 46, 61]

^d Ref. [9, 54, 61]

^e Ref. [9, 43, 61]

^f Ref. [61]

^g Ref. [21]

^h Ref. [9]

meta-analysis, UBC healing rate after surgical curettage was comparable (90 %) whether autograft or allograft was utilized. The utilization of MPA in the treatment of UBC was first described by Scaglietti [454]. The role of MPA is to reduce the production of cyst fluid from the inner wall

Table 7 Pool estimate of treatment outcome for different treatment modalities

Treatment category	Pool estimate (%)	95 % Confidence interval
Overall injection ^a	81.3	77.9–84.8
MPA injection ^a	77.4	72.7–82.2
With no inner wall disruption ^a	77.5	72.7–82.3
With inner wall disruption ^a	86.6	59.6–113.7
Bone marrow injection ^a	77.9	65.9–89.9
With no inner wall disruption ^a	77.4	63.2–91.5
Bone marrow + DBM injection ^a	98.7	95.7–101.7
With no inner wall disruption ^b	99.9	98.7–101.1
With inner wall disruption ^a	86.1	57.6–114.7
Curettage with allograft ^a	90.8	86.7–94.9
Curettage with autograft ^a	90.9	85.8–96.1
Curettage with pellets ^a	96.5	91.7–101.3
Sulfate pellets ^a	89.9	75.3–104.4
Phosphate pellets ^b	99.2	95.7–102.7
Curettage with hydroxyapatite ^b	98.7	94.5–102.9
Cyst excision ^a	96.7	91.3–102.1
IM nail with no curettage ^b	99.7	99.0–100.4
Continuous decompression with cannulated screws ^a	83.9	63.1–104.7
With no curettage ^a	88.8	64.5–113.0
Cyst wall trepanation ^b	99.9	98.7–101.1
Conservative treatment ^a	64.2	26.7–101.8

^a Pool estimate was reported utilizing random effect meta-analysis

^b Pool estimate was reported utilizing fixed effect meta-analysis

cyst, which enhances bone healing [352]. On the other hand, bone marrow injection was proposed to accelerate healing, given the osteogenic potential of red marrow [465, 466]. In this meta-analysis, the healing rate of UBC was

comparable after injection with bone marrow or MPA (77 %). The healing rate after MPA or bone marrow injection was higher (almost double) in our meta-analysis compared to the results demonstrated by Wright et al. [165] in a randomized (prospective) clinical trial. This might be a result of failure to report unsuccessful outcomes in studies of retrospective design (reporting bias). Both the randomized study by Wright et al. [165] and our meta-analysis demonstrated comparable healing rate after MPA injection and bone marrow injection.

The utilization of IM nails or cannulated screws for the treatment of UBC was also described, and the rationale was that theoretically, UBCs develop from venous blockage and increase of fluid pressure inside the cyst [5]. In this meta-analysis, we found that treatment with IM nails without curettage provided almost 100 % healing rate of UBC in long bones. IM nails were described as an efficient acute treatment for UBCs that present with a fracture [11, 16, 67]. Cyst wall drilling and trepanation also provided a healing rate of almost 100 %; however, this healing rate was estimated based on only two studies [9, 49].

Although this meta-analysis may be interpreted as a comparison between different treatment modalities such as MPA and bone marrow injection, this is incorrect. Studies that tested hypothesis with respect of comparative effectiveness of treatment were not available; therefore, we were unable to use formal meta-analysis method to examine the differences in outcomes of treatment with different treatment modalities. Future studies designed to compare different modalities of treatment are recommended, and will provide the opportunity for these questions to be addressed.

Our systematic review is limited in the sense that different studies presented with different sampling designs and different study protocols. For example, data were not

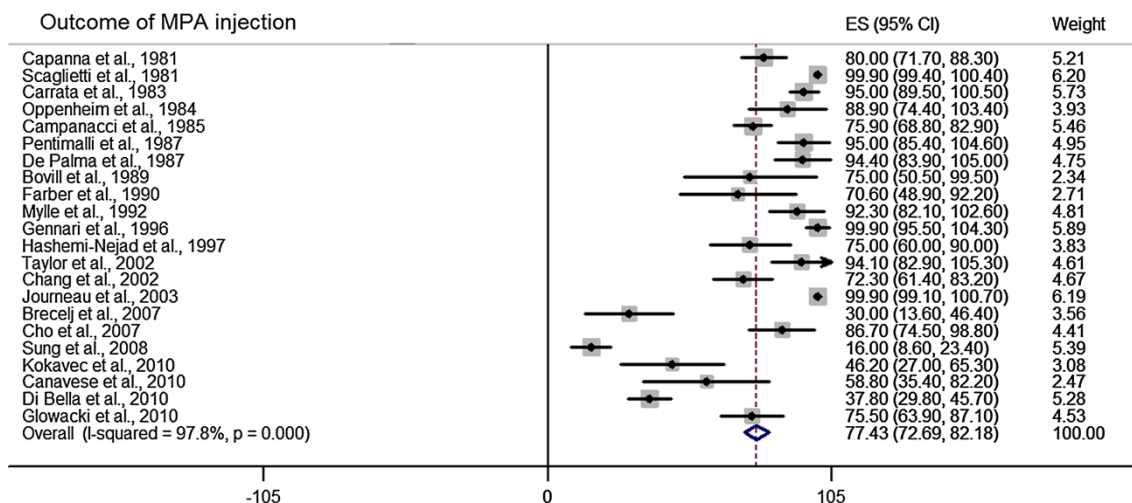


Fig. 6 Forest plot illustrating the point estimate of each article and the pool estimate of healing outcome of methylprednisolone (MPA) injection

Fig. 7 Forest plot illustrating the point estimate of each article and the pool estimate of healing outcome of bone marrow injection

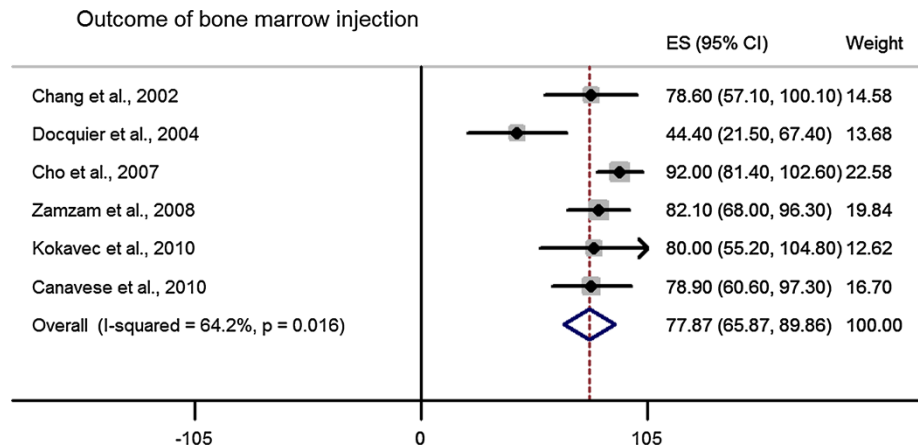
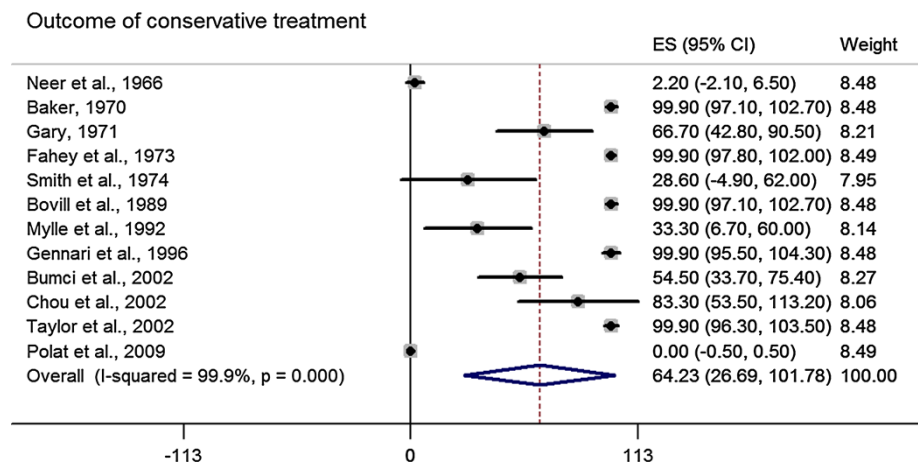


Fig. 8 Forest plot illustrating the point estimate of each article and the pool estimate of healing outcome of conservative treatment



available on MPA dosage that was utilized for treatment. Also, the variability of surgical techniques and type of bone graft (autograft or allograft) has a tendency of introducing a confounding that may lead to bias in our outcomes estimation and interpretation. In addition, we were unable to examine the need for further intervention and recurrence rate in each treatment modality, as data were not clearly specified in the reviewed articles. Also UBC activity as described by the distance from the growth plate may be an important factor that may affect on cyst healing after different treatment modalities. Some of the studies provided data on cyst activity, but only a few of these provided data on the outcome of treatment stratified by cyst activity. The other limitations are the heterogeneity of the patients in terms of UBC anatomic locations, cyst size, sex variability, and duration of treatment and follow-up. We could have performed subgroup meta-analysis in terms of the impact of sex or anatomic site of the UBC on the outcome implying cyst healing. However, since many studies did not provide relevant data, performing such subgroup analysis could have ended up in biased results regarding such effects. Considering this inability to perform the observed subgroup analyses, we recommend future studies to

provide complete data on patients' sex and specific anatomic location.

Heterogeneity remains an important factor to be considered in the conduct and interpretation of meta-analysis. There is no meta-analytic study without some influence of heterogeneity. Several studies used in our meta-analysis showed significant heterogeneity; however, our meta-analysis is not completely driven by this variability. A meta-analytic finding could be reliable and valid despite heterogeneity when appropriate analysis is used in the summary estimate. We applied the random effect meta-analysis given the heterogeneity of studies included in this meta-analysis. Consequently, by adjusting for the differences between studies with the random effect method approach, we have produced relatively standard and valid meta-analytic results on the effect of treatments on the outcomes of UBC. Whereas qualitative systematic review is not intended to quantify results of reviewed literature, we attempted to summarize proportions with regard to UBC healing, and caution is recommended in the interpretation of the results of our systematic review.

We are unaware of previous meta-analysis in this direction to either support or negate our findings. Clinicians

will be interested in assessing the possibility of the results of this meta-analysis in developing guidelines regarding the treatment of UBC. Our meta-analysis of published literature on UBC treatment indicates improved healing rates among treated patients relative to the observational management. Healing rate was found to be comparable in studies that utilized bone marrow injection or MPA, and higher rate of healing was found when DBM was added. Surgical curettage resulted in healing rate of 90 % with the utilization of autograft, allograft or any bone substitution material. Healing rate was also high with the utilization of IM nails.

Open Access This article is distributed under the terms of the Creative Commons Attribution License which permits any use, distribution, and reproduction in any medium, provided the original author(s) and the source are credited.

References

- Boseker EH, Bickel WH, Dahlin DC (1968) A clinicopathologic study of simple unicameral bone cysts. *Surg Gynecol Obstet* 127(3):550–560
- Cohen J (1970) Etiology of simple bone cyst. *J Bone Jt Surg Am* 52(7):1493–1497
- Neer CS, Francis KC, Marcove RC, Terz J, Carbonara PN (1966) Treatment of unicameral bone cyst. A follow-up study of one hundred seventy-five cases. *J Bone Jt Surg Am* 48(4):731–745
- Jaffe H, Lichtenstein L (1942) Solitary unicameral bone cyst—with emphasis on the roentgen picture the pathologic appearance and the pathogenesis. *Arch Surg* 44:1004–1025
- Cohen J (1960) Simple bone cysts. Studies of cyst fluid in six cases with a theory of pathogenesis. *J Bone Jt Surg Am* 42-A:609–616
- Capanna R, Dal MA, Gitelis S, Campanacci M (1982) The natural history of unicameral bone cyst after steroid injection. *Clin Orthop Relat Res* 166:204–211
- Moher D, Liberati A, Tetzlaff J, Altman DG (2009) Preferred reporting items for systematic reviews and meta-analyses: the PRISMA statement. *BMJ* 339:b2535
- Sponer P, Urban K, Urbanova E, Karpas K, Mathew PG (2009) Behaviour of nonresorbable bioactive glass-ceramic implanted into long bone defects: comparison with cancellous allografts. *Arch Orthop Trauma Surg* 129(10):1353–1360
- Baker DM (1970) Benign unicameral bone cyst. A study of forty-five cases with long-term follow up. *Clin Orthop Relat Res* 71:140–151
- Bensahel H, Aigrain Y, Desgrappes Y (1982) Evaluation of the treatment of the unicameral bone cyst in children. *J Chir (Paris)* 119(5):319–323
- Roposch A, Saraph V, Linhart WE (2000) Flexible intramedullary nailing for the treatment of unicameral bone cysts in long bones. *J Bone Jt Surg Am* 82-A(10):1447–1453
- Bovill DF, Skinner HB (1989) Unicameral bone cysts. A comparison of treatment options. *Orthop Rev* 18(4):420–427
- Chuo CY, Fu YC, Chien SH, Lin GT, Wang GJ (2003) Management strategy for unicameral bone cyst. *Kaohsiung J Med Sci* 19(6):289–295
- Oppenheim WL, Galleno H (1984) Operative treatment versus steroid injection in the management of unicameral bone cysts. *J Pediatr Orthop* 4(1):1–7
- Kanellopoulos AD, Yiannakopoulos CK, Soucacos PN (2005) Percutaneous reaming of simple bone cysts in children followed by injection of demineralized bone matrix and autologous bone marrow. *J Pediatr Orthop* 25(5):671–675
- Journeau P, Ciotlos D (2003) Treatment of solitary bone cysts by intra-medullary nailing or steroid injection in children. *Rev Chir Orthop Reparatrice Appar Mot* 89(4):333–337
- Gakuu LN (1997) Solitary unicameral bone cyst. *East Afr Med J* 74(1):31–32
- Graham JJ (1952) Solitary unicameral bone cyst; a follow-up study of thirty-one cases with proven pathological diagnoses. *Bull Hosp Jt Dis* 13(1):106–130
- Kokavec M, Fristakova M, Polan P, Bialik GM (2010) Surgical options for the treatment of simple bone cyst in children and adolescents. *Isr Med Assoc J* 12(2):87–90
- Pogorelic Z, Furlan D, Biocic M, Mestrovic J, Juric I, Todoric D (2010) Titanium intramedullary nailing for treatment of simple bone cysts of the long bones in children. *Scott Med J* 55(3):35–38
- Rougraff BT, Kling TJ (2002) Treatment of active unicameral bone cysts with percutaneous injection of demineralized bone matrix and autogenous bone marrow. *J Bone Jt Surg Am* 84-A(6):921–929
- de Palma L, Santucci A (1987) Treatment of bone cysts with methylprednisolone acetate. A 9 to 11 year follow-up. *Int Orthop* 11(1):23–28
- Hou HY, Wu K, Wang CT, Chang SM, Lin WH, Yang RS (2010) Treatment of unicameral bone cyst: a comparative study of selected techniques. *J Bone Jt Surg Am* 92(4):855–862
- Peltier LF, Jones RH (2004) Treatment of unicameral bone cysts by curettage and packing with plaster-of-Paris pellets. 1978. *Clin Orthop Relat Res* 422:145–147
- Farber JM, Stanton RP (1990) Treatment options in unicameral bone cysts. *Orthopedics* 13(1):25–32
- Cho HS, Oh JH, Kim HS, Kang HG, Lee SH (2007) Unicameral bone cysts: a comparison of injection of steroid and grafting with autologous bone marrow. *J Bone Jt Surg Br* 89(2):222–226
- Pentimalli G, Tudisco C, Scola E, Farsetti P, Ippolito E (1987) Unicameral bone cysts—comparison between surgical and steroid injection treatment. *Arch Orthop Trauma Surg* 106(4):251–256
- Campanacci M, Capanna R, Picci P (1986) Unicameral and aneurysmal bone cysts. *Clin Orthop Relat Res* 204:25–36
- Brecej J, Suhodolcan L (2007) Continuous decompression of unicameral bone cyst with cannulated screws: a comparative study. *J Pediatr Orthop B* 16(5):367–372
- Masquijo JJ, Baroni E, Miscione H (2008) Continuous decompression with intramedullary nailing for the treatment of unicameral bone cysts. *J Child Orthop* 2(4):279–283
- De SN, Andreacchio A (2006) Elastic stable intramedullary nailing is the best treatment of unicameral bone cysts of the long bones in children? Prospective long-term follow-up study. *J Pediatr Orthop* 26(4):520–525
- Glanzman MC, Campos L (2007) Flexible intramedullary nailing for unicameral cysts in children's long bones : level of evidence: IV, case series. *J Child Orthop* 1(2):97–100
- Di BC, Dozza B, Frisoni T, Cevolani L, Donati D (2010) Injection of demineralized bone matrix with bone marrow concentrate improves healing in unicameral bone cyst. *Clin Orthop Relat Res* 468(11):3047–3055
- Teoh KH, Watts AC, Chee YH, Reid R, Porter DE (2010) Predictive factors for recurrence of simple bone cyst of the proximal humerus. *J Orthop Surg (Hong Kong)* 18(2):215–219
- Spence KF Jr, Bright RW, Fitzgerald SP, Sell KW (1976) Solitary unicameral bone cyst: treatment with freeze-dried crushed

- cortical-bone allograft. A review of one hundred and forty-four cases. *J Bone Jt Surg Am* 58(5):636–641
36. Fahey JJ, O'Brien ET (1973) Subtotal resection and grafting in selected cases of solitary unicameral bone cyst. *J Bone Jt Surg Am* 55(1):59–68
 37. Sung AD, Anderson ME, Zurakowski D, Hornicek FJ, Gebhardt MC (2008) Unicameral bone cyst: a retrospective study of three surgical treatments. *Clin Orthop Relat Res* 466(10):2519–2526
 38. Canavese F, Wright JG, Cole WG, Hopyan S (2011) Unicameral bone cysts: comparison of percutaneous curettage, steroid, and autologous bone marrow injections. *J Pediatr Orthop* 31(1):50–55
 39. Chang CH, Stanton RP, Glutting J (2002) Unicameral bone cysts treated by injection of bone marrow or methylprednisolone. *J Bone Jt Surg Br* 84(3):407–412
 40. Zamzam MM, Abak AA, Bakarman KA, Al-Jassir FF, Khoshhal KI, Zamzami MM (2009) Efficacy of aspiration and autogenous bone marrow injection in the treatment of simple bone cysts. *Int Orthop* 33(5):1353–1358
 41. Scaglietti O, Marchetti PG, Bartolozzi P (1982) Final results obtained in the treatment of bone cysts with methylprednisolone acetate (depo-medrol) and a discussion of results achieved in other bone lesions. *Clin Orthop Relat Res* 165:33–42
 42. Altermatt S, Schwobel M, Pochon JP (1992) Operative treatment of solitary bone cysts with tricalcium phosphate ceramic. A 1 to 7 year follow-up. *Eur J Pediatr Surg* 2(3):180–182
 43. James AG, Coley BL, Higinbotham NL (1948) Solitary, unicameral, bone cyst. *Arch Surg* 57(1):137–147
 44. Norman-Taylor FH, Hashemi-Nejad A, Gillingham BL, Stevens D, Cole WG (2002) Risk of refracture through unicameral bone cysts of the proximal femur. *J Pediatr Orthop* 22(2):249–254
 45. Docquier PL, Delloye C (2004) Autologous bone marrow injection in the management of simple bone cysts in children. *Acta Orthop Belg* 70(3):204–213
 46. Hagberg S, Mansfeld L (1967) The solitary bone cyst. A follow-up study of 24 cases. *Acta Chir Scand* 133(1):25–29
 47. Mylle J, Burssens A, Fabry G (1992) Simple bone cysts. A review of 59 cases with special reference to their treatment. *Arch Orthop Trauma Surg* 111(6):297–300
 48. Inoue O, Ibaraki K, Shimabukuro H, Shingaki Y (1993) Packing with high-porosity hydroxyapatite cubes alone for the treatment of simple bone cyst. *Clin Orthop Relat Res* 293:287–292
 49. Shinozaki T, Arita S, Watanabe H, Chigira M (1996) Simple bone cysts treated by multiple drill-holes. 23 cysts followed 2–10 years. *Acta Orthop Scand* 67(3):288–290
 50. Carrata A, Garbagna P, Mapelli S, Zucchi V (1983) The treatment of simple bone cysts by topical infiltrations of methylprednisolone acetate: technique and results. *Eur J Radiol* 3(1):3–8
 51. Hunt KJ, Bergeson A, Coffin CM, Randall RL (2009) Percutaneous curettage and bone grafting for humeral simple bone cysts. *Orthopedics* 32(2):89
 52. Gray DH (1971) Simple bone cysts: results of a pilot survey. *Aust N Z J Surg* 41(2):169–173
 53. Schreuder HW, Conrad EU III, Bruckner JD, Howlett AT, Sorensen LS (1997) Treatment of simple bone cysts in children with curettage and cryosurgery. *J Pediatr Orthop* 17(6):814–820
 54. McKay DW, Nason SS (1977) Treatment of unicameral bone cysts by subtotal resection without grafts. *J Bone Jt Surg Am* 59(4):515–519
 55. Hashemi-Nejad A, Cole WG (1997) Incomplete healing of simple bone cysts after steroid injections. *J Bone Jt Surg Br* 79(5):727–730
 56. Park IH, Micic ID, Jeon IH (2008) A study of 23 unicameral bone cysts of the calcaneus: open chip allogeneic bone graft versus percutaneous injection of bone powder with autogenous bone marrow. *Foot Ankle Int* 29(2):164–170
 57. Yildirim C, Akmaz I, Sahin O, Keklikci K (2011) Simple calcaneal bone cysts: a pilot study comparing open versus endoscopic curettage and grafting. *J Bone Jt Surg Br* 93(12):1626–1631
 58. Smith RW, Smith CF (1974) Solitary unicameral bone cyst of the calcaneus. A review of twenty cases. *J Bone Jt Surg Am* 56(1):49–56
 59. Polat O, Saglik Y, Adiguzel HE, Arikan M, Yildiz HY (2009) Our clinical experience on calcaneal bone cysts: 36 cysts in 33 patients. *Arch Orthop Trauma Surg* 129(11):1489–1494
 60. Bumci I, Vlahovic T (2002) Significance of opening the medullar canal in surgical treatment of simple bone cyst. *J Pediatr Orthop* 22(1):125–129
 61. Tsuchiya H, Abdel-Wanis ME, Uehara K, Tomita K, Takagi Y, Yasutake H (2002) Cannulation of simple bone cysts. *J Bone Jt Surg Br* 84(2):245–248
 62. Meyer JM, Burdet A (1979) Essential bone cyst and its therapy. *Schweiz Med Wochenschr* 109(19):714–719
 63. Mik G, Arkader A, Manteghi A, Dormans JP (2009) Results of a minimally invasive technique for treatment of unicameral bone cysts. *Clin Orthop Relat Res* 467(11):2949–2954
 64. Glowacki M, Ignys-O'Byrne A, Ignys I, Mankowski P, Melzer P (2010) Evaluation of volume and solitary bone cyst remodeling using conventional radiological examination. *Skeletal Radiol* 39(3):251–259
 65. Immenkamp M, Ehrenbrink H, Knoche U (1982) Subperiosteal segmental resection and insertion of a fibula graft in the treatment of solitary bone cysts of the humerus. *Arch Orthop Trauma Surg* 100(2):107–114
 66. Gennari JM, Merrot T, Legre B, Bergoin M (1996) The choice of treatment for simple bone cysts of the upper third of the femur in children. *Eur J Pediatr Surg* 6(2):95–99
 67. Knorr P, Schmittenbecher PP, Dietz HG (2003) Elastic stable intramedullary nailing for the treatment of complicated juvenile bone cysts of the humerus. *Eur J Pediatr Surg* 13(1):44–49
 68. Lischi DM (1984) Solitary cysts of the calcaneus with inclusion. *Radiol Med* 70(12):995–996
 69. Zidkova H (1984) Solitary benign bone lesions. *Cesk Radiol* 38(4):276–290
 70. Chigira M, Watanabe H, Arita S, Udagawa E (1983) Simple bone cyst—pathophysiology and treatment. *Nihon Seikeigeka Gakkai Zasshi* 57(8):759–766
 71. Vrbicky B (1982) Solitary cyst of the calcaneus (author's transl). *Acta Chir Orthop Traumatol Cech* 49(2):174–176
 72. Sturz H, Hagen FW (1980) Solitary bone cysts with expansion throughout the complete humerus (author's transl). *Z Orthop Ihre Grenzgeb* 118(6):923–926
 73. Glowacki M, Struszynski J, Krasny I (2000) Solitary cyst of the calcaneus contemporary diagnostic possibilities: the results and treatment. *Chir Narzadow Ruchu Ortop Pol* 65(2):117–121
 74. Sturz H, Witt AN (1979) Solitary bone cysts of the ulna (author's transl). *Arch Orthop Trauma Surg* 94(2):105–108
 75. Maranzana G (1979) Solitary osseous cyst in early childhood. *Chir Organi Mov* 65(1):75–80
 76. Iwasaki H, Okamura Y, Hirano Y, Tagawa T, Murata M, Sato I (1979) Three cases of solitary bone cyst (author's transl). *Kyoto Daigaku Kokugakaku Kiyo* 19:79–85
 77. Korzh AA, Pankov EI, Kul'man LV (1978) Reliable and arguable points in the problem of the solitary bone cyst. *Ortop Travmatol Protez* 4:75–80
 78. De Palma L (1978) Use of methylprednisolone acetate in the treatment of solitary bone cysts. *Arch Putti Chir Organi Mov* 29:341–351

79. Hauer G, Wilhelm K, Feldmeier C (1978) Solitary cyst of the distal radius. *Handchirurgie* 10(1):13–14
80. Korzh AA, Kul'man L, Matskevich ND, Pankov EI (1977) Therapeutic tactics in solitary bone cysts in children. *Ortop Travmatol Protez* 12:32–38
81. Koch W, Luy M, Solitary bone cysts (1977) A possible clinical contribution to their pathogenesis. *Dtsch Zahnarztl Z* 32(8):629–630
82. Kovacs A, Szabo G, Tatrai J, Toth E (1976) Simple bone cyst. *Fogorv Sz* 69(11):341–344
83. Aszodi K (1976) Data on the pathogenesis of solitary juvenile bone cysts (author's transl). *Arch Orthop Unfallchir* 86(2):157–168
84. Dick W (1976) Solitary bone cysts in the foot. *Chirurg* 47(2):93–97
85. Melanotte PL, Pavanini G, Turra S (1975) Solitary bone cysts. *Clin Ortop* 26:70–86
86. Ozga A, Borkowski Z (1975) Results of treatment of solitary bone cysts. *Chir Narzadow Ruchu Ortop Pol* 40(2):261–267
87. Olechnowicz A, Tokarowski A, Zappa M (1974) Treatment of solitary bone cysts. *Chir Narzadow Ruchu Ortop Pol* 39(3):349–355
88. Goldschmidt H (1973) Healing and healing picture of the juvenile, solitary bone cyst. *Helv Chir Acta* 40(1):163–170
89. Carnevali G, Lattuada A (1973) Radiological signs of malignancy of solitary lesions of the skeleton. *Minerva Med* 64(54):2808–2827
90. Toth S, Gyarfás F, Perenyi A (1972) Solitary bone cysts. *Monatsschr Unfallheilkd Versicher Versorg Verkehrsmed* 75(7):326–330
91. Pagani A (1971) Solitary bone cysts. *Minerva Med* 62(89):4425–4427
92. Harada M, Nino M, Tanaka S (1970) Case of solitary bone cyst occurring in the carpale (the capitate bone). *Seikei Geka* 21(4):294–297
93. Stefanescu N (1968) Clinico-radiological observations on solitary primary bone cysts based on 5 cases. *Rev Med Chir Soc Med Nat Iasi* 72(2):447–450
94. Ito S (1968) Clinical and radiological studies of solitary bone cysts and benign giant cell tumors. *Nihon Seikeigeka Gakkai Zasshi* 42(3):153–167
95. Pollono F, Cavalli F (1967) On a case of solitary osseous cyst of the olecranon. *Minerva Ortop* 18(10):680–682
96. Kischinhevsky W (1967) Solitary bone cyst. *Arq Bras Med* 54(4):357–359
97. Jansen C (1967) On an atypical solitary bone cyst. *Z Orthop Ihre Grenzgeb* 103(1):109–111
98. Bednarek J, Hibner K (1967) Solitary bone cyst of the clavicle treated by excision and simultaneous bone grafting. *Chir Narzadow Ruchu Ortop Pol* 32(2):281–284
99. Brancadoro P (1966) n 3 cases of solitary osseous cyst of the tarsus. *Nunt Radiol* 32(10):1131–1141
100. Marchese GS, Grassi E, Tos L (1965) Solitary bone cysts. *Minerva Chir* 20(18):773–780
101. Gottschalk E (1965) Clinical observations on a solitary bone cyst. *Zentralbl Chir* 90(26):994–1002
102. Fukuma H (1965) A study of the solitary bone cyst. *Igaku Kenkyu* 35(3):91–128
103. Petracchia A, Volmaro N (1964) Simple bone cyst in an unusual site, comments on a case. *Prensa Med Argent* 31(51):299–303
104. Palkoska F (1964) On the treatment of solitary juvenile bone cysts and giant cell tumors. *Zentralbl Chir* 12(89):1909–1916
105. Romano A, Zaffaroni A (1964) Findings on recurrences of juvenile solitary bone cysts. *Chir Ital* 16:275–288
106. Salzer M, Salzer-Kuntschik M (1964) Giant cell tumor and solitary cyst of bone. *Wien Klin Wochenschr* 1(76):316–318
107. Itami Y, Kamatsu K, Yamashita E (1964) Radiography and histology of the solitary bone cyst. *Rinsho Geka* 19:640–645
108. Dubrov I, Buachidze OS, Fedotov PD (1964) Solitary bone cysts. *Ortop Travmatol Protez* 25:19–23
109. Monesi B, Florio L (1964) Recurrence in operated solitary bone cysts. *Arch Putti Chir Organi Mov* 19:175–189
110. Lievre CA, Calcagni V (1963) On a solitary bone cyst of the wing of the ilium. *Minerva Ortop* 14:615–617
111. Rai I, Kitano M (1963) Cases of solitary bone cyst in siblings. *Nihon Seikeigeka Gakkai Zasshi* 37:623–627
112. Calcagni V (1963) On juvenile solitary osseous cysts of the calcaneus. *Minerva Ortop* 14:556–560
113. Maeda F (1963) Studies on the solitary bone cyst with special reference to its pathogenesis. *Nihon Seikeigeka Gakkai Zasshi* 37:529–547
114. Malcapi C, Turrini PG (1963) Solitary osseous cysts of the calcaneus. *Minerva Ortop* 14:445–451
115. Krebs H (1963) The solitary juvenile bone cyst. *Bruns Beitr Klin Chir* 206:335–350
116. Skwarcz A (1963) Results of surgical treatment for solitary cyst of the long bones. *Chir Narzadow Ruchu Ortop Pol* 28:955–961
117. Lanzillo F (1956) Clinical aspects of solitary bone cysts. *Riforma Med* 70(2):39–42
118. Havranek P, Pesl T, Bartonicek J (2005) Pathologic proximal femoral fractures in children in an unicameral bone cyst. *Acta Chir Orthop Traumatol Cech* 72(5):282–286
119. Gal P, Ondrus S, Skvaril J, Straka M, Jochymek J, Planka L (2009) Synthetic biocompatible degradable material for juvenile bone cyst treatment. *Acta Chir Orthop Traumatol Cech* 76(6):495–500
120. Yu GX, Wei MM (2009) Proximal humeral interlocking antatomic plate for the treatment of proximal humeral fracture and bone cyst. *Zhongguo Gu Shang* 22(10):793
121. Makris V, Papavasiliou KA, Bobos M, Hytiroglou P, Kirkos JM, Kapetanios GA (2009) Simultaneous existence of unicameral bone cysts involving the femur and ischium. *Acta Orthop Traumatol Turc* 43(2):185–189
122. Harges J, Schultheiss M, Gosheger G, Schulte M (2009) The juvenile bone cyst: treatment with continuous decompression using cannulated screws. *Orthopade* 38(3):256–262
123. Planka L, Ondrus S, Skvaril J, Stary D, Gal P (2008) The use of biodegradable materials in the management of bone cysts in children. *Rozhl Chir* 87(11):585–589
124. Tang HC, Wang ZH, Xiang M (2008) Allogeneic bone graft for the treatment of children's bone cyst. *Zhongguo Gu Shang* 21(12):928–929
125. Teng HW, Zhang JS, Fang GJ (2008) Solitary bone cyst in both calcaneuses: a case report. *Zhongguo Gu Shang* 21(4):312
126. Liu H, Sun J, Wang Y, Yang X, Zhu E (2008) Repairing bone defects of benign bone neoplasm by grafting of bioactive glass combined with autologous bone marrow. *Zhongguo Xiu Fu Chong Jian Wai Ke Za Zhi* 22(11):1349–1353
127. Dellling G, Sopta J (2008) Solitary bone cysts of the pelvis. A frequently misinterpreted entity. *Pathologie* 29(3):221–230
128. Sibinski M, Drobniewski M, Adamczyk E, Synder M (2007) Calcaneal solitary bone cysts in children. *Chir Narzadow Ruchu Ortop Pol* 72(3):211–213
129. Deng G, Ling Q, Li T (2007) Treatment of bone cyst by transplantation of autologous bone marrow combined with allograft bone. *Zhongguo Xiu Fu Chong Jian Wai Ke Za Zhi* 21(8):801–803
130. Guo S, Feng W, Jia Y (2007) Lyophilized small-segment allogeneic bone in repairing bone defect due to benign bone tumor and tumor-like lesions after resection and curettage. *Zhongguo Xiu Fu Chong Jian Wai Ke Za Zhi* 21(8):789–792
131. Wang E, Zhao Q, Zhang L (2006) Assessment of therapeutic results for simple bone cyst with percutaneous injection of

- autogenous bone marrow. *Zhongguo Xiu Fu Chong Jian Wai Ke Za Zhi* 20(9):925–927
132. Sulko J (2005) Solitary calcaneal bone cyst in children. *Chir Narzadow Ruchu Ortop Pol* 70(4):261–264
 133. Yilmaz G, Aksoy MC, Alanay A, Yazici M, Alpaslan AM (2005) Treatment of simple bone cysts with methylprednisolone acetate in children. *Acta Orthop Traumatol Turc* 39(5):411–415
 134. Kraus R, Schnettler R (2006) Distraction osteogenesis for adjusting humeral length difference due to premature closure of the proximal growth plate in a simple bone cyst. *Chirurg* 77(4):376–380
 135. Zhang Y, Wang Y, Cheng J (2005) A long-term follow-up of treatment of adult unicameral bone cysts with allograft of lyophilized cancellous bone. *Zhongguo Xiu Fu Chong Jian Wai Ke Za Zhi* 198:600–602
 136. Topuria ZM, Bekauri LA, Makaridze DS (2005) Immunohistochemical characteristics of solitary bone cyst. *Georgian Med News* 118:56–58
 137. Lewandowski B, Kulig T (2004) Simple bone cyst. *Pol Merkur Lekarski* 17(97):70–72
 138. Huch K, Werner M, Puhl W, Dellling G (2004) Calcaneal cyst: a classical simple bone cyst? *Z Orthop Ihre Grenzgeb* 142(5):625–630
 139. Pogoda P, Priemel M, Catala-Lehnen P, Gebauer M, Rupprecht M, Adam G, Rueger JM, Amling M (2004) Simple bone cysts of the calcaneus. Differential diagnosis and therapy. *Unfallchirurg* 107(8):680–688
 140. Cuenca EJ, Herrera RA, Gil AJ, Martinez Martin AA, Bregante BJ (2002) Simple bone cysts in childhood. Retrospective study of 15 cases and review of literature. *Cir Pediatr* 15(2):68–72
 141. Kondoch A, Ewerbeck V, Bernd L (2002) Calcifying solitary bone cyst of the sacrum—A rare type of bone cyst and its unknown localisation, differential diagnosis and management. *Z Orthop Ihre Grenzgeb* 140(2):214–217
 142. Beek FJ, Puijts JE (2001) Diagnostic image (42). Solitary bone cyst of the left calcaneus. *Ned Tijdschr Geneesk* 145(24):1155
 143. Zietek P, Krolewski J, Bohatyrewicz A (1999) Aneurysmal bone cyst and solitary cyst of bone. *Chir Narzadow Ruchu Ortop Pol* 64(6):663–669
 144. Seip GU, Thiele H (1999) Solitary juvenile cyst of the heel bone. Two case reports and review of the literature. *Unfallchirurg* 102(7):576–579
 145. Glowacki M, Marciniak W, Krasny I, Szulc A (1998) The evaluation of selected risk factors of solitary bone cyst recurrence after its curettage and bone graft filling. *Chir Narzadow Ruchu Ortop Pol* 63(3):259–266
 146. Glowacki M, Marciniak W (1997) Solitary bone cyst: etiology, diagnosis, therapy, clinical and radiologic evaluation of treatment results. *Chir Narzadow Ruchu Ortop Pol* 62(5):437–444
 147. Wallenbock E, Pollanz H (1996) Solitary calcaneal cyst. *Langenbecks Arch Chir* 381(6):300–302
 148. Amling M, Werner M, Posl M, Ritzel H, Welkerling H, Wening JV, Maas R, Winkler K, Heise U, Dellling G (1996) Solitary bone cysts. Morphologic variation, site, incidence and differential diagnosis. *Pathologe* 17(1):63–67
 149. Werner M, Heintz A, Dellling G (1996) DNA cytometry of solitary and aneurysmal bone cysts and low malignancy and high malignancy central osteosarcomas. Current significance within the scope of morphologic diagnosis of intraosseous cystic and osteoblastic lesions. *Pathologe* 17(1):44–49
 150. Mandys V, Mazanek J (1995) Solitary “traumatic” mandibular cyst. *Cesk Patol* 31(3):92–93
 151. D’Angelo R, Mangoni Di Stefano ML, Arienzo A, Fazioli F, De Rosa V (1995) Unicameral cysts of the hindfoot. Diagnostic aspects and therapeutic implications. *Radiol Med* 89(3):335–338
 152. Ludwig A, Merten HA (1995) Solitary bone cysts. The pathogenesis, clinical picture and therapy of solitary bone cysts. *Schweiz Monatsschr Zahnmed* 105(1):63–70
 153. Maiat VV (1992) Zonography in solitary bone cysts. *Khirurgiia (Mosk)* 7–8:56–58
 154. Sim E, Haid C (1990) Unicameral cyst of the calcaneus: surgical indications, biomechanical calculations and results of follow-up studies. *Z Orthop Ihre Grenzgeb* 128(6):623–631
 155. Dietlein M, Zanella FE, de Feaux LW (1990) A unicameral aneurysmal bone cyst of the cervical spine. The differential diagnosis of a lateral cervical cyst. *Rofo* 152(6):732–733
 156. Konera W, Okonski M, Gregosiewicz A (1990) Outcome of treating solitary osseous cyst with acetate methylprednisolone injections. *Chir Narzadow Ruchu Ortop Pol* 55(3):237–240
 157. Sarria CA, Oliván GG, Fleta ZJ, Bello Nicolau ML, Jimenez VA, Bueno SM (1989) Solitary bone cyst in childhood: form of presentation and course in 13 cases. *An Esp Pediatr* 30(3):171–174
 158. Bereznoi AP, Nechvolodova OL, Vilenskii EV, Skipenko TT (1988) The outcome of the conservative treatment of solitary and aneurysmal bone cysts in children. *Ortop Travmatol Protez* 2:5–8
 159. Pedersen NW, Schmidt SA (1986) Solitary bone cyst. *Ugeskr Laeger* 148(20):1195–1197
 160. Sokolov TP (1986) Our experience treating a solitary bone cyst with mineralocorticoid preparations. *Ortop Travmatol Protez* 3:48–49
 161. Schwenzer N, Ehrenfeld M, Roos R (1985) The so-called solitary bone cyst. *Dtsch Zahnarztl Z* 40(6):573–575
 162. Fischer-Brandies E, Dielert E (1985) The diagnosis and therapy of solitary bone cysts. *Dtsch Zahnarztl Z* 40(6):570–572
 163. Brandt M, Lehmann W (1985) Frequency and recurrence of solitary bone cysts. *Dtsch Zahnarztl Z* 40(6):566–569
 164. Sleboda B (1985) Solitary cyst of the ilium. *Chir Narzadow Ruchu Ortop Pol* 50(6):513–515
 165. Wright JG, Yandow S, Donaldson S, Marley L (2008) A randomized clinical trial comparing intralesional bone marrow and steroid injections for simple bone cysts. *J Bone Jt Surg Am* 90(4):722–730
 166. Bielecki T, Cieslik-Bielecka A, Zelawski M, Mikusek W (2012) A side-effect induced by the combination of a demineralized freeze-dried bone allograft and leucocyte and platelet-rich plasma during treatment for large bone cysts: a 4-year follow-up clinical study. *Transfus Apher Sci* 47(2):133–138
 167. Creyssel J (1955) Remote prognosis and treatment of solitary cysts of bone. *Lyon Chir* 50(1):98–103
 168. Miles JE, Degenshein GA (1956) Solitary bone cysts. *Am J Surg* 91(2):170–177
 169. Dotter WE (1959) Solitary unicameral bone cysts. *Surg Clin North Am* 39(3):857–864
 170. Creyssel J (1954) Remote prognosis and treatment of solitary bone cysts. *Acta Orthop Belg* 20(5):463–476
 171. Creyssel J, Barry P (1953) Postoperative recurrences in solitary non-parasitic cysts of bones. *Lyon Chir* 48(3):322–335
 172. Tonino AJ, Linclau LA (1974) The solitary bone cyst. *Arch Chir Neerl* 26(2):131–138
 173. Bodart A, Lesure J (1954) Surgical treatment of a solitary cyst in bones. *Rev Med Nancy* 1(79):905–910
 174. Heublein GW, Baird CL (1948) Solitary unicameral bone cyst of right ilium; a case report. *Am J Roentgenol Radium Ther* 59(5):699–704
 175. MacDonald KM, Swanstrom MM, McCarthy JJ, Nemeth BA, Guliani TA, Noonan KJ (2010) Exaggerated inflammatory response after use of recombinant bone morphogenetic protein in recurrent unicameral bone cysts. *J Pediatr Orthop* 30(2):199–205

176. Jerbi OS, Hafsa C, Ben GH, Hamza HA, Sassi N, Gannouni A (2008) Osteoid osteoma of the talus and simple bone cyst of the homolateral calcaneus. A rare association. *Rev Chir Orthop Reparatrice Appar Mot* 94(1):96–99
177. Goto T, Nemoto T, Okuma T, Kobayashi H, Funata N (2008) Mirror-image solitary bone cyst of the humerus in a pair of mirror-image monozygotic twins. *Arch Orthop Trauma Surg* 128(12):1403–1406
178. Gallagher TA, Lim-Dunham JE, Vade A (2007) CT findings of a unicameral calcaneal bone cyst containing a fluid-fluid level. *Comput Med Imaging Graph* 31(2):111–113
179. Lu AP, Hame SL (2005) Autologous osteochondral transplantation for simple cyst in the patella. *Arthroscopy* 21(8):1008
180. Wada R, Lambert RG (2005) Deposition of intraosseous fat in a degenerating simple bone cyst. *Skeletal Radiol* 34(7):415–418
181. Hanna SJ, Dasic D, Floyd A (2004) Simple bone cysts of the calcaneus: a report of five cases and a review of the literature. *Foot Ankle Int* 25(9):680–684
182. Coskun B, Akpek S, Dogulu F, Uluoglu O, Eken G (2004) Simple bone cyst in spinous process of the c4 vertebra. *Am J Neuroradiol* 25(7):1291–1293
183. Ogata T, Matsuda Y, Hino M, Kawatani Y, Sogabe H, Yamamoto H (2004) A simple bone cyst located in the pedicle of the lumbar vertebra. *J Spinal Disord Tech* 17(4):339–342
184. Baughman R, Johnson P, Abramson H (2003) Testing your diagnostic skills. Case no. 2. Traumatic (simple) bone cyst. *Today's FDA* 15(10):20–22
185. Amrani A, Dandane MA, el Alami Z, Miri A (2002) An unusual localization of solitary bone cyst in a child: the lumbar spine. *Acta Orthop Belg* 68(5):551–554
186. Cohen N, Keret D, Ezra E, Lokiec F (2002) Unusual simple bone cyst of the distal radius in a toddler. *Isr Med Assoc J* 4(2):137–139
187. Abdel-Wanis ME, Tsuchiya H, Minato H, Morinaga T, Yamamoto N, Tomita K (2001) Bilateral symmetrical cysts in the upper tibiae in a skeletally mature patient: might they be simple bone cysts? *J Orthop Sci* 6(6):595–600
188. Fujimoto T, Nakamura T, Ikeda T, Koyanagi E, Takagi K (2002) Solitary bone cyst in L-2. Case illustration. *J Neurosurg* 97(1 Suppl):151
189. Chang H, Park JB, Lee EJ (2001) Simple bone cyst of lamina of lumbar spine: a case report. *Spine (Phila Pa 1976)* 26(22):E531–E534
190. Komiya S, Inoue A (2000) Development of a solitary bone cyst—a report of a case suggesting its pathogenesis. *Arch Orthop Trauma Surg* 120(7–8):455–457
191. Bonnel F, Canovas F, Faure P (1999) Treatment of a simple bone cyst of the calcaneus by endoscopic curettage with cancellous bone injection. *Acta Orthop Belg* 65(4):528–531
192. Kitoh H, Nogami H (1999) A simple bone cyst containing secretory cells in its lining membrane in a patient with polyostotic fibrous dysplasia. *Pediatr Radiol* 29(6):481–483
193. Maas EJ, Craig JG, Swisher PK, Amin MB, Marcus N (1998) Fluid-fluid levels in a simple bone cyst on magnetic resonance imaging. *Australas Radiol* 42(3):267–270
194. Ehara S, Nishida J, Shiraishi H, Honda M, Abe M, Satoh T (1997) Eccentric simple bone cysts of the femoral neck in adults. *Clin Imaging* 21(4):233–236
195. Park CK, Cho KK, Lee SW, Jeon JS, Kang JK, Choi CR (1997) Simple bone cyst of the axis. *Childs Nerv Syst* 13(3):171–174
196. Margolis M, McLennan MK (1994) Radiology rounds. Simple bone cyst. *Can Fam Physician* 40:1535–1539–1541
197. Watanabe H, Arita S, Chigira M (1994) Aetiology of a simple bone cyst. A case report. *Int Orthop* 18(1):16–19
198. Seckler MM, Kenan S, Desimone D, Abdelwahab IF, Lewis MM (1993) Simple bone cysts: true recurrence after complete obliteration. *Bull Hosp Jt Dis* 53(4):50–53
199. Zamarin RI, Bosacco DN (1992) Answer please. Simple (unicameral) bone cysts. *Orthopedics* 15(8):989–993–89, 994
200. Hoeffel JC (1992) Simple bone cysts of the pelvis in adolescents. A report of four cases. *J Bone Jt Surg Am* 74(6):951–952
201. Abdelwahab IF, Hermann G, Norton KI, Kenan S, Lewis MM, Klein MJ (1991) Simple bone cysts of the pelvis in adolescents. A report of four cases. *J Bone Jt Surg Am* 73(7):1090–1094
202. Andrews JR, Tedder JL, Godbout BP (1991) Simple bone cyst of the distal tibia: a case for ankle arthroscopy. *Arthroscopy* 7(4):381–384
203. Jasan M, House JH, Brand JC (1990) Bilateral unicameral bone cysts in the hamate bones. *J Hand Surg Am* 15(6):888–890
204. Kragel PJ, Williams J, Garvin DF, Goral AB (1989) Solitary bone cyst of the radius containing Liesegang's rings. *Am J Clin Pathol* 92(6):831–833
205. Sener RN (1989) Persistent femoral neck cysts in healed Legg-Perthes' disease: a clue to the etiology of simple bone cyst? *Pediatr Radiol* 19(6–7):496–497
206. Nakamura T, Takagi K, Kitagawa T, Harada M (1988) Micro-density of solitary bone cyst after steroid injection. *J Pediatr Orthop* 8(5):566–568
207. Baruch A, Haas A, Lifschitz-Mercer B, Zeligowsky A (1987) Simple bone cyst of the metacarpal. *J Hand Surg Am* 12(6):1103–1106
208. Chigira M, Takehi Y, Nagase M, Arita S, Shimizu T, Shinozaki T (1987) A case of multiple simple bone cysts. With special reference to their etiology and treatment. *Arch Orthop Trauma Surg* 106(6):390–393
209. Cudia G, Gordeeff A, Panzoni E (1987) Solitary bone cyst. A case of dual mandibular and humeral location. *Rev Stomatol Chir Maxillofac* 88(1):31–35
210. Steinberg GG (1985) Ewing's sarcoma arising in a unicameral bone cyst. *J Pediatr Orthop* 5(1):97–100
211. Kozlowski K, Masel J (1982) Simple bone cysts (report of two unusual cases). *Australas Radiol* 26(3):269–272
212. Blumberg ML (1981) CT of iliac unicameral bone cysts. *AJR Am J Roentgenol* 136(6):1231–1232
213. Mirra JM, Bernard GW, Bullough PG, Johnston W, Mink G (1978) Cementum-like bone production in solitary bone cysts. (so-called “cementoma” of long bones). Report of three cases. Electron microscopic observations supporting a synovial origin to the simple bone cyst. *Clin Orthop Relat Res* 135:295–307
214. Porat S, Lowe J, Rouso M (1978) Solitary bone cyst in the infant radius. A case report. *Clin Orthop Relat Res* 135:132–136
215. Lloyd ES, Press HC Jr (1978) Solitary bone lesion in a young adult. *J Natl Med Assoc* 70(9):681–682
216. Khermish O, Weissman SL (1977) Coxa vara, avascular necrosis and osteochondritis dissecans complicating solitary bone cysts of the proximal femur. *Clin Orthop Relat Res* 126:143–146
217. Watanabe R (1977) Solitary bone cyst of the rib. *Nihon Geka Hokan* 46(1):68–71
218. Dawson EG, Mirra JM, Yuhl ET, Lasser K (1976) Solitary bone cyst of the cervical spine. *Clin Orthop Relat Res* 119:141–143
219. Nelson JP, Foster RJ (1976) Solitary bone cyst with epiphyseal involvement: a case report. *Clin Orthop Relat Res* 118:147–150
220. Gwinn JL, Lee FA (1976) Radiological case of the month: solitary bone cyst. *Am J Dis Child* 130(6):655–656
221. Samuelson KM, Momberger GL, Coleman SS (1975) Solitary bone cyst of the ilium. Report of two cases and a review of the literature. *Rocky Mt Med J* 72(10):443–445
222. Ogden JA, Griswold DM (1972) Solitary cyst of the talus. *J Bone Jt Surg Am* 54(6):1309–1310
223. Melrose RJ, Abrams AM, Needleman G (1971) Multiple osseous dysplasia with concomitant simple bone cyst. *J South Calif Dent Assoc* 39(5):386–389

224. Fincher RL (1971) Radiographic diagnosis of a bone cyst of the humerus with pathological fracture. *J Ark Med Soc* 67(9):298
225. Tanghe W, Verstrecken J, Mulier JC (1970) Solitary cyst of the ramus ossis pubis. Report of a case. *Acta Orthop Belg* 36(3):346–349
226. Broder HM (1968) Possible precursor of unicameral bone cysts. *J Bone Jt Surg Am* 50(3):503–507
227. Sato A, Watanabe R, Nishijima H (1966) A rare case of a solitary bone cyst of the patella. *Nihon Geka Hokan* 35(1):173–175
228. Idelberger K (1964) A solitary cyst of the 4th lumbar vertebra, operated on by abdominal approach in a 48 year old man. *Rev Chir Orthop Reparatrice Appar Mot* 50:385–387
229. Devan WT (1964) Solitary bone cyst with pathological fracture complicating otherwise normal pregnancy: report of a case and discussion of fractures in etiology, pathogenesis and treatment. *Am Surg* 30:109–114
230. Clark L (1962) The influence of trauma on unicameral bone cysts. *Clin Orthop* 22:209–214
231. Ufranc OE, Jones WN, Harris WH (1961) Humeral fractures through unicameral bone cysts. *JAMA* 28(178):410–413
232. Beller ML (1952) Solitary bone cyst in the humeral mid-shaft at age five years. *Bull Hosp Jt Dis* 13(1):212–216
233. McCort JJ (1951) Weekly clinicopathological exercises: unicameral bone cyst of ischium. *N Engl J Med* 245(10):379–81
234. Kliger M (1951) Solitary bone cyst of humerus, report of case and review of some current literature. *Arch Pediatr* 68(11):518–525
235. Wu KK (1993) A surgically treated unicameral (solitary) bone cyst of the talus with a 15-year follow-up. *J Foot Ankle Surg* 32(2):242–244
236. Brogdon BG, Cottrell WC, Nimityongskul P, Takhtani D (2006) A bullet-sired bone cyst. *Skeletal Radiol* 35(12):959–963
237. Akman S, Gur B, Seekin F, Ozturk I (2002) A case of bilateral unicameral bone cyst of the calcaneus and surgical outcome. *Acta Orthop Traumatol Turc* 36(3):265–267
238. Schwartz D (2009) An 11-year-old boy with ankle trauma: unicameral bone cyst of the calcaneus. *Pediatr Ann* 38(3):132–134
239. Giddings CE, Bray D, Stapleton S, Daya H (2005) Aneurysmal bone cyst of the spine. *J Laryngol Otol* 119(6):495–497
240. Sarierler M, Cullu E, Yurekli Y, Birincioglu S (2004) Bone cement treatment for aneurysmal bone cyst in a dog. *J Vet Med Sci* 66(9):1137–1142
241. Burr BA, Resnick D, Syklawer R, Haghighi P (1993) Fluid-fluid levels in a unicameral bone cyst: CT and MR findings. *J Comput Assist Tomogr* 17(1):134–136
242. Ruggieri P, Biagini R, Picci P (1987) Case report 437: solitary (unicameral, simple) bone cyst of the scapula. *Skeletal Radiol* 16(6):493–497
243. Chaudhary D, Bhatia N, Ahmed A, Chopra RK, Malik AC, Singh AK, Rao KS (2000) Unicameral bone cyst of the patella. *Orthopedics* 23(12):1285–1286
244. Vayego SA, De Conti OJ, Varella-Garcia M (1996) Complex cytogenetic rearrangement in a case of unicameral bone cyst. *Cancer Genet Cytogenet* 86(1):46–49
245. Marsh JJ, Munk PL, Muller NL (1992) CT of a unicameral bone cyst in a rib. *Br J Radiol* 65(769):74–75
246. Weisel A, Hecht HL (1980) Development of a unicameral bone cyst. Case report. *J Bone Jt Surg Am* 62(4):664–666
247. Haims AH, Desai P, Present D, Beltran J (1997) Epiphyseal extension of a unicameral bone cyst. *Skeletal Radiol* 26(1):51–54
248. Lagier R, Kramar C, Baud CA (1987) Femoral unicameral bone cyst in a medieval child. Radiological and pathological study. *Pediatr Radiol* 17(6):498–500
249. Cebesoy O (2007) Intraosseous ganglion of the talus treated with the talonavicular joint approach without exposing the ankle joint. *J Am Podiatr Med Assoc* 97(5):424–427
250. Schopler SA, Lawrence JF, Johnson MK (1986) Lengthening of the humerus for upper extremity limb length discrepancy. *J Pediatr Orthop* 6(4):477–480
251. Sadler AH, Rosenhain F (1964) Occurrence of two unicameral bone cysts in the same patient. *J Bone Jt Surg Am* 46:1557–1560
252. Madiefsky L, Wasiak GA (1986) Outpatient surgery of a unicameral bone cyst of the calcaneus. *J Foot Surg* 25(1):73–77
253. Tynan JR, Schachar NS, Marshall GB, Gray RR (2005) Pathologic fracture through a unicameral bone cyst of the pelvis: CT-guided percutaneous curettage, biopsy, and bone matrix injection. *J Vasc Interv Radiol* 16(2 Pt 1):293–296
254. Madhavan P, Ogilvie C (1998) Premature closure of upper humeral physis after fracture through simple bone cyst. *J Pediatr Orthop B* 7(1):83–85
255. Shindell R, Connolly JF, Lippello L (1987) Prostaglandin levels in a unicameral bone cyst treated by corticosteroid injection. *J Pediatr Orthop* 7(2):210–212
256. Stearns HC III (1986) Radiologic review: unicameral bone cyst with humeral fracture. *Orthop Nurs* 5(4):43–45
257. Tyler W, Frassica FJ, McCarthy EF (2002) Recurrence of a unicameral bone cyst after nineteen years. *Orthopedics* 25(4):435–436
258. Bowen RE, Morrissy RT (2004) Recurrence of a unicameral bone cyst in the proximal part of the fibula after en bloc resection. A case report. *J Bone Jt Surg Am* 86(1):154–158
259. Lee CC, Wei JD, How SW (2000) Simple bone cyst in cervical vertebral spinous process and laminae: report of a case. *J Formos Med Assoc* 99(1):54–58
260. Violas F, Salmeron F, Chapuis M, de Sales GJ, Bracq H, Cahuzac JP (2004) Simple bone cysts of the proximal humerus complicated with growth arrest. *Acta Orthop Belg* 70(2):166–170
261. Thomas LB, Steffensen T, Walling AK, Gilbert-Barness E (2008) Simple (unicameral) bone cyst of the calcaneus: a pathologic variant revisited. *Fetal Pediatr Pathol* 27(3):141–147
262. Nager GT (1986) Solitary (unicameral) cysts involving the temporal bone. *Laryngoscope* 96(6):666–674
263. Tausend ME, Marcus M (1959) Solitary unicameral bone cyst in a seven-week-old infant. *N Engl J Med* 260(3):129–131
264. Frankel SL, Chioros PG, Sidlow CJ (1988) Steroid injection of a unicameral bone cyst of the calcaneus: literature review and two case reports. *J Foot Surg* 27(1):60–65
265. Alvarez RG, Arnold JM (2007) Technical tip: arthroscopic assistance in minimally invasive curettage and bone grafting of a calcaneal unicameral bone cyst. *Foot Ankle Int* 28(11):1198–1199
266. McGlynn FJ, Mickelson MR, El-Khoury GY (1981) The fallen fragment sign in unicameral bone cyst. *Clin Orthop Relat Res* 156:157–159
267. Tsuchihara T, Arino H, Nemoto K, Amako M, Isaki H, Fujikawa K (2008) The growth rate of the humerus: long-term follow-up of treatment of solitary bone cyst of the proximal humerus using cannulated screws: a case report. *J Pediatr Orthop B* 17(3):145–147
268. Jordanov MI (2009) The “rising bubble” sign: a new aid in the diagnosis of unicameral bone cysts. *Skeletal Radiol* 38(6):597–600
269. Taxin RN, Feldman R (1975) The tumbling bullet sign in a post-traumatic bone cyst. *Am J Roentgenol Radium Ther Nucl Med* 123(1):140–143
270. Richkind KE, Mortimer E, Mowery-Rushton P, Fraire A (2002) Translocation (16;20)(p11.2;q13). sole cytogenetic abnormality

- in a unicameral bone cyst. *Cancer Genet Cytogenet* 137(2):153–155
271. Johnston CE, Fletcher RR (1986) Traumatic transformation of unicameral bone cyst into aneurysmal bone cyst. *Orthopedics* 9(10):1441–1447
 272. Yildirim C, Mahirogullari M, Kuskucu M, Akmaz I, Keklikci K (2010) Treatment of a unicameral bone cyst of calcaneus with endoscopic curettage and percutaneous filling with corticocancellous allograft. *J Foot Ankle Surg* 49(1):93–97
 273. Moed BR, LaMont RL (1982) Unicameral bone cyst complicated by growth retardation. *J Bone Jt Surg Am* 64(9):1379–1381
 274. Prietto C, Orofino CF, Waugh TR (1977) Unicameral bone cyst in the scapula. *Clin Orthop Relat Res* 125:183–184
 275. Bone LB, Johnston CE, Bucholz RW (1986) Unicameral bone cyst. *Orthopedics* 9(8):1155–1161
 276. Yoho RM, Mandracchia VJ, Syrud JN (1996) Unicameral bone cyst. An unusual complication. *J Am Podiatr Med Assoc* 86(5):236–238
 277. Shulman HS, Wilson SR, Harvie JN, Cruickshank B (1977) Unicameral bone cyst in a rib of a child. *Am J Roentgenol* 128(6):1058–1060
 278. Grumbine NA, Clark GD (1986) Unicameral bone cyst in the calcaneus with pathologic fracture. A literature review and case report. *J Am Podiatr Med Assoc* 76(2):96–99
 279. Keret D, Kumar SJ (1987) Unicameral bone cysts in the humerus and femur in the same child. *J Pediatr Orthop* 7(6):712–715
 280. Hresko MT, Miele JF, Goldberg MJ (1988) Unicameral bone cyst in the scapula of an adolescent. *Clin Orthop Relat Res* 236:141–144
 281. Ehrlich MG, Chaglassian JH (1974) Unicameral bone cyst in the scapula. *Clin Orthop Relat Res* 103:80–81
 282. Tsirikos AI, Bowen JR (2002) Unicameral bone cyst in the spinous process of a thoracic vertebra. *J Spinal Disord Tech* 15(5):440–443
 283. Head SA (1984) Unicameral bone cyst located in metacarpal bone: report of a case. *J Am Osteopath Assoc* 84(4):372–373
 284. Snell BE, Adesina A, Wolfla CE (2001) Unicameral bone cyst of a cervical vertebral body and lateral mass with associated pathological fracture in a child. Case report and review of the literature. *J Neurosurg* 95(2 Suppl):243–245
 285. Brodsky AE, Khalil M, VanDeventer L (1986) Unicameral bone cyst of a lumbar vertebra. A case report. *J Bone Jt Surg Am* 68(8):1283–1285
 286. Hazmy CH (2004) Unicameral bone cyst of the calcaneum. *Med J Malaysia* 59 Suppl F:63–64
 287. Epstein J, Wertheimer SJ (1984) Unicameral bone cyst of the calcaneus. Literature review and case studies. *J Am Podiatry Assoc* 74(2):76–79
 288. O'Laughlin SJ (2012) Unicameral bone cyst of the calcaneus. *J Orthop Sports Phys Ther* 42(1):43
 289. Perlman MD, Maiocco JL, Rybczynski JM (1989) Unicameral bone cyst of the first metatarsal. *J Foot Surg* 28(1):38–41
 290. Randelli P, Arrigoni P, Cabitza P, Denti M (2009) Unicameral bone cyst of the humeral head: arthroscopic curettage and bone grafting. *Orthopedics* 32(1):54
 291. Wray CC (1986) Unicameral bone cyst of the ilium. *J R Coll Surg Edinb* 31(4):233–236
 292. Wu KK (1990) Unicameral bone cyst of the medial malleolus of the ankle. *J Foot Surg* 29(2):183–187
 293. Janjua KJ (1999) Unicameral bone cyst of the patella. *Am J Knee Surg* 12(2):111–113
 294. Saglik Y, Ucar DH, Yildiz HY, Dogan M (1995) Unicameral bone cyst of the patella. A case report. *Int Orthop* 19(5):280–281
 295. Wientroub S, Salama R, Baratz M, Papo I, Weissman SL (1979) Unicameral bone cyst of the patella. *Clin Orthop Relat Res* 140:159–161
 296. Martin SJ, Schiller JE (1987) Unicameral bone cyst of the second metatarsal with pathologic fracture. *J Am Podiatr Med Assoc* 77(3):143–147
 297. Chieppa WA, Shinder M (1989) Unicameral bone cyst of the talus. *J Am Podiatr Med Assoc* 79(9):441–446
 298. Gordon SL, Denton JR, McCann PD, Parisien MV (1987) Unicameral bone cyst of the talus. *Clin Orthop Relat Res* 215:201–205
 299. Nasca RJ (1988) Unicameral bone cyst of the tibia complicated by genu valgum. *South Med J* 81(10):1301–1304
 300. Malawer MM, Markle B (1982) Unicameral bone cyst with epiphyseal involvement: clinicoanatomic analysis. *J Pediatr Orthop* 2(1):71–79
 301. Deyoe L, Woodbury DF (1985) Unicameral bone cyst with fracture. *Orthopedics* 8(4):529–531
 302. Singh S, Dhammi IK, Arora A, Kumar S (2003) Unusually large solitary unicameral bone cyst: case report. *J Orthop Sci* 8(4):599–601
 303. Agerholm JC, Goodfellow JW (1965) Simple cysts of the humerus treated by radical excision. *J Bone Jt Surg Br* 47(4):714–717
 304. MacKenzie DB (1980) Treatment of solitary bone cysts by diaphysectomy and bone grafting. *S Afr Med J* 58(4):154–158
 305. Kleiger B (1969) Unicameral bone cyst, 15 year follow-up. *Bull Hosp Jt Dis* 30(1):53–58
 306. Gundes H, Sahin M, Alici T (2010) Unicameral bone cyst of the lunate in an adult: case report. *J Orthop Surg Res* 5:79
 307. Hutter CG (1950) Unicameral bone cyst; report of an unusual case. *J Bone Jt Surg Am* 32A(2):430–432
 308. Dormans JP, Dormans NJ (2004) Use of percutaneous intramedullary decompression and medical-grade calcium sulfate pellets for treatment of unicameral bone cysts of the calcaneus in children. *Orthopedics* 27(1 Suppl):s137–s139
 309. Siegel IM (1966) Brisement force with controlled collapse in treatment of solitary unicameral bone cyst. *Arch Surg* 92(1):109–114
 310. Goel AR, Kriger J, Bronfman R, Lauf E (1994) Unicameral bone cysts: treatment with methylprednisone acetate injections. *J Foot Ankle Surg* 33(1):6–15
 311. Cho HS, Seo SH, Park SH, Park JH, Shin DS, Park IH (2012) Minimal invasive surgery for unicameral bone cyst using demineralized bone matrix: a case series. *BMC Musculoskelet Disord* 13:134
 312. Shibata K, Tsunooka H, Sasaki S, Oono N, Niwa A, Oowa T, Kamio Y, Saito Y, Sumita H, Naito A (1992) A case report of solitary bone cyst of rib detected from pathological fracture. *Kyobu Geka* 45(9):817–819
 313. Zenmyo M, Komiya S, Hamada T, Inoue A (2000) A solitary bone cyst in the spinous process of the cervical spine: a case report. *Spine (Phila Pa 1976)* 25(5):641–642
 314. Nystrom L, Raw R, Buckwalter J, Morcuende JA (2008) Acute intraoperative reactions during the injection of calcium sulfate bone cement for the treatment of unicameral bone cysts: a review of four cases. *Iowa Orthop J* 28:81–84
 315. Asada Y, Suzuki I, Suzuki M, Fukushima M (1991) Atypical multiple benign osteoblastomas accompanied by simple bone cysts. A case report. *J Craniomaxillofac Surg* 19(4):166–171
 316. Taneda H, Azuma H (1994) Avascular necrosis of the femoral epiphysis complicating a minimally displaced fracture of solitary bone cyst of the neck of the femur in a child. A case report. *Clin Orthop Relat Res* 304:172–175

317. Stelling CB, Martin W, Fechner RE, Alford BA, Strider DV (1981) Case report 150. Solitary bone cyst with cementum-like bone production. *Skeletal Radiol* 6(3):213–215
318. Hahn PF, Rosenthal DI, Ehrlich MG (1984) Case report 286: gas within a solitary bone cyst of the proximal end of the left humerus. *Skeletal Radiol* 12(3):214–217
319. Schultz E, Greenspan A (1986) Case report 378: simple bone cyst (traumatized). *Skeletal Radiol* 15(5):405–407
320. Wu KK, Guise ER (1981) Unicameral bone cyst of the spine. A case report. *J Bone Jt Surg Am* 63(2):324–326
321. Abdelwahab IF, Lewis MM, Klein MJ, Barbera C (1989) Case report 515: simple (solitary) bone cyst of the calcaneus. *Skeletal Radiol* 17(8):607–610
322. Abdelwahab IF, Hermann G, Lewis MM, Klein MJ (1989) Case report 534: simple bone cyst of the acetabulum and ischium. *Skeletal Radiol* 18(2):157–159
323. Gregory JM, Arkader A, Bokhari A, Dormans JP (2010) Case report: unicameral bone cysts in a young patient with acquired generalized lipodystrophy. *Clin Orthop Relat Res* 468(5):1440–1446
324. Grabias S, Mankin HJ (1974) Chondrosarcoma arising in histologically proved unicameral bone cyst. A case report. *J Bone Jt Surg Am* 56(7):1501–1509
325. Abril JC, Queiruga JA, Casas J, Albinana J (1999) Unusual finding after contrast injection of a solitary bone cyst. A case report. *Acta Orthop Belg* 65(2):235–238
326. Mason RJ, Friedman SJ, Frassica FJ (1994) Medial meniscal cyst of the knee simulating a solitary bone lesion. A case report and review of the literature. *Clin Orthop Relat Res* 304:190–194
327. Tamir E, Halperin N, Segal M, Robinson D (1998) Sclerotic hip medullary lesion evolving into a simple bone cyst—a case report. *Acta Orthop Scand* 69(6):647–648
328. Czitrom AA, Pritzker KP (1980) Simple bone cyst causing collapse of the articular surface of the femoral head and incongruity of the hip joint. A case report. *J Bone Jt Surg Am* 62(5):842–845
329. Smith SB, Shane HS (1994) Simple bone cyst of the calcaneus. A case report and literature review. *J Am Podiatr Med Assoc* 84(3):127–130
330. Ha KY, Kim YH (2003) Simple bone cyst with pathologic lumbar pedicle fracture: a case report. *Spine (Phila Pa 1976)* 28(7):E129–E131
331. Uygur F, Ulkur E, Pehlivan O, Celikoz B (2008) Soft tissue necrosis following using calcium phosphate cement in calcaneal bone cyst: case report. *Arch Orthop Trauma Surg* 128(12):1397–1401
332. Shen Q, Jia L, Li Y (1998) Solitary bone cyst in the odontoid process and body of the axis. A case report and review of literature. *J Bone Jt Surg Br* 80(1):30–32
333. Matsumoto K, Fujii S, Mochizuki T, Hukuda S (1990) Solitary bone cyst of a lumbar vertebra. A case report and review of literature. *Spine (Phila Pa 1976)* 15(6):605–607
334. Civello IM, Butti A (1978) Sutures of nonabsorbable material as the cause of disturbances in gastrectomized patients. Considerations on 19 personal cases. *Chir Patol Sper* 26(2):131–135
335. Sguazzini VC (1967) Solitary bone cyst of the clavicle (case report). *Minerva Ortop* 18(12):870–872
336. Goldsmith E (1966) Solitary bone cyst of the distal phalanx. A case report. *J Am Podiatry Assoc* 56(2):69–70
337. Gupta AK, Crawford AH (1996) Solitary bone cyst with epiphyseal involvement: confirmation with magnetic resonance imaging. A case report and review of the literature. *J Bone Jt Surg Am* 78(6):911–915
338. Rodolico R, Nicolato A, Scaglione P (1968) Solitary osseous cyst of the calcaneus. Case reports. *Ann Radiol Diagn (Bologna)* 41(3):183–191
339. Bosch B, Bialik G, Bialik V (2002) Spontaneous epiphyseal injury as a complication of a simple bone cyst of the femoral neck? Case report and review of the literature. *Orthopade* 31(9):930–933
340. Parker ME, Samsodien MG, Wood RE (1988) The untreated, shrinking simple bone cavity: case report. *Ann Dent* 47(2):43–45
341. Herring JA, Peterson HA (1987) Simple bone cyst with growth arrest. *J Pediatr Orthop* 7(2):231–235
342. Maney WA (1967) Kiel bone in the treatment of a simple bone cyst. *Br J Clin Pract* 21(10):519–520
343. Bourne MH, Beabout JW, Wold LE, Sim FH (1986) Simple bone cysts. *Orthopedics* 9(9):1285–1289
344. Catier P, Bracq H, Canciani JP, Allouis M, Babut JM (1981) The treatment of upper femoral unicameral bone cysts in children by Ender's nailing technique. *Rev Chir Orthop Reparatrice Appar Mot* 67(2):147–149
345. Mainard D, Galois L (2006) Treatment of a solitary calcaneal cyst with endoscopic curettage and percutaneous injection of calcium phosphate cement. *J Foot Ankle Surg* 45(6):436–440
346. Nakagawa T, Kawano H, Kubota T (1994) Solitary bone cyst of the cervical spine—case report. *Neurol Med Chir (Tokyo)* 34(8):558–560
347. Vasilev V, Andreeff I, Sokolov T, Vidinov N (1987) Clinical-morphological and electron-microscopic studies of the growth plate in solitary bone cysts. *Arch Orthop Trauma Surg* 106(4):232–237
348. Sanerkin NG (1979) Old fibrin coagula and their ossification in simple bone cysts. *J Bone Jt Surg Br* 61-B(2):194–199
349. Komiya S, Tsuzuki K, Mangham DC, Sugiyama M, Inoue A (1994) Oxygen scavengers in simple bone cysts. *Clin Orthop Relat Res* 308:199–206
350. Yu J, Chang SS, Suratwala S, Chung WS, Abdelmessieh P, Lee HJ, Yang J, Lee FY (2005) Zoledronate induces apoptosis in cells from fibro-cellular membrane of unicameral bone cyst (UBC). *J Orthop Res* 23(5):1004–1012
351. Jager M, Jelinek EM, Wess KM, Scharfstadt A, Jacobson M, Kevy SV, Krauspe R (2009) Bone marrow concentrate: a novel strategy for bone defect treatment. *Curr Stem Cell Res Ther* 4(1):34–43
352. Yu CL, D'Astous J, Finnegan M (1991) Simple bone cysts. The effects of methylprednisolone on synovial cells in culture. *Clin Orthop Relat Res* 262:34–41
353. Gerasimov AM, Toporova SM, Furtseva LN, Berezhnoy AP, Vilensky EV, Alekseeva RI (1991) The role of lysosomes in the pathogenesis of unicameral bone cysts. *Clin Orthop Relat Res* 266:53–63
354. Vayego-Lourenco SA (2001) TP53 mutations in a recurrent unicameral bone cyst. *Cancer Genet Cytogenet* 124(2):175–176
355. Komiya S, Kawabata R, Zenmyo M, Hashimoto S, Inoue A (2000) Increased concentrations of nitrate and nitrite in the cyst fluid suggesting increased nitric oxide synthesis in solitary bone cysts. *J Orthop Res* 18(2):281–288
356. Zehetgruber H, Bittner B, Gruber D, Krepler P, Trieb K, Kotz R, Dominkus M (2005) Prevalence of aneurysmal and solitary bone cysts in young patients. *Clin Orthop Relat Res* 439:136–143
357. Becker WH (1952) Differential diagnosis of solitary bone cysts from giant cell tumors. *Munch Med Wochenschr* 94(36):1799–1804
358. Lee FY, Schoeb JS, Yu J, Christiansen BD, Dick HM (2005) Operative lengthening of the humerus: indications, benefits, and complications. *J Pediatr Orthop* 25(5):613–616
359. Sullivan RJ, Meyer JS, Dormans JP, Davidson RS (1999) Diagnosing aneurysmal and unicameral bone cysts with magnetic resonance imaging. *Clin Orthop Relat Res* 366:186–190
360. Levine E, Neff JR (1983) Dynamic computed tomography scanning of benign bone lesions: preliminary results. *Skeletal Radiol* 9(4):238–245

361. Pireau N, De GA, Mainard-Simard L, Lascombes P, Docquier PL (2011) Fracture risk in unicameral bone cyst. Is magnetic resonance imaging a better predictor than plain radiography? *Acta Orthop Belg* 77(2):230–238
362. Clayer M, Boatright C, Conrad E (1997) Growth disturbances associated with untreated benign bone cysts. *Aust N Z J Surg* 67(12):872–873
363. Lodwick GS (1958) Juvenile unicameral bone cyst; a roentgen reappraisal. *Am J Roentgenol Radium Ther Nucl Med* 80(3):495–504
364. Margau R, Babyn P, Cole W, Smith C, Lee F (2000) MR imaging of simple bone cysts in children: not so simple. *Pediatr Radiol* 30(8):551–557
365. Ahn JI, Park JS (1994) Pathological fractures secondary to unicameral bone cysts. *Int Orthop* 18(1):20–22
366. Caviglia H, Garrido CP, Palazzi FF, Meana NV (2005) Pediatric fractures of the humerus. *Clin Orthop Relat Res* 432:49–56
367. Lee JH, Reinus WR, Wilson AJ (1999) Quantitative analysis of the plain radiographic appearance of unicameral bone cysts. *Invest Radiol* 34(1):28–37
368. Struhl S, Edelson C, Pritzker H, Seimon LP, Dorfman HD (1989) Solitary (unicameral) bone cyst. The fallen fragment sign revisited. *Skeletal Radiol* 18(4):261–265
369. Morton KS (1964) The pathogenesis of unicameral bone cyst. *Can J Surg* 7:140–150
370. Kaelin AJ, MacEwen GD (1989) Unicameral bone cysts. Natural history and the risk of fracture. *Int Orthop* 13(4):275–282
371. Reinus WR, Wilson AJ (1995) Quantitative analysis of solitary lesions of bone. *Invest Radiol* 30(7):427–432
372. Yandow SM, Marley LD, Fillman RR, Galloway KS (2009) Precordial Doppler evaluation of simple bone cyst injection. *J Pediatr Orthop* 29(2):196–200
373. Norman A, Schiffman M (1977) Simple bone cysts: factors of age dependency. *Radiology* 124(3):779–782
374. Hammoud S, Weber K, McCarthy EF (2005) Unicameral bone cysts of the pelvis: a study of 16 cases. *Iowa Orthop J* 25:69–74
375. Brodetti A (1956) The weight bearing capacity of the femoral neck with solitary bone cyst. *Acta Orthop Scand* 26(2):81–98
376. Docquier PL, Paul L, Menten R, Cartiaux O, Francq B, Banse X (2009) Measurement of bone cyst fluid volume using k-means clustering. *Magn Reson Imaging* 27(10):1430–1439
377. Vasconcellos DA, Yandow SM, Grace AM, Moritz BM, Marley LD, Fillman RR (2007) Cyst index: a nonpredictor of simple bone cyst fracture. *J Pediatr Orthop* 27(3):307–310
378. Ortiz EJ, Isler MH, Navia JE, Canosa R (2005) Pathologic fractures in children. *Clin Orthop Relat Res* 432:116–126
379. Reynolds J (1969) The “fallen fragment sign” in the diagnosis of unicameral bone cysts. *Radiology* 92(5):949–953
380. Amling M, Werner M, Posl M, Maas R, Korn U, Delling G (1995) Calcifying solitary bone cyst: morphological aspects and differential diagnosis of sclerotic bone tumours. *Virchows Arch* 426(3):235–242
381. Yanagawa T, Watanabe H, Shinozaki T, Takagishi K (2009) Curettage of benign bone tumors without grafts gives sufficient bone strength. *Acta Orthop* 80(1):9–13
382. Shrader MW, Schwab JH, Shaughnessy WJ, Jacofsky DJ (2009) Pathologic femoral neck fractures in children. *Am J Orthop (Belle Mead NJ)* 38(2):83–86
383. Mnaymneh WA, Ghandur-Mnaymneh L, Chaglassian J (1973) Unicameral bone cyst. Appraisal of experience at the American University Hospital of Beirut. *J Med Liban* 26(4):459–470
384. Sakamoto A, Matsuda S, Yoshida T, Iwamoto Y (2010) Clinical outcome following surgical intervention for a solitary bone cyst: emphasis on treatment by curettage and steroid injection. *J Orthop Sci* 15(4):553–559
385. Haidar SG, Culliford DJ, Gent ED, Clarke NM (2011) Distance from the growth plate and its relation to the outcome of unicameral bone cyst treatment. *J Child Orthop* 5(2):151–156
386. Fillingham YA, Lenart BA, Gitelis S (2012) Function after injection of benign bone lesions with a bioceramic. *Clin Orthop Relat Res* 470(7):2014–2020
387. Glowacki M, Ignys-O’Byrne A, Ignys I, Wroblewska K (2011) Limb shortening in the course of solitary bone cyst treatment—a comparative study. *Skeletal Radiol* 40(2):173–179
388. Sturz H, Zenker H, Buckl H (1979) Total subperiosteal resection treatment of solitary bone cysts of the humerus. *Arch Orthop Trauma Surg* 93(3):231–239
389. Morton KS (1982) Unicameral bone cyst. *Can J Surg* 25(3):330–332
390. Tey IK, Mahadev A, Lim KB, Lee EH, Nathan SS (2009) Active unicameral bone cysts in the upper limb are at greater risk of fracture. *J Orthop Surg (Hong Kong)* 17(2):157–160
391. Stanton RP, Abdel-Mota’al MM (1998) Growth arrest resulting from unicameral bone cyst. *J Pediatr Orthop* 18(2):198–201
392. Garceau GJ, Gregory CF (1954) Solitary unicameral bone cyst. *J Bone Joint Surg Am* 36(A:2):267–280
393. Matthiass HH, Immenkamp M (1976) Surgical treatment of solitary bone cysts. *Recent Results Cancer Res* 54:231–238
394. Yajima H, Murata K, Kawamura K, Kawate K, Takakura Y (2008) Treatment of intraosseous ganglia and bone cysts of the carpal bones with injectable calcium phosphate bone cement. *Hand Surg* 13(3):167–173
395. Garcia Filho RJ, Dos Santos JB, Korukian M, Laredo FJ (1992) Conservative treatment of solitary bone cysts—a study of 55 patients. *Rev Paul Med* 110(3):131–137
396. Givon U, Sher-Lurie N, Schindler A, Ganel A (2004) Titanium elastic nail—a useful instrument for the treatment of simple bone cyst. *J Pediatr Orthop* 24(3):317–318
397. Chaves D (1980) Treatment of solitary cysts of the humerus. Treated by diaphyseal resection and bone grafting. *Int Orthop* 3(4):253–256
398. Biermann JS (2002) Common benign lesions of bone in children and adolescents. *J Pediatr Orthop* 22(2):268–273
399. Abdel-Wanis ME, Tsuchiya H (2002) Simple bone cyst is not a single entity: point of view based on a literature review. *Med Hypotheses* 58(1):87–91
400. Robins PR, Peterson HA (1972) Management of pathologic fractures through unicameral bone cysts. *JAMA* 222(1):80–81
401. Neer CS, Francis KC, Johnston AD, Kiernan HA Jr (1973) Current concepts on the treatment of solitary unicameral bone cyst. *Clin Orthop Relat Res* 97:40–51
402. Leclert H, Adamsbaum C (1998) Intraosseous cyst injection. *Radiol Clin North Am* 36(3):581–587
403. Wilkins RM (2000) Unicameral bone cysts. *J Am Acad Orthop Surg* 8(4):217–224
404. Capanna R, Campanacci DA, Manfrini M (1996) Unicameral and aneurysmal bone cysts. *Orthop Clin North Am* 27(3):605–614
405. Makley JT, Joyce MJ (1989) Unicameral bone cyst (simple bone cyst). *Orthop Clin North Am* 20(3):407–415
406. Kruls HJ (1979) Pathological fractures in children due to solitary bone cysts. *Reconstr Surg Traumatol* 17:113–118
407. Iorio R, Betz RR, Clancy MJ (1989) Treatment options in simple unicameral bone cysts. *Orthopedics* 12(6):877–878
408. Donaldson S, Chundamala J, Yandow S, Wright JG (2010) Treatment for unicameral bone cysts in long bones: an evidence based review. *Orthop Rev (Pavia)* 2(1):e13
409. Baig R, Eady JL (2006) Unicameral (simple) bone cysts. *South Med J* 99(9):966–976
410. Dormans JP, Pill SG (2002) Fractures through bone cysts: unicameral bone cysts, aneurysmal bone cysts, fibrous cortical

- defects, and nonossifying fibromas. *Instr Course Lect* 51:457–467
411. Lokiec F, Wientroub S (1998) Simple bone cyst: etiology, classification, pathology, and treatment modalities. *J Pediatr Orthop B* 7(4):262–273
 412. Hecht AC, Gebhardt MC (1998) Diagnosis and treatment of unicameral and aneurysmal bone cysts in children. *Curr Opin Pediatr* 10(1):87–94
 413. Chaney SL, Karp NE (1981) The use of freeze-dried bone allografts: a review of the literature with special emphasis on their use in treatment of solitary bone cysts. *J Foot Surg* 20(1):41–43
 414. Cohen J (1977) Unicameral bone cysts. A current synthesis of reported cases. *Orthop Clin North Am* 8(4):715–736
 415. Peltier LF, Jones RH (1978) Treatment of unicameral bone cysts by curettage and packing with plaster-of-Paris pellets. *J Bone Jt Surg Am* 60(6):820–822
 416. Moore TM (1982) Orthopedics-important advances in clinical medicine: injection of steroid agents in solitary bone cysts. *West J Med* 137(5):408–409
 417. Weinert CR (1989) Administering steroids in unicameral bone cysts. *West J Med* 150(6):684–685
 418. Namazi H (2008) Practice pearl: a novel use of botulinum toxin for unicameral bone cyst ablation. *Ann Surg Oncol* 15(2):657–658
 419. Savastano AA (1979) The treatment of bone cysts with intracyst injection of steroids. Injection of steroids will largely replace surgery in the treatment of benign bone cysts. *R I Med J* 62:93–95
 420. Galasko CS (1974) Letter: the fate of simple bone cysts which fracture. *Clin Orthop Relat Res* (101):302–304
 421. Matsumine A, Myoui A, Kusuzaki K, Araki N, Seto M, Yoshikawa H, Uchida A (2004) Calcium hydroxyapatite ceramic implants in bone tumour surgery. A long-term follow-up study. *J Bone Jt Surg Br* 86(5):719–725
 422. Gebhart M, Blaimont P (1996) Contribution to the vascular origin of the unicameral bone cyst. *Acta Orthop Belg* 62(3):137–143
 423. Innami K, Takao M, Miyamoto W, Abe S, Nishi H, Matsushita T (2011) Endoscopic surgery for young athletes with symptomatic unicameral bone cyst of the calcaneus. *Am J Sports Med* 39(3):575–581
 424. Shindell R, Huurman WW, Lippiello L, Connolly JF (1989) Prostaglandin levels in unicameral bone cysts treated by intralesional steroid injection. *J Pediatr Orthop* 9(5):516–519
 425. Fernbach SK, Blumenthal DH, Poznanski AK, Dias LS, Tachdjian MO (1981) Radiographic changes in unicameral bone cysts following direct injection of steroids: a report on 14 cases. *Radiology* 140(3):689–695
 426. Lindell L (1963) Solitary unicameral bone cyst in childhood. *Ann Chir Gynaecol Fenn* 52:80–92
 427. Glaser DL, Dormans JP, Stanton RP, Davidson RS (1999) Surgical management of calcaneal unicameral bone cysts. *Clin Orthop Relat Res* 360:231–237
 428. Moreau G, Letts M (1994) Unicameral bone cyst of the calcaneus in children. *J Pediatr Orthop* 14(1):101–104
 429. Kanellopoulos AD, Mavrogenis AF, Papagelopoulos PJ, Soucacos PN (2007) Elastic intramedullary nailing and DBM-bone marrow injection for the treatment of simple bone cysts. *World J Surg Oncol* 5:111
 430. Abdel-Wanis ME, Tsuchiya H, Uehara K, Tomita K (2002) Minimal curettage, multiple drilling, and continuous decompression through a cannulated screw for treatment of calcaneal simple bone cysts in children. *J Pediatr Orthop* 22(4):540–543
 431. Thawrani D, Thai CC, Welch RD, Copley L, Johnston CE (2009) Successful treatment of unicameral bone cyst by single percutaneous injection of alpha-BSM. *J Pediatr Orthop* 29(5):511–517
 432. Saraph V, Zwick EB, Maizen C, Schneider F, Linhart WE (2004) Treatment of unicameral calcaneal bone cysts in children: review of literature and results using a cannulated screw for continuous decompression of the cyst. *J Pediatr Orthop* 24(5):568–573
 433. Killian JT, Wilkinson L, White S, Brassard M (1998) Treatment of unicameral bone cyst with demineralized bone matrix. *J Pediatr Orthop* 18(5):621–624
 434. Yandow SM, Lundeen GA, Scott SM, Coffin C (1998) Autogenic bone marrow injections as a treatment for simple bone cyst. *J Pediatr Orthop* 18(5):616–620
 435. Lokiec F, Ezra E, Khermash O, Wientroub S (1996) Simple bone cysts treated by percutaneous autologous marrow grafting. A preliminary report. *J Bone Jt Surg Br* 78(6):934–937
 436. Delloye C, Docquier PL, Cornu O, Poilvache P, Peters M, Woitrin B, Rombouts JJ, De Nayer P (1998) Simple bone cysts treated with aspiration and a single bone marrow injection. A preliminary report. *Int Orthop* 22(2):134–138
 437. Symeonides PP, Economou CJ, Papadimitriou J (1977) Solitary bone cyst of the calcaneus. *Int Surg* 62(1):24–26
 438. Pedzisz P, Zgoda M, Kocon H, Benke G, Gorecki A (2010) Treatment of solitary bone cysts with allogenic bone graft and platelet-rich plasma. A preliminary report. *Acta Orthop Belg* 76(3):374–379
 439. Rosenborg M, Karlsson A, Hirsch G, Mortensson W (1992) Contrast medium injected into juvenile bone cysts to analyze interior morphology and guide intracavity corticosteroid treatment. *Acta Radiol* 33(3):221–224
 440. El-Adl G, Mostafa MF, Enan A, Ashraf M (2009) Biphasic ceramic bone substitute mixed with autogenous bone marrow in the treatment of cavitory benign bone lesions. *Acta Orthop Belg* 75(1):110–118
 441. Rud B, Pedersen NW, Thomsen PB (1991) Simple bone cysts in children treated with methylprednisolone acetate. *Orthopedics* 14(2):185–187
 442. Gartland JJ, Cole FL (1975) Modern concepts in the treatment of unicameral bone cysts of the proximal humerus. *Orthop Clin North Am* 6(2):487–498
 443. Robbins H (1982) The treatment of unicameral or solitary bone cysts by the injection of corticosteroids. *Bull Hosp Jt Dis Orthop Inst* 42(1):1–16
 444. Komiya S, Minamitani K, Sasaguri Y, Hashimoto S, Morimatsu M, Inoue A (1993) Simple bone cyst. Treatment by trepanation and studies on bone resorptive factors in cyst fluid with a theory of its pathogenesis. *Clin Orthop Relat Res* 287:204–211
 445. Santori F, Ghera S, Castelli V (1988) Treatment of solitary bone cysts with intramedullary nailing. *Orthopedics* 11(6):873–878
 446. Kose N, Gokturk E, Turgut A, Gunal I, Seber S (1999) Percutaneous autologous bone marrow grafting for simple bone cysts. *Bull Hosp Jt Dis* 58(2):105–110
 447. Arazi M, Senaran H, Memik R, Kapicioglu S (2005) Minimally invasive treatment of simple bone cysts with percutaneous autogenous bone marrow injection. *Orthopedics* 28(2):108–112
 448. Sporer P, Urban K, Urbanova E, Karpas K, Mathew PG (2010) Behavior of bioactive glass-ceramic implanted into long bone defects: a scintigraphic study. *J Pediatr Orthop B* 19(1):102–107
 449. Morii T, Mochizuki K, Satomi K (2009) Continuous decompression using a cannulated ceramic pin for simple bone cysts. *J Orthop Surg (Hong Kong)* 17(1):62–66
 450. Chigira M, Maehara S, Arita S, Udagawa E (1983) The aetiology and treatment of simple bone cysts. *J Bone Jt Surg Br* 65(5):633–637

451. Vigler M, Weigl D, Schwarz M, Ben-Itzhak I, Salai M, Bar-On E (2006) Subtrochanteric femoral fractures due to simple bone cysts in children. *J Pediatr Orthop B* 15(6):439–442
452. Ovadia D, Ezra E, Segev E, Hayek S, Keret D, Wientroub S, Lokiec F (2003) Epiphyseal involvement of simple bone cysts. *J Pediatr Orthop* 23(2):222–229
453. Tang XY, Liu LJ, Peng MX, Xiang B (2006) Simple bone cysts in children treated with intracystic fibrin sealant injection. *Chin Med J (Engl)* 119(6):523–525
454. Scaglietti O, Marchetti PG, Bartolozzi P (1979) The effects of methylprednisolone acetate in the treatment of bone cysts. Results of three years follow-up. *J Bone Jt Surg Br* 61(2):200–204
455. Capanna R, Van HJ, Ruggieri P, Biagini R (1986) Epiphyseal involvement in unicameral bone cysts. *Skeletal Radiol* 15(6):428–432
456. Capanna R, Albisinni U, Caroli GC, Campanacci M (1984) Contrast examination as a prognostic factor in the treatment of solitary bone cyst by cortisone injection. *Skeletal Radiol* 12(2):97–102
457. Bensahel H, Jehanno P, Desgrippes Y, Pennecot GF (1998) Solitary bone cyst: controversies and treatment. *J Pediatr Orthop B* 7(4):257–261
458. Chigira M, Shimizu T, Arita S, Watanabe H, Heshiki A (1986) Radiological evidence of healing of a simple bone cyst after hole drilling. *Arch Orthop Trauma Surg* 105(3):150–153
459. Campanacci M, De SL, Trentani C (1977) Scaglietti's method for conservative treatment of simple bone cysts with local injections of methylprednisolone acetate. *Ital J Orthop Traumatol* 3(1):27–36
460. Roposch A, Saraph V, Linhart WE (2004) Treatment of femoral neck and trochanteric simple bone cysts. *Arch Orthop Trauma Surg* 124(7):437–442
461. Spence KF, Sell KW, Brown RH (1969) Solitary bone cyst: treatment with freeze-dried cancellous bone allograft. A study of one hundred seventy-seven cases. *J Bone Jt Surg Am* 51(1):87–96
462. Docquier PL, Delloye C (2003) Treatment of simple bone cysts with aspiration and a single bone marrow injection. *J Pediatr Orthop* 23(6):766–773
463. Dormans JP, Sankar WN, Moroz L, Erol B (2005) Percutaneous intramedullary decompression, curettage, and grafting with medical-grade calcium sulfate pellets for unicameral bone cysts in children: a new minimally invasive technique. *J Pediatr Orthop* 25(6):804–811
464. Bensahel H (1976) Treatment of the solitary bone cyst in children. *Nouv Presse Med* 5(11):711–712
465. Salama R, Weissman SL (1978) The clinical use of combined xenografts of bone and autologous red marrow. A preliminary report. *J Bone Jt Surg Br* 60(1):111–115
466. Burwell RG (1964) Studies in the transplantation of bone. VII. The fresh composite homograft of cancellous bone, an analysis of factors leading to osteogenesis in marrow transplantations and in marrow-containing bone grafts. *J Bone Jt Surg Br* 46:110–140