

# Diagnostic dilemma in gastric varices: Endoscopic ultrasound resolves the issue (with videos)

Malay Sharma, Parvinder Singh<sup>1</sup>, Amit Pathak, Shalini Arya<sup>2</sup>

Department of Gastroenterology, Jaswant Rai Speciality Hospital, Meerut, <sup>2</sup>Department of Medicine, Muzaffarnagar Medical College, Muzaffarnagar, Uttar Pradesh, <sup>3</sup>Department of Surgical Gastroenterology, Guru Gobind Singh Medical College and Hospital, Faridkot, Punjab, India

Gastroesophageal varices are one of the most serious complications of portal hypertension. One-third of patients with varices develop variceal hemorrhage.<sup>[1]</sup> Bleeding from gastric varices is more severe and is associated with higher morbidity, transfusion requirements and mortality than esophageal varices.<sup>[2]</sup> Despite significant improvements in various treatment modalities, mortality due to bleeding from gastric varices remains very high.<sup>[2]</sup> Gastric varices are usually classified as per Sarin's endoscopic classification, which is based on the endoscopic appearance and location of the varices.<sup>[3]</sup> Sometimes gastric varices are mistaken for large gastric folds or submucosal tumors and endoscopic ultrasound (EUS) helps in differentiating them.<sup>[4]</sup> EUS is useful in identifying the collateral pathways and inflowing and out flowing perforators.<sup>[5]</sup> EUS has also been used in evaluation and injection of glue into perforators and paragastric varices.<sup>[6]</sup> We are presenting a case of isolated gastric varices (IGV2), in which there was diagnostic dilemma with a differential diagnosis of submucosal tumor. The dilemma was resolved by EUS.

The 65-year-old lady presented in an emergency with complain of massive upper gastrointestinal (GI) bleed and shock requiring several units of packed cells for resuscitation. Investigations before the transfusions revealed hemoglobin (Hb) 4.6 g%, total lymphocyte count 8200, differential leukocyte count polymorphs 68%, lymphocytes 32%, blood urea 30 mg/dL, Serum creatinine 1.1 mg/dL, serum bilirubin 9 mg/dL, aspartate aminotransferase 38 U/L (normal: 14-40 U/L), alanine aminotransferase 28 U/L (normal: 10-40 U/L), and an alkaline phosphatase value of 135 U/L (normal: 38-126 U/L). The markers for hepatitis B and C were negative. Ultrasound abdomen in emergency revealed a portal vein diameter of 11 mm and a normal liver with mild splenomegaly. After 8 h of resuscitation, repeat Hb was 9.6 g%, and the patient was hemodynamically stable. An upper GI endoscopy revealed normal esophagus and fundus of the stomach. Examination of the body of the stomach on retroflexion showed the following pictures [Figures 1a-c]. An EUS was done [Figures 2a-c].<sup>[2]</sup> The diagnosis of isolated submucosal gastric varices

Videos Available on: [www.eusjournal.com](http://www.eusjournal.com)

Access this article online

Quick Response Code:



Website:

[www.eusjournal.com](http://www.eusjournal.com)

DOI:

10.4103/2303-9027.199764

This is an open access article distributed under the terms of the Creative Commons Attribution-NonCommercial-ShareAlike 3.0 License, which allows others to remix, tweak, and build upon the work non-commercially, as long as the author is credited and the new creations are licensed under the identical terms.

For reprints contact: [reprints@medknow.com](mailto:reprints@medknow.com)

**How to cite this article:** Sharma M, Singh P, Pathak A, Arya S. Diagnostic dilemma in gastric varices: Endoscopic ultrasound resolves the issue (with videos). *Endosc Ultrasound* 2017;6:409-11.

## Address for correspondence

Dr. Malay Sharma, Department of Gastroenterology, Jaswant Rai Speciality Hospital, Meerut, Uttar Pradesh, India.

E-mail: [sharmamalay@hotmail.com](mailto:sharmamalay@hotmail.com)

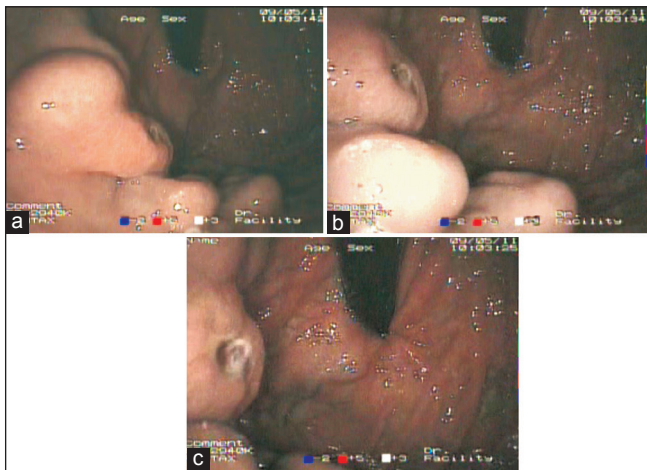
Received: 2014-08-01; Accepted: 2015-08-29

was suspected from endoscopic appearance, and the confirmation was done by EUS. An EUS was also able to show the inflowing and outflowing perforators to the gastric varices [Figure 3 Videos 1 and 2]. Two milliliter of n-butylcyanoacrylate glue was injected into the varices and a repeat EUS after glue injection showed absence of blood signals in submucosa of the stomach wall [Figure 4]. Follow-up ultrasound showed coarse echo-texture of liver and a diagnosis of cirrhosis of the liver was made.

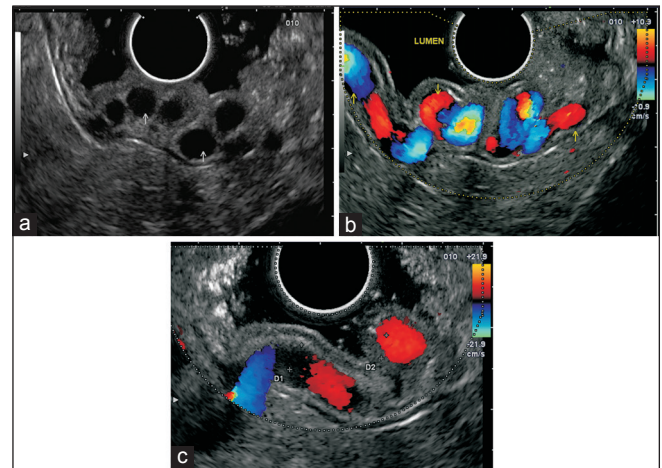
Variceal bleed is a major cause of morbidity and mortality in case of portal hypertension. Gastric variceal bleeding is more severe and associated with a worse outcome compared with esophageal varices.<sup>[2]</sup> The ulceration on gastric varices without any intervention is uncommon, and it produces diagnostic dilemma especially in the setting of IGV type II. In this case there was ulceration of varix without

any prior treatment. Hence, there was suspected differential diagnosis of ulcerated submucosal tumor as patient had normal liver on ultrasonography and no esophago-fundal varices. This diagnostic dilemma was resolved by EUS. The computed tomography angiogram or magnetic resonance angiogram can also show the IGV2, but the layer-wise relationship of the varices to the stomach wall is difficult to establish.

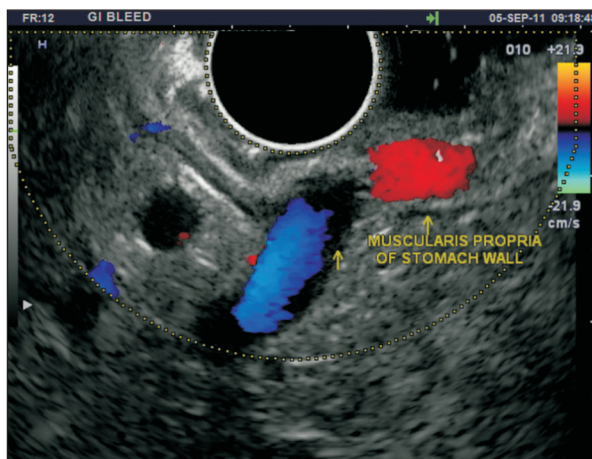
Once the diagnosis is confirmed glue injection is the preferred therapy for gastric varices.<sup>[7]</sup> In this case glue injection was given in the IGV2 after confirmation of the diagnosis and patient responded well to treatment. The confirmation of satisfactory glue injection was made by a follow-up EUS. The other possible option of obliteration of gastric varices is by coil injection.<sup>[8]</sup>



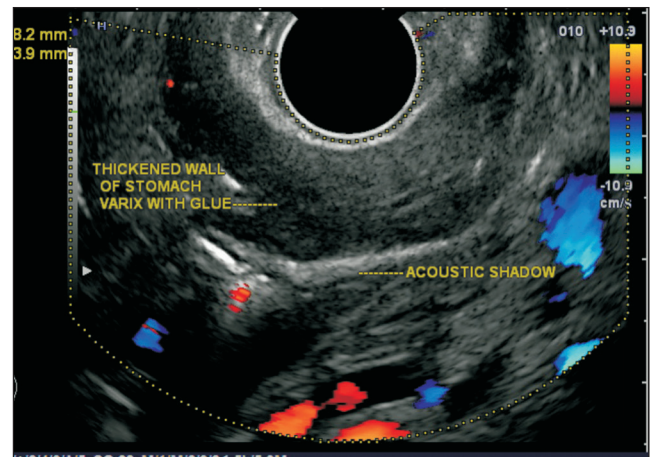
**Figure 1.** (a) Examination of the body of the stomach on retroflexion showed a large submucosal bulge in the body of stomach (b) There were multiple smaller bulges near the large bulging area (c) The largest bulge had central ulceration



**Figure 2.** (a) An endoscopic ultrasound showed anechoic areas in submucosa, which showed color flow on application of color Doppler (b) An endoscopic ultrasound showed anechoic areas in submucosa which showed color flow on application of color Doppler (c) The outflowing perforator was identified by the blue coloured flow of the varix through the muscularis propria



**Figure 3.** The perforator could be traced to the para gastric varices



**Figure 4.** Endoscopic ultrasound after glue injection showed absence of blood signals in submucosa of stomach wall

Endoscopic ultrasound is an excellent diagnostic modality for diagnostic evaluation of gastric varices and is useful in resolving the dilemma if the diagnosis of gastric varices is in doubt.

#### *Financial support and sponsorship*

Nil.

#### *Conflicts of interest*

There are no conflicts of interest.

#### REFERENCES

1. Rosolowski M, Hartleb M, Marek T, *et al.* Therapeutic and prophylactic management of bleeding from oesophageal and gastric varices – Recommendations of the Working Group of the National Consultant for Gastroenterology. *Prz Gastroenterol* 2014;9:63-8.
2. Al-Osaimi AM, Caldwell SH. Medical and endoscopic management of gastric varices. *Semin Intervent Radiol* 2011;28:273-82.
3. Sarin SK, Kumar A. Gastric varices: Profile, classification, and management. *Am J Gastroenterol* 1989;84:1244-9.
4. Seicean A. Endoscopic ultrasound in the diagnosis and treatment of upper digestive bleeding: A useful tool. *J Gastrointestin Liver Dis* 2013;22:465-9.
5. Sharma M, Rameshbabu CS. Collateral pathways in portal hypertension. *J Clin Exp Hepatol* 2012;2:338-52.
6. Sharma M, Goyal A. Bleeding after glue injection in gastric varices. Rebleeding from a glue ulcer. *Gastroenterology* 2012;142:e1-2.
7. Cheng LF, Wang ZQ, Li CZ, *et al.* Low incidence of complications from endoscopic gastric variceal obturation with butyl cyanoacrylate. *Clin Gastroenterol Hepatol* 2010;8:760-6.
8. Romero-Castro R, Ellrichmann M, Ortiz-Moyano C, *et al.* EUS-guided coil versus cyanoacrylate therapy for the treatment of gastric varices: A multicenter study (with videos). *Gastrointest Endosc* 2013;78:711-21.