

**POSTER PRESENTATION**

**Open Access**

# Free-breathing with motion-correction and video projection during cardiac MRI: a paediatric design!

Laurent Bonnemains<sup>1,2\*</sup>, Freddy Odille<sup>2,3</sup>, Aboubaker Cherifi<sup>5</sup>, Pierre-Yves Marie<sup>4,3</sup>, Cedric Pasquier<sup>5,2</sup>, Jacques Felblinger<sup>2,3</sup>

From 17th Annual SCMR Scientific Sessions  
New Orleans, LA, USA. 16-19 January 2014

## Background

Cardiac magnetic resonance imaging with children is a complex exam because it requires cooperation of the children to stay motionless and perform multiple breath-holding. This issue is particularly acute for fibrosis detection with late gadolinium enhancement which requires strict immobility during acquisition. In many situations, children must undergo general anaesthesia because such cooperation is too difficult to obtain. However, 1/cooperation and stillness is easily obtained when children are proposed funny derivative occupation (such as movies to watch) during the exam and 2/the blurring effect induced by free-breathing can be corrected by a retrospective non-rigid adaptive motion correction algorithm such as GRICS (Odille, MRM 2008).

## Methods

We present an alternative solution based on GRICS (non-rigid adaptive ungated motion correction method) and on simple basic equipment (special glasses, screen, and video projector) as illustrated in Figure 1A. GRICS requires the use of two respiratory belts to record the thorax motions during the examination, in order to correct it during the image reconstruction process. We were able to organize full cardiac MRI examinations

(Cine-MRI before and after gadolinium, Phase contrast for aortic flow and myocardial delayed enhancement) with GRICS for four Duchene children (mean = 9 years old) in complete free breathing and with almost no instruction given to the children from the MR operator during the exams.

## Results

Exams were easily performed. Every children found the experience enjoyable. For three of them, the exam revealed diffuse fibrosis in the lateral or infero-lateral segments, as illustrated in Figure 1C and 1D, whereas the images before injection were normal and no alteration of ejection fraction was noted.

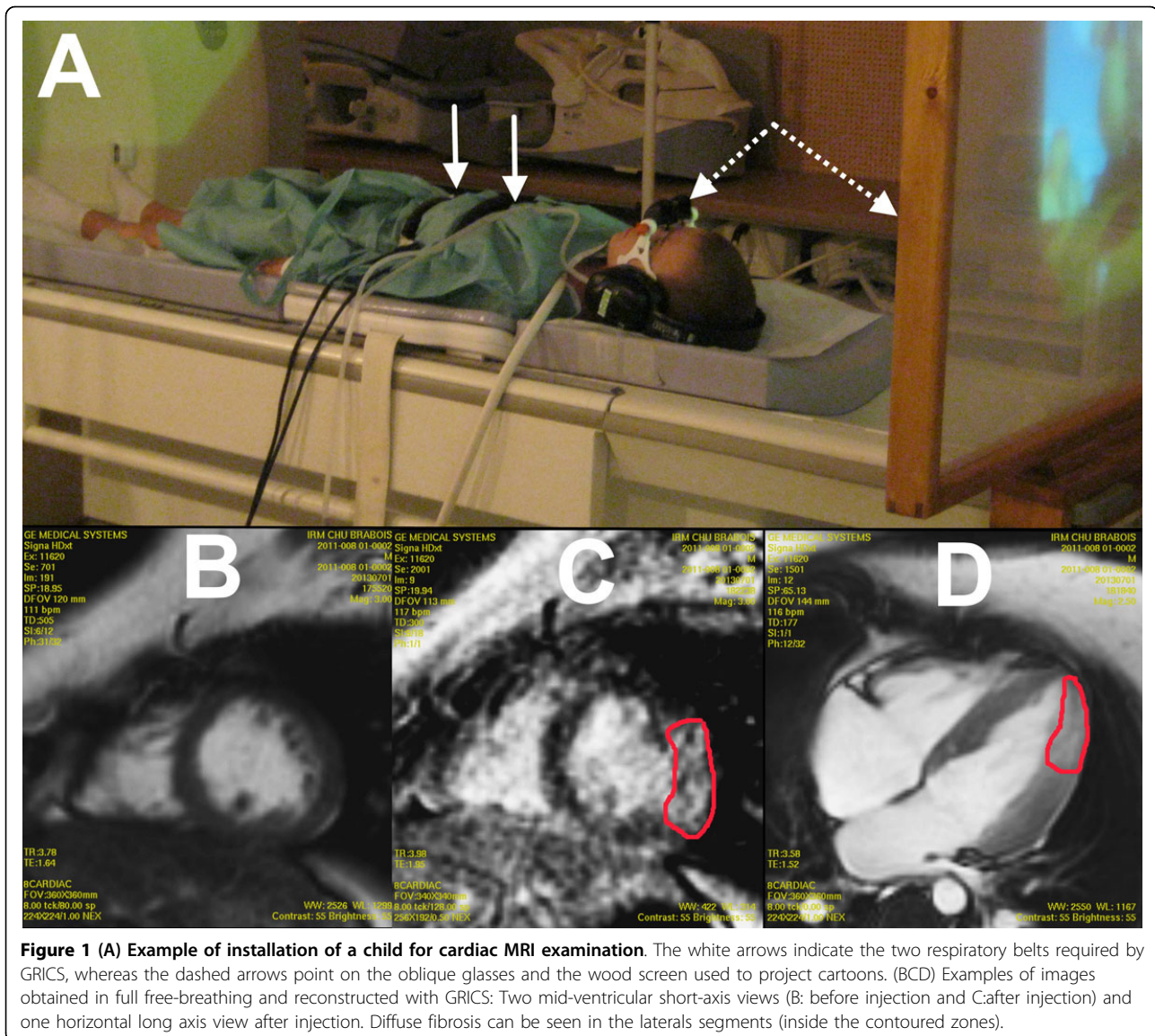
## Conclusions

Paediatric complete free-breathing cardiac MRI is feasible with GRICS and simple video equipment. GRICS greatly simplifies the organisation of cardiomyopathy MRI examination with young children. This is the first report of the use of GRICS with patients.

## Funding

Joint funding from INSERM, France and AFM, France (French Association against Myopathy) under the ID C13-04.

<sup>1</sup>Cardiology, CHU Nancy, Nancy, France  
Full list of author information is available at the end of the article



**Authors' details**

<sup>1</sup>Cardiology, CHU Nancy, Nancy, France. <sup>2</sup>INSERM,U947, Nancy, France.  
<sup>3</sup>Université de Lorraine, Nancy, France. <sup>4</sup>Radiology, CHU Nancy, Nancy, France. <sup>5</sup>CICIT 801, CHU Nancy, Nancy, France.

Published: 16 January 2014

doi:10.1186/1532-429X-16-S1-P319

Cite this article as: Bonnemains *et al.*: Free-breathing with motion-correction and video projection during cardiac MRI: a paediatric design. *Journal of Cardiovascular Magnetic Resonance* 2014 **16**(Suppl 1):P319.

Submit your next manuscript to BioMed Central and take full advantage of:

- Convenient online submission
- Thorough peer review
- No space constraints or color figure charges
- Immediate publication on acceptance
- Inclusion in PubMed, CAS, Scopus and Google Scholar
- Research which is freely available for redistribution

Submit your manuscript at  
[www.biomedcentral.com/submit](http://www.biomedcentral.com/submit)

