

Success Rate of MTA Pulpotomy on Vital Pulp of Primary Molars: A 3-Year Observational Study

¹Brinda Godhi, ²Rishi Tyagi

ABSTRACT

Introduction: Vital pulp therapy is a major contributor in the preservation of primary dentition after caries affliction. Introduction of mineral trioxide aggregate (MTA) has revolutionized such treatment.

Aim: The aim of our study was to evaluate and correlate the effects of MTA clinically and radiographically on pulpotomized primary molars till their exfoliation or extraction followed by histological evaluation.

Study design: This is an observational study.

Materials and methods: A total of 25 teeth were selected from 5- to 8-year-old children requiring pulp therapy on the basis of inclusion and exclusion criterion. The teeth were treated by conventional pulpotomy technique under aseptic conditions using MTA and were immediately restored with stainless steel crown. The teeth were assessed postoperatively till 36 months. The exfoliated or extracted teeth were examined histologically.

Results: The pulpotomized teeth were vital with no adverse clinical findings during the observation period. After 3 months, one tooth showed internal resorption, but the same was not observed after 12 months. Pulp canal obliteration was seen in three cases. At the end of the study, five teeth were exfoliated and one tooth was extracted for maintaining arch symmetry. The histological examination of extracted tooth revealed the presence of healthy pulp and the area of true calcification. Remaining exfoliated teeth presented dentin bridge formation.

Statistics: Frequencies and percentages were used for descriptive statistics. Fisher's exact tests were used to see the difference between clinical and radiological findings. The probability value was fixed at 5% level of significance.

Conclusion: The response of pulp in primary teeth to MTA was favorable in all cases from clinical and radiographic perspective, and histological evaluation confirmed the observation.

Keywords: Mineral trioxide aggregate, Primary molars, Pulpotomy.

How to cite this article: Godhi B, Tyagi R. Success Rate of MTA Pulpotomy on Vital Pulp of Primary Molars: A 3-Year Observational Study. *Int J Clin Pediatr Dent* 2016;9(3):222-227.

Source of support: Nil

Conflict of interest: None

INTRODUCTION

Pulpotomy is still the most common treatment for cariously exposed pulps in symptom-free primary molars. The aim of this treatment was to preserve the vitality of radicular pulp, avoiding pain and swelling, and ultimately to retain the tooth, preserving arch integrity. Several materials have been used as popular pulpotomy medicaments. Formocresol is one such pulpotomy medicament that has been in use for the past 70 years.¹ Even with acceptable clinical and radiographic results, concerns have been raised about formocresol, because of its association with systemic toxicity and carcinogenic potential in humans, and its safety in children has been questioned.²⁻⁴ Alternatives have been proposed to maintain the radicular pulp's vitality. These include electrosurgery,^{5,6} laser,⁷ glutaraldehyde,^{8,9} ferric sulfate,¹⁰ bone morphogenetic protein,¹¹ and osteogenic protein.¹²

Pulpotomy has been broadly classified as devitalization, preservation, and regeneration of the remaining pulp tissue.¹³ One material that has shown immense potential for regeneration is mineral trioxide aggregate (MTA). It is a biocompatible and bioinductive material that has been investigated for endodontic applications since the early 1990s. Mineral trioxide aggregate was first described in the dental scientific literature in 1993¹⁴ and was given approval for endodontic use by the US Food and Drug Administration in 1998.¹⁵

Mineral trioxide aggregate pulpotomy has been studied clinically and radiologically extensively and compared with other pulpotomy medicaments, and it has been concluded that MTA can be an acceptable alternative. There are few studies in the literature where the response of human pulp to MTA has been histologically studied.¹⁶⁻¹⁸ Hence, this study was conducted to evaluate and correlate the effects of MTA clinically and radiographically on pulpotomized primary molars till their exfoliation or extraction followed by histological evaluation.

¹Reader, ²Associate Professor

¹Department of Pedodontics, JSS Dental College and Hospital Sri Jagadguru Sri Shivarathreshwara University, Mysuru Karnataka, India

²Department of Pedodontics, UCMS and GTB Hospital, New Delhi, India

Corresponding Author: Brinda Godhi, Reader, Department of Pedodontics, JSS Dental College and Hospital, Sri Jagadguru Sri Shivarathreshwara University, Mysuru, Karnataka, India Phone: +917259749417, e-mail: drbrinda7@yahoo.co.in

MATERIALS AND METHODS

Ethical clearance to conduct the study was obtained from the Institutional Review Board. The procedure, possible discomfort, and benefits were explained to parents of the children involved, and written consent was obtained.

A total of 25 maxillary and mandibular primary molar teeth were selected from 19 normal, healthy, and cooperative children aged between 5 and 8 years, requiring pulp therapy from the patients attending the Department of Pedodontics and Preventive Dentistry, ITS Center for Dental Studies and Research, Ghaziabad, Uttar Pradesh, India. Intraexaminer agreement was done using kappa coefficients. The agreement was found to be 100%.

The criteria for selection of teeth to be included in the study are given below.

Inclusion Criteria

- Symptomless primary molars with a deep carious lesion.
- Exposure of vital pulp due to dental caries.
- No clinical and radiographic evidence of inflamed pulp, pulp degeneration, such as excessive bleeding from root canal, swelling or sinus tract, internal resorption, interradicular bone destruction, no periapical bone destruction, and no radiolucency in furcation area.
- Pulp shall be uninfamed and no pain on percussion clinically.
- Teeth should be restorable after completion of the procedure.

Exclusion Criteria

- Excessive bleeding during pulp amputation.
- Nonvital teeth.

Primary molars were treated by conventional pulpotomy technique using local anesthesia and isolating the teeth with rubber dam. After caries removal with round bur, coronal access was obtained using a #330 high-speed bur with water spray to expose the pulp chamber. The deroofing of pulp chamber was done by connecting the pulp horns by a nonend-cutting bur. The coronal pulp was excised until root canal orifices, with no tags remaining on the pulpal floor using Hu-Friedy sharp spoon excavator. After the pulp was amputated, the pulp chamber was irrigated with saline to wash away dentin debris. Following irrigation, sterile, saline-wetted cotton pellets were applied for 5 minutes on the amputated pulp stumps to achieve hemostasis. After the standardized technique, pulp stumps were covered with MTA paste that is obtained by mixing MTA powder with distilled water provided by manufacturer in 3:1 (powder-liquid) ratio.

Then, the mixture was compressed against the exposure site with a moist cotton pellet. Wet cotton pellet was placed in pulp chamber, and cavity was covered with intermediate restorative material (IRM). In the second session 1 day after, patients were recalled and cotton pellet was removed. Cavity was restored with IRM, and intra-oral periapical radiographs were taken. Within 1 week, the tooth was restored with a preformed stainless steel crown.

After 1, 3, 6, 12, 24, and 36 months, the children were recalled for clinical and radiographic examination postoperatively. The children were examined clinically, for the presence of signs and symptoms, such as pain, swelling, and sinus/fistula, and radiographically for periapical changes, furcation radiolucency, and internal resorption.

The treatment was regarded as a failure when one or more of the above-mentioned signs and symptoms were present, but pulp canal obliteration was not regarded as a failure. During the follow-up, if the treated teeth exfoliate or extraction was done for balancing, the arch will be subjected to histological examination and it will be taken as success of the treatment.

Histologic Study

Exfoliated teeth were kept in 10% buffered formalin solution for minimum 24 hours and were decalcified in 5% nitric acid for 3 weeks. Six-micrometer-thick sections were cut with a microtome in buccolingual direction and stained with hematoxylin and eosin and viewed under light microscope. The sections were evaluated by the pathologist according to the criteria described in Table 1.

The frequencies and percentages were used for descriptive statistics. Fisher's exact tests were used to see the difference between clinical and radiological findings. The probability value was fixed at 5% level of significance. Data were statistically analyzed by Statistical Package for the Social Sciences software version 17.

Table 1: Sections graded – modified scoring system adapted from Stanley (1–3) (Kot et al 1995)¹⁹

1 Dentin bridge formation	0 – No presence of bridge formation
	1 – Bridge formation <25%
	2 – 25% bridge formation <50%
	3 – 50% bridge formation <75%
2 Quality of dentin formation in the dentin	4 – Bridge formation 75%
	0 – No tubules present
	1 – Irregular pattern of tubules
	2 – Regular pattern of tubules
3 Pulpal inflammation	0 – No inflammation
	1 – Mild inflammation present
	2 – Moderate inflammation
	3 – Severe inflammation

RESULTS

Out of 25 selected teeth, 6 were first primary molars and 19 were second primary molars. The age of the subjects ranged from 5 to 8 years with mean (\pm standard deviation) age (years) 6.44 (\pm 1.12).

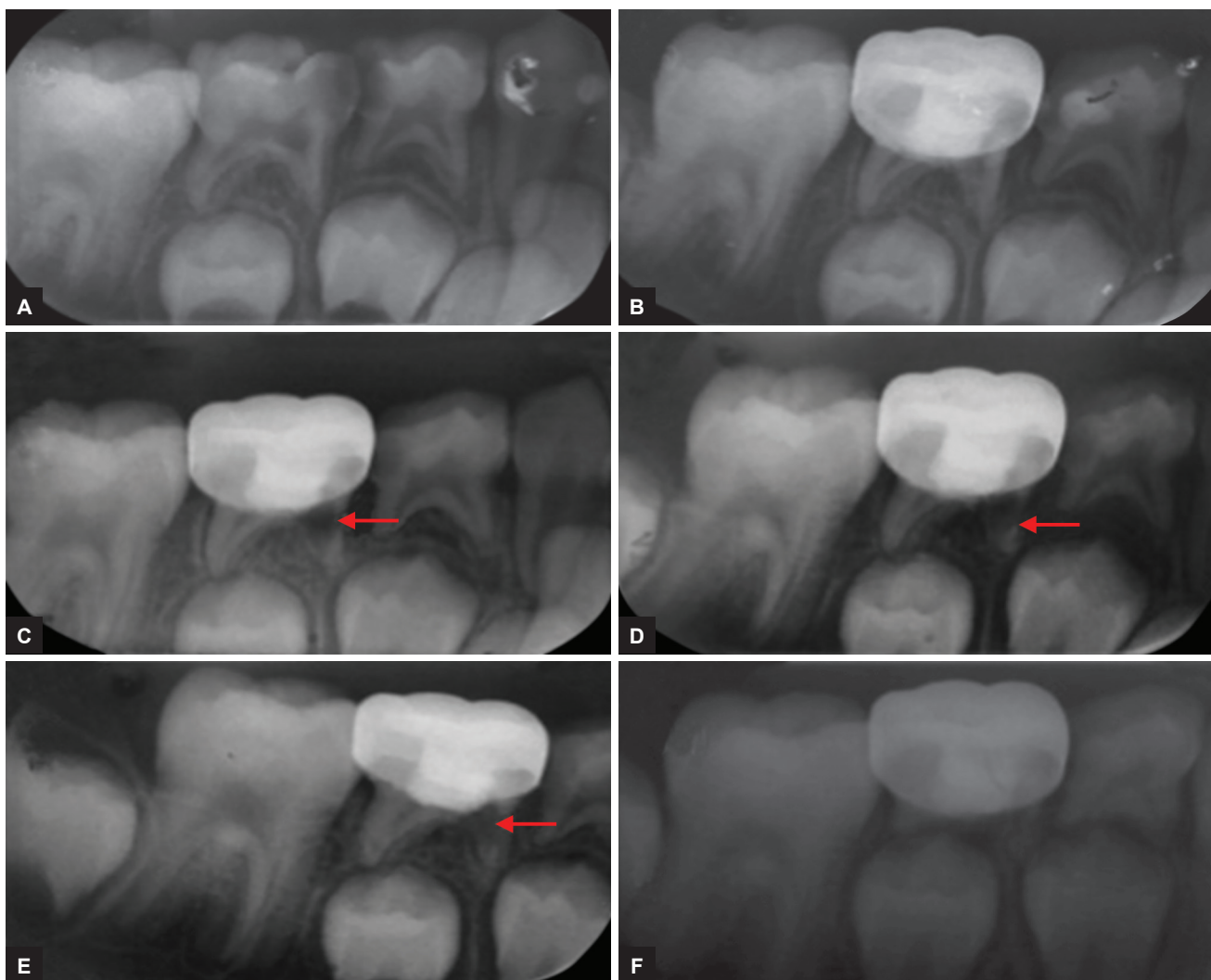
The follow-up evaluation revealed 100% success for clinical signs and symptoms for all 25 teeth at 1, 3, 6, 12, 24, and 36 months when observed by the same observer. The radiographic evaluation at 3 months revealed internal resorption with one tooth, but the same was not observed after 12 months; during the follow-up period of 24 and 36 months, internal resorption was found to be arrested and pulp tissue was replaced by calcified tissue, with tooth being clinically asymptomatic (Figs 1A to F). Pulp canal obliteration was found in the three cases and was not considered as failure. Out of 25 teeth, treated 24 teeth did not show any

radiographic changes, giving 96% success at the end of 12 months, and it increased to 100% success at the end of 36 months because one tooth that showed internal resorption at the end of 12 months was found to be arrested and pulp tissue was replaced by calcified tissue. So this tooth was not considered as failure. There were no significant differences after 1, 3, 6, 12, 24, and 36 months' evaluation periods for clinical and radiographic success (Table 2).

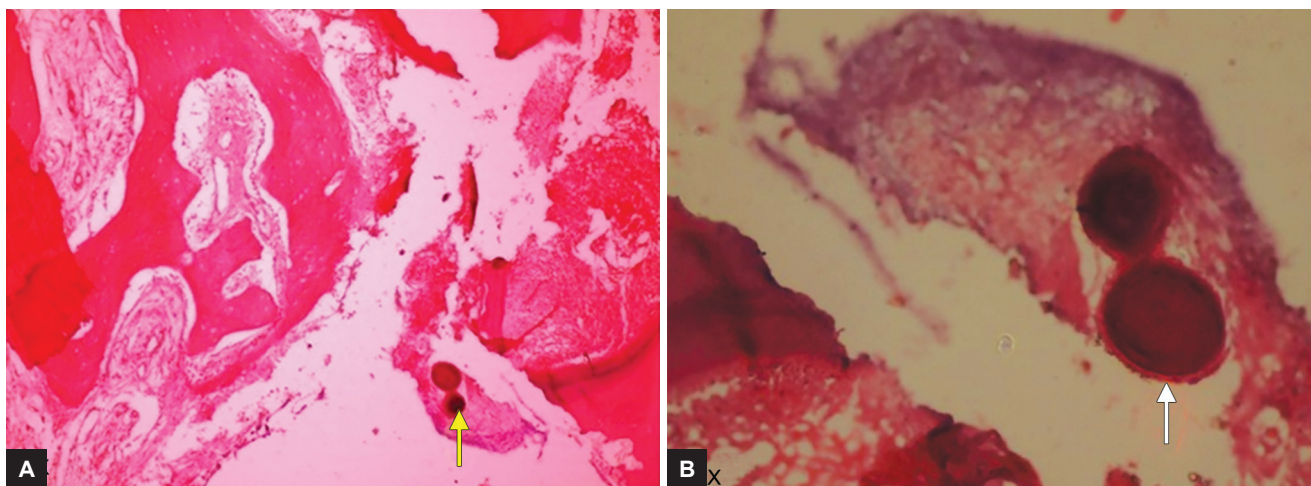
Table 2: Success rate of clinical and radiological outcome

Follow-up (months)	Clinical success	Radiological success	p-value
3	25 (100%)	24 (96%)	1.000 NS
6	25 (100%)	24 (96%)	1.000 NS
12	25 (100%)	24 (96%)	1.000 NS
24	25 (100%)	25 (100%)	–
36	25 (100%)	25 (100%)	–

NS: Nonsignificant



Figs 1A to F: Preoperative and postoperative radiograph of mandibular second primary molar treated with MTA pulpotomy revealed internal resorption; (A) Preoperative radiograph; (B) postoperative radiograph taken immediately after MTA pulpotomy and restored with stainless steel crown; (C) radiograph taken 3 months postoperatively showing feature of failure in pulpotomy; (D) radiograph taken 6 months postoperatively showing feature of failure in pulpotomy; (E) radiograph taken 24 months postoperatively showing internal resorption found to be arrested, and pulp tissue was replaced by calcified tissue; and (F) radiograph taken 36 months postoperatively showing normal physiologic resorption



Figs 2A and B: Photomicrograph of a section of tooth treated with MTA showing globular calcified mass

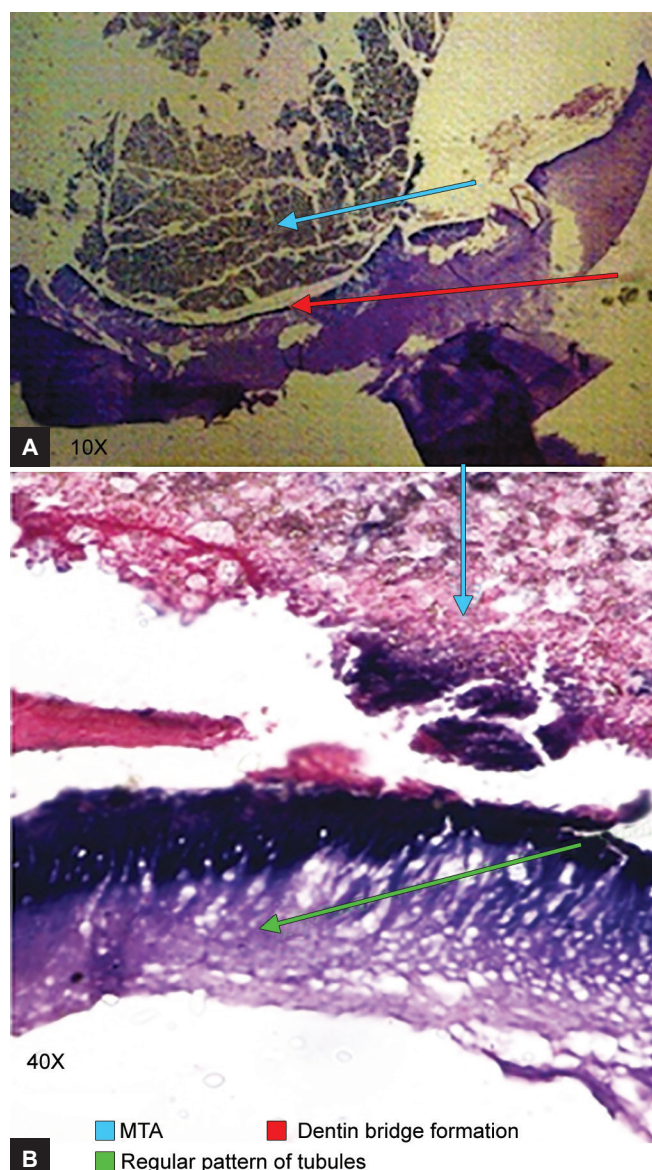
At the end of the study, six (24%) teeth were available for histological examination: Five teeth were exfoliated, and one tooth was extracted for maintaining arch symmetry. The histological examination of extracted tooth previously that showed internal resorption revealed the presence of healthy pulp and the area of true calcification (Figs 2A and B). Remaining exfoliated teeth presented dentin bridge formation >25% but <50% with five teeth showing regular pattern of tubules (Figs 3A and B) and one tooth with irregular pattern.

DISCUSSION

In this study, clinically, the success rate was 100% at all observation periods. The results are in agreement with the results of various previous studies.²⁰⁻²⁵ The clinical success was attributable to proper case selection, high aseptic standards, proper technique protocol, appropriate use of medicament, excellent sealing ability of the material, biocompatibility, alkalinity, and ability to regenerate the hard tissues.²⁶

Radiographically, one tooth showed internal resorption at 3 months interval, which did not progress to perforate the root any further over a period of next 9 months. Similar findings were seen at a duration of 25 to 38 months in two cases in a study by Holan et al²⁷ and at a duration of 12 months by Jabbarifar et al²⁸ respectively.

Initially, it was taken as failure, but during the follow-up at 24 months, there was arrest of progression of internal resorption process with replacement by calcified material. This has been reported earlier in a study by Holan et al.²⁷ Smith et al²⁹ and Papagiannoulis³⁰ have reported arrest of progression of internal resorption with ferric sulfate pulpotomy. Internal resorption may result from overstimulation of primary pulp by the highly alkaline calcium hydroxide. This highly alkaline-induced



Figs 3A and B: Photomicrograph of a section of tooth treated with MTA showing dentin bridge formation and regular pattern of tubules

overstimulation could cause metaplasia within the pulp tissue, leading to the formation of odontoblasts. Although MTA does not contain calcium hydroxide, calcium oxide is formed after MTA hardening, which can react with tissue fluids to produce calcium hydroxide.³¹ According to Seux et al,³² after contact with pulp tissue, MTA presents some structures that are similar to calcite crystals found in calcium hydroxide. They attract fibronectin, i.e., generally responsible for cellular adhesion and differentiation, as do calcium hydroxide. Therefore, we believe that the mechanism of action of MTA is similar to that of calcium hydroxide.³³

The aim of pulpotomy was to retain a symptom-free, functional primary tooth until it reaches the age of its physiologic exfoliation. This definition allows the inclusion of any condition and process that is symptom-free and does not impair the tooth's function. Internal resorption fits this definition, as long as it is not associated with external inflammatory root resorption. Internal resorption can, therefore, be left for follow-up, expecting the arrest of the process and the development of calcific metamorphosis.²⁷ It could also be more likely the result of undiagnosed chronic inflammation existing in radicular pulp prior to pulpotomy.³⁴

The histological examination revealed the presence of healthy pulp and the area of true calcification in one tooth and dentin bridge formation, i.e., >25% but <50% with regular pattern of dental tubules in remaining five teeth. Similar findings were seen in study on maxillary third molars by Aeinehchi et al,¹⁶ Iwamoto et al,³⁵ Caicedo et al¹⁸ on primary teeth. Chacko and Kurikose,¹⁷ in a study on first premolars pulp capping with MTA, have shown homogeneous dentin bridge formation at 4 and 8 weeks. Chueh and Chiang³⁶ concluded that, when caries and bacterial contamination is removed from the dentin-pulp complex, the inflamed but vital pulp of a permanent tooth may have a chance to return to a healthy, functional status after MTA pulpotomy.

In this observational study (36 months), histological response showed healthy pulp, dentin bridge formation, and areas of true calcifications under MTA.

CONCLUSION

Mineral trioxide aggregate on amputated pulpal tissue seems to suggest that the material preserves the pulp tissue and promotes the regeneration of hard tissues. We were fortunate enough to follow-up for 3 years, and treated teeth that exfoliated eventually have been correlated histologically. Pulp remained healthy after 3 years of application of MTA on pulpotomized primary molars. The whole aim of pulpotomy was maintaining integrity

of the pulp. Mineral trioxide aggregate has maintained it. Mineral trioxide aggregate has a biological potential for healing and repair. So it can be recommended as a replacement for pulpotomy procedures.

REFERENCES

1. Milnes AR. Persuasive evidence that formocresol use in pediatric dentistry is safe. *J Can Dent Assoc* 2006 Apr;72(3):247-248.
2. Hingston EJ, Parmer S, Hunter ML. Vital pulpotomy in the primary dentition: attitudes and practices of community dental staff in Wales. *Int J Paediatr Dent* 2007 May;17(3):186-191.
3. Casas MJ, Kenny DJ, Judd PL, Johnston DH. Do we still need formocresol in pediatric dentistry? *J Can Dent Assoc* 2005 Nov;71(10):749-751.
4. Judd PL, Kenny DJ. Formocresol concerns: a review. *J Can Dent Assoc* 1987 May;53(5):401-404.
5. Shaw DW, Sheller B, Barras BD, Morton TH. Electrosurgical pulpotomy: a 6 months study in primates. *J Endod* 1987 Oct;13(10):500-505.
6. Ruemping DR, Morton TH Jr, Anderson MW. Electrosurgical pulpotomy in primates – a comparison with formocresol pulpotomy. *Pediatr Dent* 1983 Mar;5(1):14-18.
7. Shoji S, Nakamura M, Horiuchi H. Histopathological changes in dental pulps irradiated by CO₂ laser: a preliminary report on laser pulpotomy. *J Endod* 1985 Sep;11(9):379-384.
8. García-Godoy F, Ranly DM. Clinical evaluation of pulpotomies with ZOE as the vehicle of glutaraldehyde. *Pediatr Dent* 1987 Jun;9(2):144-146.
9. Fuks AB, Bimstein E, Klein H, Guelmann M. Assessment of a 2% buffered glutaraldehyde solution in pulpotomized primary teeth of schoolchildren. *ASDC J Dent Child* 1990 Sep-Oct;57(5):371-375.
10. Fei AL, Udin RD, Johnson R. A clinical study of ferric sulfate as a pulpotomy agent in primary teeth. *Pediatr Dent* 1991 Nov-Dec;13(6):327-332.
11. Nakashima M. The induction of reparative dentine in the amputated dental pulp of the dog by bone morphogenetic protein. *Arch Oral Biol* 1990;35(7):493-497.
12. Rutherford RB, Wahle J, Tucker M, Roger D, Charette M. Induction of reparative dentine formation in monkeys by recombinant human osteogenic protein-1. *Arch Oral Biol* 1993 Jul;38(7):571-576.
13. Ranly DM. Pulpotomy therapy in primary teeth: new modalities for old rationales. *Pediatr Dent* 1994 Nov-Dec;16(6):403-409.
14. Lee SJ, Monsef M, Torabinejad M. Sealing ability of a mineral trioxide aggregate for repair of lateral root perforations. *J Endod* 1993 Nov;19(11):541-544.
15. Schwartz RS, Mauger M, Clement DJ, Walker WA III. Mineral trioxide aggregate: a new material for endodontics. *J Am Dent Assoc* 1999 Jul;130(7):967-975.
16. Aeinehchi M, Eslami B, Ghanbariha M, Saffar AS. Mineral trioxide aggregate (MTA) and calcium hydroxide as pulp capping agents in human teeth: a preliminary report. *Int Endod J*. 2003 Mar;36(3):225-231.
17. Chacko V, Kurikose S. Human pulpal response to mineral trioxide aggregate (MTA): a histologic study. *J Clin Pediatr Dent* 2006 Spring;30(3):203-210.
18. Caicedo R, Abbott PV, Alongi DJ, Alarcon MY. Clinical radiographic and histological analysis of the effects of mineral

- trioxide aggregate used in direct pulp capping and pulpotomies of primary teeth. *Aust Dent J* 2006 Dec;51(4):297-305.
19. Koh ET, Pittford TR, Torabinejad M, McDonold F. Mineral trioxide aggregate stimulates cytokine production in human osteoblasts. *J Bone Min Res* 1995;10S, S406.
 20. Eidelman E, Holan G, Fuks AB. Mineral trioxide aggregate *vs* formocresol in pulpotomized primary molars: a preliminary report. *Pediatr Dent* 2001 Jan-Feb;23(1):15-18.
 21. Agamy HA, Bakry NS, Mounir MM, Avery DR. Comparison of mineral trioxide aggregate and formocresol as pulp capping agents in pulpotomized primary teeth. *Pediatr Dent* 2004 Jul-Aug;26(4):302-309.
 22. Farsi N, Alamoudi N, Balto K, Mushayt A. Success of mineral trioxide aggregate in pulpotomized primary molars. *J Clin Pediatr Dent* 2005 Summer;29(4):307-311.
 23. Moretti AB, Sakai VT, Oliveira TM, Fornetti AP, Santos CF, Machado MA, Abdo RC. The effectiveness of mineral trioxide aggregate, calcium hydroxide and formocresol for pulpotomies in primary teeth. *Int Endod J* 2008 Jul;41(7):547-555.
 24. Subramaniam P, Konde S, Mathew S, Sugnani S. Mineral trioxide aggregate as pulp capping agent for primary: 2 year follow-up study. *J Clin Pediatr Dent* 2009 Summer;33(4):311-314.
 25. Godhi B, Sood PB, Sharma A. Effect of mineral trioxide and formocresol on vital pulp after pulpotomy of primary molars: An *in vivo* study. *Contemp Clin Dent* 2011 Oct;2(4):296-301.
 26. Torabinejad M, Chivian N. Clinical applications of mineral trioxide aggregate. *J Endod* 1999 Mar;25(3):197-205.
 27. Holan G, Eidelman E, Fuks AB. Long-term evaluation of pulpotomy in primary molars using mineral trioxide aggregate or formocresol. *Pediatr Dent* 2005 Mar-Apr;27(2):129-136.
 28. Jabbarifar SE, Khademi D, Ghasemi D. Success rate of formocresol in pulpotomy versus mineral trioxide aggregate in human primary molar tooth. *J Res Med Sci* 2004 Dec;6(6):304-307.
 29. Smith NL, Seale NS, Nunn ME. Ferric sulfate pulpotomy in primary molars: a retrospective study. *Pediatr Dent* 2000 May-Jun;22(3):192-199.
 30. Papagiannoulis L. Clinical studies on ferric sulphate as a pulpotomy medicaments in primary teeth. *Eur J Paediatr Dent* 2002 Sep;3(3):126-132.
 31. Koh ET, McDonald F, Pittford TR, Torabinejad M. Cellular response to mineral trioxide aggregate. *J Endod* 1998 Aug;24(8):543-547.
 32. Seux D, Coulbe ML, Hartmann DJ, Gauthier JP, Magloire H. Odontoblast-like cytodifferentiation of human dental pulp cells *in vitro* in the presence of a calcium hydroxide-containing cement. *Arch Oral Biol* 1991;36(2):117-128.
 33. Faraco IM Jr, Holland R. Response of pulp of dogs to capping with mineral trioxide aggregate or a calcium hydroxide cement. *Dent Traumatol* 2001 Aug;17(4):163-166.
 34. Sonmez D, Sari S, Cetinbas T. A comparison of four pulpotomy techniques in primary molars: a long term follow-up. *J Endod* 2008 Aug;34(8):950-955.
 35. Iwamoto CE, Erika A, Pameijer CH, Barnes D, Romberg EE, Jefferies S. Clinical and histological evaluation of white ProRoot MTA in direct pulp capping. *Am J Dent* 2006 Apr;19(2):85-90.
 36. Chueh LH, Chiang CP. Histology of irreversible pulpitis premolars treated with mineral trioxide aggregate pulpotomy. *Oper Dent* 2010 May-Jun;35(3):370-374.