

CASE REPORT

How can we manage Bezold abscess emergency in COVID-19 pandemic? Blind ceftriaxone and metronidazole treatment to avoid infection spread[†]

Alfonso Scarpa^{1,‡}, Arianna Di Stadio^{2,‡}, Pietro De Luca^{1,*}, Matteo Calvanese¹, Pasquale Viola³, Domenico Tassone⁴, Luca de Campora⁴, Matteo Simone⁴, Giampietro Ricci², Daniela Messineo⁵, Massimo Ralli⁶ and Claudia Cassandro⁷

¹Department of Medicine, Surgery and Dentistry, University of Salerno, Salerno, Italy, ²Department of Otolaryngology, University of Perugia, Perugia, Italy, ³Department of Experimental and Clinical Medicine, Unit of Audiology, Regional Centre for Cochlear Implants and ENT Diseases, Magna Graecia University, Catanzaro, Italy, ⁴Otolaryngology Department, San Giovanni-Addolorata Hospital, Rome, Italy, ⁵Radiology Oncology and Anatomopathological Department, University La Sapienza, Rome, Italy, ⁶Organ of Sense Department, University La Sapienza, Rome, Italy and ⁷Department of Otolaryngology, University of Turin, Turin, Italy

*Correspondence address. Department of Medicine, Surgery and Dentistry. University of Salerno, Salerno, Italy. E-mail: dr.dlp@hotmail.it

Abstract

Bezold abscess (BA) can be a rare complication of different forms of otitis media. We describe a rare case of BA determined by *Escherichia Coli*. Because of COVID-19 restriction, the surgery had to be delayed up to the swab results. To avoid infection spread, the patient was treated by blind antibiotic treatment until the surgical drainage of mastoid and neck. Thanks to the treatment with broad-spectrum antibiotics, the progression and the spread of the infection during COVID-19 investigation was avoided. Delayed surgery could expose the patient to the risk of severe brain infection caused by the *E. Coli*.

INTRODUCTION

Bezold abscess (BA) can be a rare complication of acute, chronic or cholesteatomatous otitis media [1]; the infection can be determined by several pathogens, e.g. *Streptococcus* [2]. Some of these pathogens can be more dangerous than others [2] and the infection has to be immediately treated to avoid risk of spreading in the surrounding tissues [1–8].

Very few cases of BA have been described in the literature (Table 1) and, in none of these, the presence of *Escherichia Coli* in the BA was specifically found; *E. Coli* can be very harmful if not promptly and adequately treated and, especially during COVID-19 era, in which all surgical procedures are slightly delayed after the result of COVID-19 swab, the delay in treating the bacterial infection may expose patients to the risk of worsening the

[†]The study has been approved by the International Review Board of the hospital without release of ID in respect of law country for these types of studies.

[‡]A. Scarpa and A. Di Stadio contributed equally to this article.

Received: September 6, 2021. Accepted: October 8, 2021

Published by Oxford University Press and JSCR Publishing Ltd. © The Author(s) 2021.

This is an Open Access article distributed under the terms of the Creative Commons Attribution Non-Commercial License (<https://creativecommons.org/licenses/by-nc/4.0/>), which permits non-commercial re-use, distribution, and reproduction in any medium, provided the original work is properly cited. For commercial re-use, please contact journals.permissions@oup.com

Table 1. The table shows the cases of BA reported in the literature

Author	Year	Number of cases	Sex	Age	Culture	Remarks
Lyoubi et al.	2020	1	M	62	Polymicrobial	/
Rodrigues Silva et al.	2020	1	M	67	Polymicrobial	Necrotizing fasciitis of the shoulder with extension to the chest
Polony et al.	2020	1	F	76	/	Cholesteatoma, left sigmoid sinus and jugular bulb thrombosis
Lindquist et al.	2020	1	F	66	/	Advanced cervical cancer on chemotherapy, temporal bone paraganglioma, cholesteatoma and necrotizing fasciitis
Malik et al.	2019	1	M	55	<i>Staphylococcus epidermidis</i>	Osteomyelitis
Al-Zahid et al.	2019	1	M	49	/	/
Eswaran et al.	2019	1	F	15	<i>Mycobacterium tuberculosis</i>	TBC
Yaita et al.	2018	1	F	70	<i>Streptococcus constellatus</i>	Lemierre's syndrome
Mustafa et al.	2018	1	F	14	<i>Streptococcus pneumoniae</i>	Right lateral sinus thrombosis
Syngh et al.	2018	1	M	38	<i>M. tuberculosis</i>	TBC
Nasir et al.	2017	1	M	52	<i>Klebsiella pneumoniae</i>	/
Zer Toros et al.	2017	1	M	45	<i>S. constellatus</i>	Left cholesteatoma associated with ipsilateral lateral sinus thrombophlebitis and meningitis
Katayama et al.	2017	1	M	52	<i>S. pneumoniae</i>	/
Quoraishi et al.	2017	1	M	44	No growth	Citelli's abscess
Lin et al.	2015	1	M	49	<i>K. pneumoniae</i>	/
Pradhananga et al.	2014	1	F	14	/	Cholesteatoma
Mantsopoulos et al.	2015	1	/	/	/	/
Nelson et al.	2013	1	F	12	<i>Streptococcus pyogenes</i>	/
Nawas et al.	2013	1	M	74	<i>Pseudomonas aeruginosa</i>	/
Lionello et al.	2013	1	M	35	Negative	
Li et al.	2012	1	F	32	/	Cholesteatoma
Janardhan et al.	2012	1	M	60	/	Cholesteatoma
Secko et al.	2012	1	M	32	/	HIV
Vlastos et al.	2012	1	F	3	/	Osteomyelitis
Sheikh et al.	2011	1	M	26	Ziehl-Neelsen stain-positive	/
Mascarinas et al.	2010	1	F	77	<i>Streptococcus viridans</i>	Prior soft palate squamous cell carcinoma and chemo and radiation therapies
Patel et al.	2010	1	M	35	/	HIV
McMullan et al.	2009	1	M	8	No growth	/
Ching et al.	2006	1	M	14	<i>Streptococcus milleri</i>	Post-streptococcal glomerulonephritis
Schöndorf et al.	2004	1	F	10 weeks	Negative	/
Stokroos et al.	2003	1	M	56	/	/
Uchida et al.	2002	1	M	25	Polymicrobial	Cholesteatoma
Zapanta et al.	2001	1	F	17	Alfa-hemolytic streptococci	Multiple dural sinus thromboses
Marioni et al.	2001	1	M	18 months	/	/
Spiegel et al.	1998	3	M	55	<i>S. pneumoniae</i>	Intravenous drug user
			M	33	Polymicrobial	HIV
			F	27	Negative	Intravenous drug user
Osma et al.	2000	4	/	/	/	/
Goldstein et al.	1998	1	/	/	/	Parapharyngeal space abscess
Lubianca Neto et al.	1997	1	M	7	/	Cholesteatoma and lateral sinus thrombosis
Pearson et al.	1994	1	M	37	<i>S. milleri</i>	Lateral sinus thrombosis and jugular vein thrombosis
Gaffney et al.	1991	1	M	42	Sterile	Cholesteatoma
Smouha et al.	1989	5	F	23	Polymicrobial	Parapharyngeal space abscess
			M	79	Polymicrobial	Cholesteatoma

(Continued)

Table 1. Continued

Author	Year	Number of cases	Sex	Age	Culture	Remarks
			M	62	<i>P. aeruginosa</i>	/
			M	52	Polymicrobial	
			F	73	Polymicrobial	
El-Kholy et al.	1989	1	M	74	<i>Proteus</i> spp.	Cholesteatoma
Moisa et al.	1987	1	M	60	Polymicrobial	Cholesteatoma
Moloy et al.	1982	1	M	15	Polymicrobial	/
Edison	1980	1	M	43	<i>K. pneumoniae</i>	/
Hill	1968	1	F	2	/	/
Tembe	1965	1	M	23	/	/
O'Malley	1924	1	M	25	/	/
Ouston	1898	1	F	15	/	/

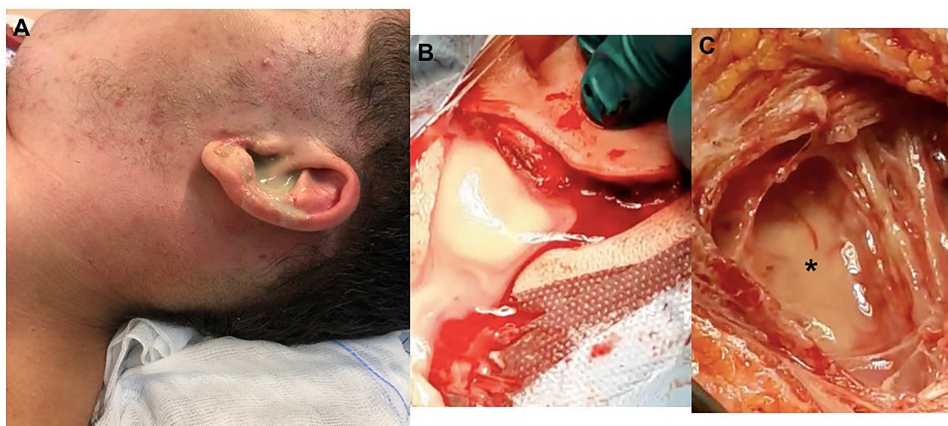


Figure 1: Pre- and intra-operative images; (A) purulent secretion from the external left canal associated with swelling of retro-auricular area (mastoid) and neck; the skin is red as a sign of inflammation; (B) after retro-auricular incision and press on the neck, the purulent secretion comes out; (C) a curettage of the neck area is necessary to remove the residual secretion (black asterisk) which has not been expelled through the retro-auricular incision.

condition. Blind antibiotic treatment is generally discouraged due to the risk of resistance; however, in COVID-19 pandemic, blind combined antibiotic therapy could be necessary.

We describe the management of a BA due to *E. coli* in a patient affected by cholesteatomatous chronic otitis media (CCOM) during the COVID-19 pandemic.

CASE REPORT

A 17-year-old boy with cognitive-emotional impairment presented in August 2020, to our emergency department, complaining about the onset of a left-sided otalgia with purulent otorrhea, neck stiffness and pain on the ipsilateral side without fever. He had a history of bilateral CCOM for 8 years with recurrent flare-up, which was periodically treated by systemic antibiotic therapy and ear washing with acetic acid due to patient's refusal of surgery. The patient presented stiffness of the left side of the neck with hot and sweaty skin, associated with hyperemia and swelling in the left latero-cervical region. The inflammation affected the left mastoid region and extended caudally into the left supraclavicular fossa (Fig. 1A).

The otoscopic examination revealed bilateral perforation of the tympanic membrane and the presence of purulent discharge in the left ear (Fig. 1B). Nasal endoscopy identified II grade adenoid hypertrophy with complete obliteration of left choanal

opening and tubal ostium (Fig. 2A and B). A pure tone audiometry, performed only through bone conduction, showed bilaterally normal auditory threshold. Neck ultrasound identified the presence of abundant fluid in the left latero-cervical area, which extended from the retro-auricular region up to the ipsilateral supraclavicular area.

Head and neck contrast-enhanced computed tomography (CT) scan confirmed the presence of the fluid below the left sternocleidomastoid muscle (Fig. 2C–E) with massive opacification of the mastoid cells and the middle ear (Fig. 3A). Inflammatory tissue was identified in the middle ear with erosion of the ossicular bone chain (Fig. 3B). A diagnosis of CCOM with BA was made.

Intravenous therapy with ceftriaxone (2 g every 24 h), metronidazole (500 mg every 8 h), paracetamol (1 g every 8 h) and pantoprazole (40 mg every 24 h) was started because, due to COVID-19 restriction, it was not possible to immediately perform surgery before confirmation of negative COVID-19 swab. Once received the results of the COVID-19 test, we performed mastoidectomy, drainage of neck abscess (Fig. 1C), adenoidectomy and inspection of middle ear.

The purulent secretion was collected from external ear before starting surgery and then from the neck (Fig. 1) after a small incision of the skin and from middle ear during its inspection; all samples were sent to the microbiologist for culture and antibiogram.

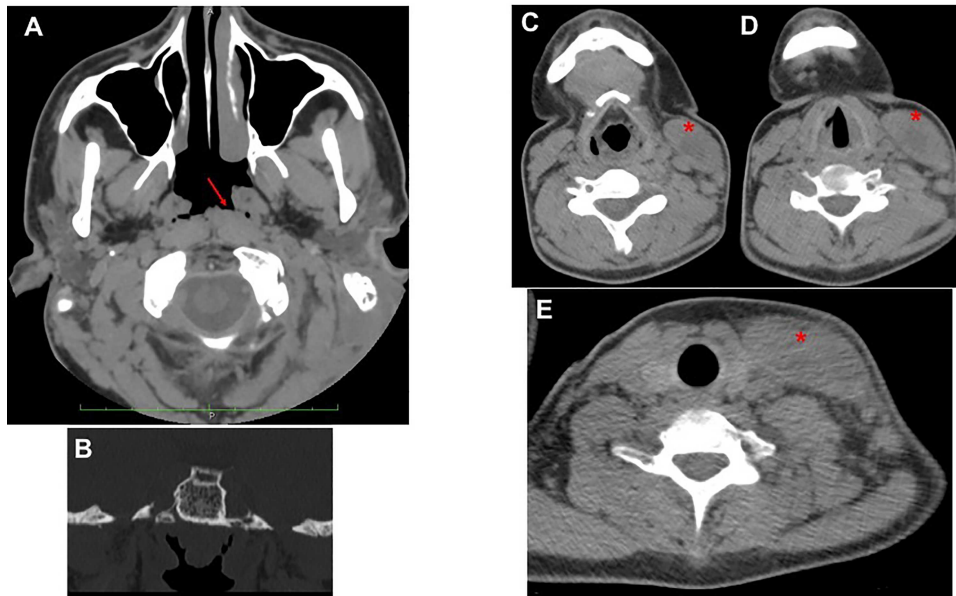


Figure 2: (A) axial view; the red arrow shows edematous torus tubarius; compared to contralateral, the adenoid is hypertrophic but median; the presence of both these conditions contributes to ostium obstruction of the left tuba (B); (C-E) from top to down, the red asterisk shows the imbibition of sternocleidomastoid muscle sign of BA.

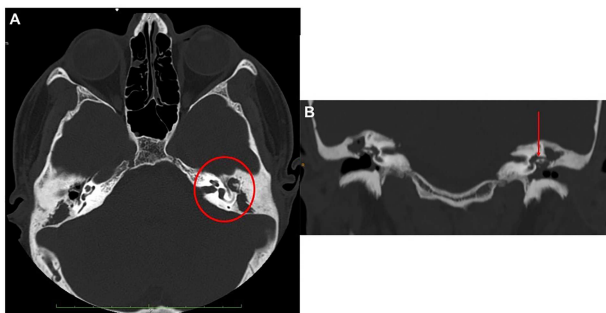

Figure 3: Ear CT scan; (A) axial view; the red circle shows the middle ear filled with inflammatory tissue, with erosion of the ossicular chain; (B) coronal view (the red arrow shows the erosion of malleus and incus); the malleus is not lateralized.

The inspection of the middle ear revealed the erosion of the ossicular chain without lateralization of the malleus, and presence of keratinizing squamous epithelium, confirming the CT findings.

Escherichia coli was present in all three samples of the purulent secretion, and the antibiogram confirmed that the microbe was sensitive to the previously administered antibiotic therapy (ceftriaxone and metronidazole), although the dosage was insufficient to solve the infection. Due to the persistence of the infection after the 2 days of treatment, antibiotic therapy was changed increasing ceftriaxone (2 g/12 h) and metronidazole (500 mg/6 h). The treatment was continued for 7 days until patient discharge 10 days after admission.

In October 2020, the patient underwent left tympanoplasty to remove the inflammatory tissue and cholesteatoma and to perform an ossiculoplasty. The last follow-up (January 2021) showed cleanness of the left external auditory canal, good results of tympanoplasty, normal bilateral auditory thresholds and clean neck area bilaterally.

DISCUSSION

To the best of our knowledge, the case reports presented in the literature [1–4] have never clearly described the presence of *E. Coli* as pathogen responsible of BA.

Today, thanks to the use of antibiotics, BA has become a rare entity. The infection is generally caused by a series of microbes, which in the most of the cases, are easy treatable by a prompt antibiotic therapy. In fact, despite the fact that BA infections are often caused by polymicrobial flora, the *Streptococcus pneumoniae* is the most common microbe identified. Followed by less common pathogens, such as *Pseudomonas aeruginosa*, *Klebsiella pneumoniae* and *Mycobacterium tuberculosis*, and rare entities, such as *Staphylococcus epidermidis* and *Proteus mirabilis* [1–8].

Unlike these pathogens, *E. coli*, which is commonly present in the gut and has immune-stimulating capacity [9], can be very harmful because resistant to antimicrobial treatments.

The delay of the surgery, due to the restrictions during COVID-19 pandemic, and the impossibility of the analysis of purulent secretion could expose the patient to severe risk of brain infection. An early treatment by broad-spectrum antibiotics, despite not being sufficient to solve the infection (dosage too low to eradicate *E. Coli*), was sufficient to avoid the progression of the infection until the surgical curettage of the BA. After surgery, the antibiotic treatment was properly modified to reach complete eradication of the pathogen without patient presented short- and long-term complication.

CONCLUSION

COVID-19 pandemic is having an important impact on the management of many conditions, and the impact on the patients' health can be more relevant than expected. In the present case, the absence of an immediate surgical drainage of BA, associated with the incapacity of performing the analysis of purulent secretion in emergency, could transform a quite low-risk condition

into a life-threatening disease if not promptly and correctly managed.

CONFLICT OF INTEREST STATEMENT

None declared.

FUNDING

This research did not receive any specific grant from funding agencies in the public, commercial or not-for-profit sectors.

REFERENCES

1. Spiegel JH, Lustig LR, Lee KC, Murr AH, Schindler RA. Contemporary presentation and management of a spectrum of mastoid abscesses. *Laryngoscope* 1998;**108**:822–8.
2. Moloy PJ. Anaerobic mastoiditis: a report of two cases with complications. *Laryngoscope* 1982;**92**:1311–5.
3. Mustafa A, Toçi B, Thaçi H, Gjikolli B, Baftiu N. Acute mastoiditis complicated with concomitant Bezold's abscess and lateral sinus thrombosis. *Case Rep Otolaryngolo* 2018;**20**:8702532.
4. Malik K, Dever LL, Kapila R. Bezold's abscess: a rare complication of suppurative mastoiditis. *IDCases* 2019;**17**:e00538.
5. Eswaran S, Kumar S, Kumar P. A rare case of primary tuberculous otitis media with Bezold's abscess. *Indian J Otolaryngol Head Neck Surg* 2019;**71**:1462–6.
6. Nawas MT, Daruwalla VJ, Spierer D, Micco AG, Nemeth AJ. Complicated necrotizing otitis externa. *Am J Otolaryngol* 2013;**34**:706–9.
7. Nasir F, Ashaari ZA. Bezold's abscess: a rare complication of acute otitis media. *Malays Fam Physician* 2017;**12**:26–8, eCollection 2017.
8. Silva VAR, Almeida AS, Lavinsky J, Pauna HF, Castilho AM, Chone CT, et al. Thorax necrotizing fasciitis following Bezold's abscess. *Clin Case Rep* 2020;**8**:2848–51.
9. Córdoba G, Holm A, Hansen F, Hammerum AM, Bjerrum L. Prevalence of antimicrobial resistant *Escherichia coli* from patients with suspected urinary tract infection in primary care. *Denmark. BMC Infect Dis* 2017;**17**:670.