

## Case Report



# Intestinal Spirochetosis: A Case Series and Review of the Literature

Roel Lemmens,<sup>1,2</sup> Thierry Devreker,<sup>1</sup> Bruno Hauser,<sup>1</sup> Elisabeth Degreef,<sup>1</sup> Annieta Goossens,<sup>2</sup> and Yvan Vandenplas<sup>1</sup>

<sup>1</sup>Kidz Health Castle, UZ Brussel, Vrije Universiteit Brussel, Brussels, Belgium

<sup>2</sup>Department of Pathology, UZ Brussel, Vrije Universiteit Brussel, Brussels, Belgium



Received: Feb 8, 2018

Revised: Apr 17, 2018

Accepted: May 16, 2018

### Correspondence to

Yvan Vandenplas

KidZ Health Castle, UZ Brussel, Vrije  
Universiteit Brussel, Laarbeeklaan 101, 1090  
Brussels, Belgium.

E-mail: Yvan.Vandenplas@uzbrussel.be

Copyright © 2019 by The Korean Society of  
Pediatric Gastroenterology, Hepatology and  
Nutrition

This is an open-access article distributed  
under the terms of the Creative Commons  
Attribution Non-Commercial License ([https://  
creativecommons.org/licenses/by-nc/4.0/](https://creativecommons.org/licenses/by-nc/4.0/))  
which permits unrestricted non-commercial  
use, distribution, and reproduction in any  
medium, provided the original work is properly  
cited.

### Conflict of Interest

The authors have no financial conflicts of  
interest.

## ABSTRACT

A clinical suspicion of intestinal spirochetosis is required when patients have long lasting complaints of abdominal pain, diarrhea, rectal bleeding, weight loss, and nausea. An endoscopy with biopsies needs to be performed to confirm the diagnosis of intestinal spirochetosis. The diagnosis of intestinal spirochetosis is based on histological appearance. Intestinal spirochetosis can also be associated with other intestinal infections and juvenile polyps (JPs). JPs seem to be more frequent in patients with intestinal spirochetosis than in patients without intestinal spirochetosis. Intestinal spirochetosis in children should be treated with antibiotics. Metronidazole is the preferred option. In this article, we describe 4 cases of intestinal spirochetosis in a pediatric population and provide a review of the literature over the last 20 years. Intestinal spirochetosis is a rare infection that can cause a variety of severe symptom. It is diagnosed based on histological appearance.

**Keywords:** Spirochete infections; Endoscopy; Co-infection; Polyps; Antibiotics

## INTRODUCTION

Spirochetes were reported in 1719 by van Leeuwenhoek who detected lively moving spiral “animalcules” in his own feces [1]. Spirochetes are classified into 3 phylogenetic groups: Spirochaetaceae (including Borrelia, Spirochaeta, Spirochaeta, and Treponema), Leptospiraceae (Leptonema and Leptospira), and Brachyspiraceae (*Brachyspira aalborgi* and *Brachyspira pilosicoli*). *B. aalborgi* and *B. pilosicoli* are most commonly associated with human intestinal spirochetosis. *B. aalborgi* was first recognized in Denmark in 1982 [2]. During the 90s, stools of patients examined by multilocus enzyme electrophoresis showed a predominance of *B. pilosicoli* [3,4].

Intestinal spirochetosis is a rare infection in children. The term intestinal spirochetosis was used for the first time by Harland and Lee in 1967 [5]. They described a “forest of organisms” on the surface of the epithelium of an adult patient with chronic diarrhea lasting for more than 3 years based on electron microscopy. Adhesion of spirochetes to the brush border mucosa results in thickening of the brush border. Histological appearance is the hallmark of this infection [6].

We performed a search between 2004 and 2014 in the database of our pediatric gastroenterology unit for all cases of intestinal spirochetosis. We also performed a review of the literature through PubMed search using terms of “Human intestinal spirochetosis” and “Children” (filter English). This search resulted in 39 publications. We limited our search to the last 20 years.

## CASE REPORT

### Case 1

A 4-year-old boy was referred because of a history of bloody stools for 8 months. Before referral, a stool culture had shown *Campylobacter jejuni* which was adequately treated with antibiotics (**Table 1**). Control culture was negative. There was no history of diarrhea or hard stools. However, the boy continued to complain of abdominal pain and the bloody stools persisted. Laboratory investigations showed no biological markers for anemia, a slightly elevated sedimentation rate (27 mm/h), normal C-reactive protein (CRP, 1 mg/L), and normal coagulation. Serology for celiac disease was negative. Colonoscopy revealed rectal irritation. Histology of rectal biopsies showed a few lymphocytes and signs of intestinal spirochetosis confirmed by Warthin-Starry staining (WSS). A 10-day course of amoxicillin-clavulanic acid (50 mg/kg/day) was administered. The blood in the stool disappeared as well as abdominal complaints.

However, 2 months later, he presented at the emergency ward with complaints of bloody diarrhea for 2 days without abdominal pain. A new diagnostic work-up with colonoscopy revealed the presence of a juvenile polyp (JP) at 3 cm from the anal margin and a second one at 20 cm. There were no longer signs of intestinal spirochetosis on biopsies. These polyps were removed. They showed an histology compatible with juvenile polyposis. His symptoms disappeared after removal of polyps. The patient remained asymptomatic during 3 months of follow-up.

### Case 2

An 8-year-old boy was presented because of a history of hyperphagia, abdominal pain, chronic diarrhea, and perianal irritation. His complaints started after a recent vacation in Egypt (**Table 1**). A blood sample showed no signs of anemia or inflammation. A colonoscopy seemed normal. However, biopsies revealed an intestinal spirochetosis.

A treatment with metronidazole was started for 2 weeks. The abdominal pain and hyperphagia disappeared almost immediately. However, diarrhea and perianal irritation resolved gradually in the following weeks. Fifteen months after the initial presentation, the patient had again complaints of hyperphagia, diarrhea, and perianal irritation for 3 weeks. A treatment with metronidazole was administered without performing an endoscopy. After this treatment, he had no longer complaints for 1 year. Afterward, he relapsed, suffering from

**Table 1.** Characteristics of patients with intestinal spirochetosis (case reported in this manuscript)

Case	Author	Year	Country	Age	Sex	AP	D	N/V	B	Duration Sx
1	Lemmens	2017	Belgium	4	M	1	0	0	1	8 (mo)
2	-	2017	Belgium	8	M	1	1	0	0	Unknown
3	-	2017	Belgium	7	M	1	1	0	0	18 (mo)
4	-	2017	Belgium	12	M	1	1	0	0	1 (y)

AP: abdominal pain, D: diarrhea, N/V: nausea/vomiting, B: rectal bleeding, Sx: symptoms.

chronic diarrhea and hyperphagia again without abdominal pain. Therefore, he was treated with metronidazole. This time, metronidazole was administered for 4 weeks. After 4 weeks of treatment with metronidazole, an endoscopy was performed. It showed no signs of intestinal spirochetosis.

### Case 3

A 7-year-old boy had non-bloody diarrhea, encopresis, abdominal pain, and peri-anal rash for 18 months. A stool culture was negative. An ultrasound of the abdomen showed no abnormalities (**Table 1**). Blood results revealed no signs of anemia or inflammation with normal tissue transglutaminase. A lower GI-tract endoscopy revealed mild rectal irritation. Histology of biopsies from the rectum and sigmoid showed signs of intestinal spirochetosis. A treatment with metronidazole at 30 mg/kg/day for 10 days was administered. At a follow-up visit 2 months later, the boy no longer suffered from diarrhea or abdominal pain. However, he still had some complaints of encopresis and anal rash. Control endoscopy showed disappearance of intestinal spirochetosis.

### Case 4

A 12-year old boy complained of episodes of abdominal pain, non-bloody diarrhea, and loss of appetite for the last year (**Table 1**). During initial presentation, a stool culture was negative. Blood sample showed some signs of mild inflammation (CRP, 16.6 mg/L; erythrocyte sedimentation rate, 16 mm/h) and discrete anemia (hemoglobin, 12.1 g/dL; normal range, 13–16.5 g/dL). Although the macroscopic aspect of colonic mucosa was normal, histology showed discrete signs of colitis. No spirochetes were found. His symptoms improved without treatment.

After 7 months, he was reevaluated because of relapsed symptoms. Blood results showed again a moderate elevation of inflammation parameters. Stool culture was positive for *Salmonella*. Ultrasound and abdominal computed tomography scan showed mesenteric adenitis and colitis. A new endoscopy was performed and the macroscopic aspect of the colon mucosa was normal. However, histology showed colon mucosae with proximal and distal zones of mild inflammation and cryptitis. WSS was positive in the caecum and colon transversum. A treatment with amoxicillin and metronidazole was commenced for 10 days. His symptoms disappeared after this treatment.

## DISCUSSION

The prevalence of intestinal spirochetosis is correlated with living in a developing region. Prevalence rates of over 30% are seen in Australian aboriginal children. In Australian non-aboriginal children, the prevalence rate is only 1.2% [7]. Several studies have reported prevalence rates ranging from 1.1 to 5% in developed countries [8]. A recent retrospective review from Japan found an even lower prevalence of 0.2% in patients aged less than 20 years [9]. All 4 children described in this article were born and raised in Belgium. None of these children had immigrated to Belgium. Nevertheless, the patient in case 2 developed complaints after a recent stay in Egypt. There seems to be no sex or age prediction except for age under 2 years [7]. This was supported by the finding in our review of the literature that 12 of 27 patients were girls and 15 of 27 patients were boys (**Table 2**, overview of pediatric cases reported in literature). However, in to our series, all patients were boys. The reason for this remains unclear. It is probably a coincidence.

## Intestinal Spirochetosis: A Case Series and Review of the Literature

**Table 2.** Characteristics of patients with intestinal spirochetosis from literature

Case	Author	Year	Country	Age	Sex	AP	D	N/V	B	Duration Sx
5	Ichimata et al. [9]	2017	Japan	9	F	1	0	0	0	>1 (wk)
6	Ghosh et al. [27]	2014	India	10	M	1	1	0	1	3 (mo)
7	Helbling et al. [13]	2012	Switzer land	13	M	0	1	0	1	1 (mo)
8	Carpentieri et al. [19]	2010	USA	11	F	1	0	0	1	Unknown
9	-	2010	USA	6	M	1	1	1	1	2 (mo)
10	-	2010	USA	11	F	1	0	0	0	1 (day)
11	-	2010	USA	17	F	1	0	0	0	Unknown
12	-	2010	USA	10	M	1	0	1	0	1 (wk)
13	Calderaro et al. [23]	2007	Italy	4	F	1	0	0	1	Unknown
14	King et al. [26]	2005	USA	9	M	0	1	0	1	3-4 (mo)
15	Nodit et al. [28]	2004	USA	9	M	1	1	0	1	Unknown
16	Marthinsen et al. [16]	2001	Sweden	5	F	1	1	0	1	Several years
17	-	2001	Sweden	7	M	1	1	0	0	>1 (y)
18	-	2001	Sweden	4	F	0	1	0	1	2 (mo)
19	-	2001	Sweden	10	F	0	1	0	1	2 (mo)
20	-	2001	Sweden	13	M	1	0	1	1	1 (y)
21	-	2001	Sweden	8	M	1	0	0	0	>1 (y)
22	-	2001	Sweden	15	F	1	0	0	1	Several weeks
23	-	2001	Sweden	14	F	1	0	0	0	>1 (y)
24	Heine et al. [29]	2001	Australia	12	M	0	1	1	0	3 (mo)
25	-	2001	Australia	12	M	1	0	0	0	Unknown
26	-	2001	Australia	16	F	1	0	0	0	Unknown
27	-	2001	Australia	9	F	0	1	0	1	1 (y)

AP: abdominal pain, D: diarrhea, N/V: nausea/vomiting, B: rectal bleeding, Sx: symptoms.

Prevalence rates of intestinal spirochetosis in adult patients of developed countries are the highest among HIV patients or homosexual males [6,10,11]. Spirochetes are probably transmitted by fecal-oral route. Sexual transmission has also been suggested because of its higher incidence in homosexual males [12]. In children and adult patients, intestinal spirochetosis can be asymptomatic. It can be an incidental discovery during an endoscopy [13-15].

In pediatric patients, an endoscopy is only performed in the setting of important abdominal complaints. Therefore, intestinal spirochetosis is rarely an incidental discovery. Symptomatic intestinal spirochetosis is associated with abdominal pain, diarrhea, rectal bleeding, weight loss, constipation, and nausea. Based on our review, 81.4% (22/27) of children had complaints of abdominal pain, 51.8% (14/27) suffered from diarrhea, 48.1% (13/27) patients with intestinal spirochetosis suffered from rectal bleeding (**Table 1**), and 14.8% (4/27) had nausea and vomiting. In 85% (17/20) of cases from the literature, the duration of symptoms prior to diagnosis was at least 1 month.

Particularly, children can develop severe symptoms [16-19]. Due to a variety of symptoms, differential diagnosis should include inflammatory bowel disease, infectious, and ischemic or even pseudomembranous colitis [13,20].

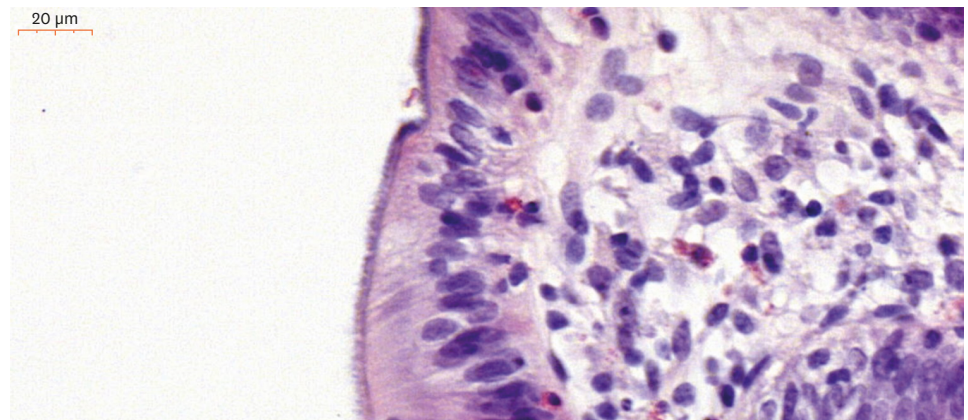
Intestinal spirochetosis is reported to be associated with polyps [8]. However, the overall prevalence of polyps in patients with intestinal spirochetosis is not different from that in the general population [21]. A potential association between intestinal spirochetosis and sessile serrated adenomas or polyps was reported and rejected in adults [8,22]. In a Swedish study, 2 out of 8 pediatric patients with intestinal spirochetosis also had JPs [16]. Calderaro et al. [23] have reported a pediatric case of intestinal spirochetosis and JP. In our case series, 1 out of 4 patients had a JP. According to literature review, 5/27 (19%) patients had JP. This is much higher than the prevalence of JP in the general population (1/100). Intestinal spirochetosis

might be a risk factor for JP in children. Intestinal spirochetosis is often diagnosed after several months of abdominal complaints. Could this chronic infection/inflammation be a trigger for developing JP?

A study in adults suggested that intestinal spirochetosis was associated with non-constipation irritable bowel syndrome [8]. Co-infection with other micro-organisms was also reported. *Helicobacter pylori*, *Enterobius vermicularis*, *Shigella Flexneri*, *Neisseria gonorrhoea*, *Entamoeba histolytica*, *Blastocystis hominis*, *Giardia intestinalis*, *Hymenolepis nana*, and *Ascaris* are all reported to be associated with spirochetosis [1,21]. In our patients, we found a co-infection with *Salmonella* and *C. jejuni*. Hygiene and/or co-infection with other pathogens could be a risk factor. However, this hypothesis needs further research.

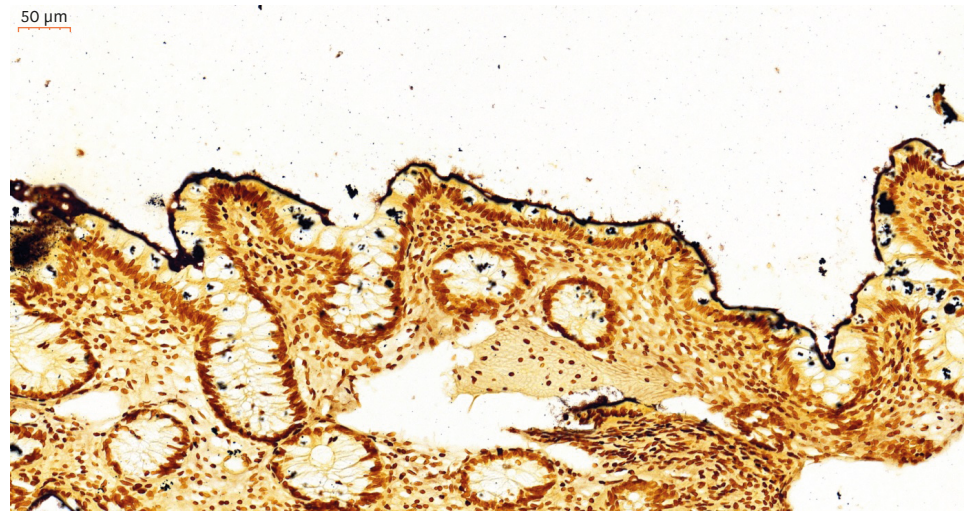
Endoscopy is reported to be often macroscopically normal. Erythematous or unspecific lesions are also observed. In half of our patients, irritation of the rectal mucosa was reported. The diagnosis of intestinal spirochetosis is based on histological appearance of a diffuse blue fringe seen on hematoxylin-eosin staining that is approximately 3–6  $\mu\text{m}$  thick along the border of the intercryptal epithelial layer (Fig. 1). This finding is referred to as “false brush border”. It is more clearly seen in a silver WSS (Fig. 2). The surrounding cytostructure can show signs of inflammation (e.g., edema, infiltrate of monocytes, lymphocytes, plasma cells, and neutrophils in the lamina propria and elongated and hyperplastic crypts). On electron microscopy, spirochetes are attached perpendicularly to the epithelial membrane of enterocytes. Microvilli can be shortened or depleted. Defect of the glycocalyx and swelling of the mitochondria can be noticed [2,5,6]. Colonization of several parts of the intestinal is common. The location of the highest colonization rate differs from patient to patient [8]. A recent study has suggested that intestinal spirochetosis is more frequent in the right-side large intestine [24]. Involvement of the appendix has also been reported [25]. Although spirochetes are reported to be most predominant in colon ascendens, symptoms involve the distal colon more.

There is a lack of evidence on which is the therapy of choice in children with intestinal spirochetosis. Several treatment strategies have been proposed in the past 2 decades, including macrolide antibiotic, macrolide combined with metronidazole, metronidazole alone, and clindamycin. However, metronidazole seems to become the antibiotic of choice [13]. In the literature, 7 out of 27 patients at diagnosis were treated with metronidazole in monotherapy and 5 of 27 patients were treated with metronidazole combined with



**Fig. 1.** Diffuse blue fringe seen on hematoxylin-eosin staining. It is approximately 3 to 6  $\mu\text{m}$  thick along the border of the intercryptal epithelial layer, suggesting the diagnosis of spirochetosis.





**Fig. 2.** The diffuse fringe is referred to as “false brush border”. It can be more clearly seen in a silver Warthin-Starry staining.

amoxicillin. Nevertheless, relapses are frequently reported in the literature. In the review, we found that more than half of patients (14/27) had no complete recovery or relapsed after a first antibiotic treatment when patient was treated with metronidazole.

Spontaneous resolution of symptoms has also been reported [16,26]. One of our patients was treated with amoxicillin clavulanic acid. Two patients received treatment with metronidazole alone. The last one was treated with metronidazole and amoxicillin because of co-infection with *Salmonella*.

In conclusion, intestinal spirochetosis is a quite rare infection in children. This might be related to the fact that its diagnosis can only be made on intestinal biopsies. Intestinal spirochetosis can cause diverse symptoms such as abdominal pain, diarrhea, rectal bleeding, weight loss, and nausea. As a consequence, endoscopy and histology are recommended in the work-up of a child chronically presenting a combination of these symptoms.

## REFERENCES

1. van Mook WN, Koek GH, van der Ven AJ, Ceelen TL, Bos RP. Human intestinal spirochaetosis: any clinical significance? *Eur J Gastroenterol Hepatol* 2004;16:83-7.  
[PUBMED](#) | [CROSSREF](#)
2. Hovind-Hougen K, Birch-Andersen A, Henrik-Nielsen R, Orholm M, Pedersen JO, Teglbjaerg PS, et al. Intestinal spirochetosis: morphological characterization and cultivation of the spirochete *Brachyspira aalborgi* gen. nov., sp. nov. *J Clin Microbiol* 1982;16:1127-36.  
[PUBMED](#)
3. Lee JI, Hampson DJ. Genetic characterisation of intestinal spirochaetes and their association with disease. *J Med Microbiol* 1994;40:365-71.  
[PUBMED](#) | [CROSSREF](#)
4. Trott DJ, Stanton TB, Jensen NS, Hampson DJ. Phenotypic characteristics of *Serpulina pilosicoli* the agent of intestinal spirochaetosis. *FEMS Microbiol Lett* 1996;142:209-14.  
[PUBMED](#) | [CROSSREF](#)
5. Harland WA, Lee FD. Intestinal spirochaetosis. *BMJ* 1967;3:718-9.  
[PUBMED](#) | [CROSSREF](#)

6. Körner M, Gebbers JO. Clinical significance of human intestinal spirochetosis--a morphologic approach. *Infection* 2003;31:341-9.  
[PUBMED](#)
7. Lee JI, Hampson DJ. Intestinal spirochaetes colonizing aborigines from communities in the remote north of Western Australia. *Epidemiol Infect* 1992;109:133-41.  
[PUBMED](#)
8. Walker MM, Talley NJ, Inganäs L, Engstrand L, Jones MP, Nyhlin H, et al. Colonic spirochetosis is associated with colonic eosinophilia and irritable bowel syndrome in a general population in Sweden. *Hum Pathol* 2015;46:277-83.  
[PUBMED](#) | [CROSSREF](#)
9. Ichimata S, Yoshizawa A, Kusakari M, Nakayama Y, Asaka S, Negishi T, et al. Human intestinal spirochetosis in Japanese patients aged less than 20 years: Histological analysis of colorectal biopsy and surgical specimens obtained from 479 patients. *Pathol Int* 2017;67:302-5.  
[PUBMED](#) | [CROSSREF](#)
10. Lindboe CF. The prevalence of human intestinal spirochetosis in Norway. *Anim Health Res Rev* 2001;2:117-9.  
[PUBMED](#)
11. Tompkins DS, Foulkes SJ, Godwin PG, West AP. Isolation and characterisation of intestinal spirochaetes. *J Clin Pathol* 1986;39:535-41.  
[PUBMED](#) | [CROSSREF](#)
12. McMillan A, Lee FD. Sigmoidoscopic and microscopic appearance of the rectal mucosa in homosexual men. *Gut* 1981;22:1035-41.  
[PUBMED](#) | [CROSSREF](#)
13. Helbling R, Osterheld MC, Vaudaux B, Jatou K, Nydegger A. Intestinal spirochetosis mimicking inflammatory bowel disease in children. *BMC Pediatr* 2012;12:163.  
[PUBMED](#) | [CROSSREF](#)
14. Carr NJ, Mahajan H, Tan KL, Sharma R. The histological features of intestinal spirochetosis in a series of 113 patients. *Int J Surg Pathol* 2010;18:144-8.  
[PUBMED](#) | [CROSSREF](#)
15. Ngwa T, Peng JL, Choi E, Tayarachakul S, Liangpunsakul S. Colonic spirochetosis in a 60-year-old immunocompetent patient: case report and review. *J Investig Med High Impact Case Rep* 2016;4:2324709616662671.  
[PUBMED](#) | [CROSSREF](#)
16. Marthinsen L, Willén R, Carlén B, Lindberg E, Värendh G. Intestinal spirochetosis in eight pediatric patients from Southern Sweden. *APMIS* 2002;110:571-9.  
[PUBMED](#)
17. Tsinganou E, Gebbers JO. Human intestinal spirochetosis--a review. *Ger Med Sci* 2010;8:Doc01.  
[PUBMED](#) | [CROSSREF](#)
18. Koteish A, Kannangai R, Abraham SC, Torbenson M. Colonic spirochetosis in children and adults. *Am J Clin Pathol* 2003;120:828-32.  
[PUBMED](#) | [CROSSREF](#)
19. Carpentieri DF, Souza-Morones S, Gardetto JS, Ross HM, Downey K, Ingebo K, et al. Intestinal spirochetosis in children: five new cases and a 20-year review of the literature. *Pediatr Dev Pathol* 2010;13:471-5.  
[PUBMED](#) | [CROSSREF](#)
20. Peruzzi S, Gorrini C, Piccolo G, Calderaro A, Dettori G, Chezzi C. Human intestinal spirochaetosis in Parma: a focus on a selected population during 2002–2005. *Acta Biomed* 2007;78:128-32.  
[PUBMED](#)
21. Calderaro A, Gorrini C, Peruzzi S, Piccolo G, Dettori G, Chezzi C. Occurrence of human intestinal spirochetosis in comparison with infections by other enteropathogenic agents in an area of the Northern Italy. *Diagn Microbiol Infect Dis* 2007;59:157-63.  
[PUBMED](#) | [CROSSREF](#)
22. Omori S, Mabe K, Hatanaka K, Ono M, Matsumoto M, Takahashi M, et al. Human intestinal spirochetosis is significantly associated with sessile serrated adenomas/polyps. *Pathol Res Pract* 2014;210:440-3.  
[PUBMED](#) | [CROSSREF](#)
23. Calderaro A, Bommezzadri S, Gorrini C, Piccolo G, Peruzzi S, Villanacci V, et al. Infective colitis associated with human intestinal spirochetosis. *J Gastroenterol Hepatol* 2007;22:1772-9.  
[PUBMED](#) | [CROSSREF](#)
24. Ogata S, Shimizu K, Nakanishi K. Human intestinal spirochetosis: right-side preference in the large intestine. *Ann Diagn Pathol* 2015;19:414-7.  
[PUBMED](#) | [CROSSREF](#)

25. Henrik-Nielsen R, Lundbeck FA, Teglbjaerg PS, Ginnerup P, Hovind-Hougen K. Intestinal spirochetosis of the vermiform appendix. *Gastroenterology* 1985;88:971-7.  
[PUBMED](#) | [CROSSREF](#)
26. King NR, Fidda N, Gourley G. Colorectal spirochetosis in a child with rectal bleeding: case report and literature review. *J Pediatr Gastroenterol Nutr* 2005;41:673-5.  
[PUBMED](#) | [CROSSREF](#)
27. Ghosh JK, Goyal SK, Lamtha SC, Kaushik P, Behera MK, Abhilash VB, et al. Colonic spirochetosis in an immunocompetent child. *Trop Gastroenterol* 2014;35:266-9.  
[PUBMED](#)
28. Nodit L, Parizhskaya M. Intestinal spirochetosis. *Arch Pathol Lab Med* 2004;128:823-4.  
[PUBMED](#)
29. Heine RG, Ward PB, Mikosza AS, Bennett-Wood V, Robins-Browne RM, Hampson DJ. *Brachyspira aalborgi* infection in four Australian children. *J Gastroenterol Hepatol* 2001;16:872-5.  
[PUBMED](#) | [CROSSREF](#)