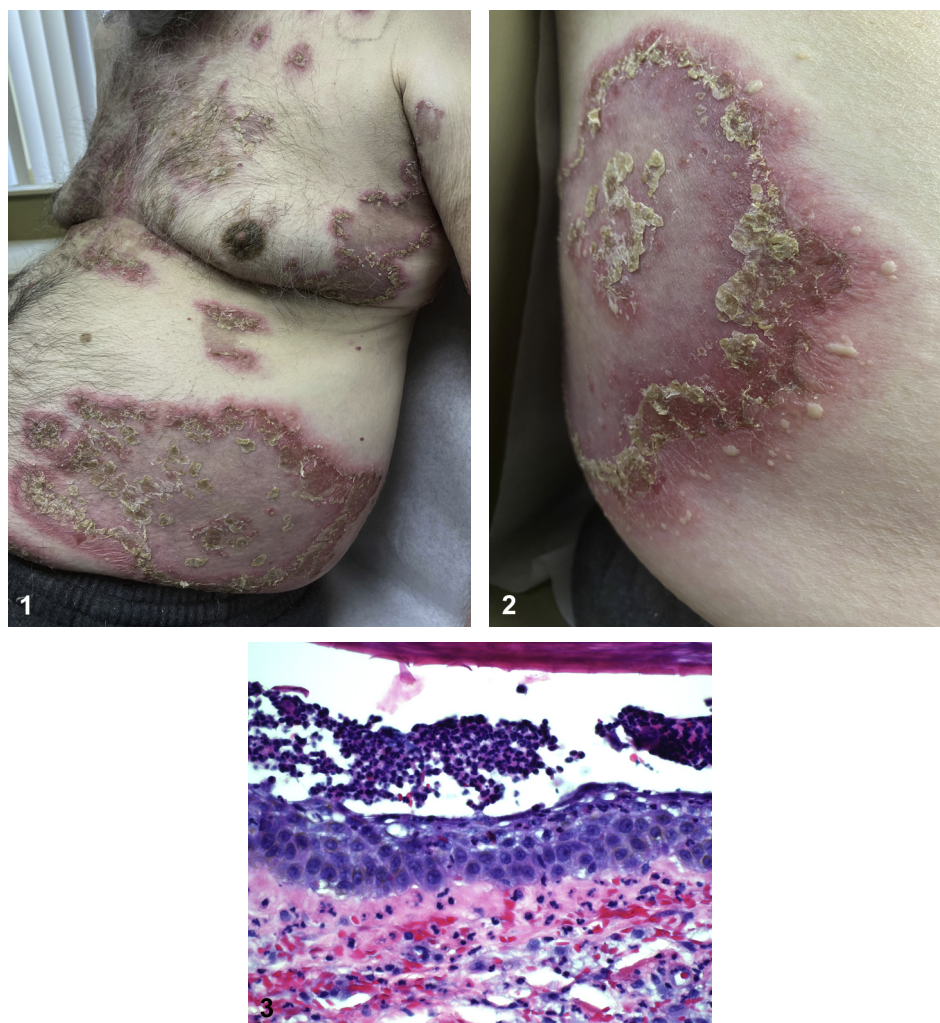


Annular scaly plaques with peripheral pustules



Lisa Faye Fronek, DO,^{a,b} Allyson Brooke Brahs, DO,^c Taylor Gray, DO,^{a,b} Julie Gibbs, MD,^d and James Sligh, MD, PhD^b
St. Petersburg and Bay Pines, Florida

Key words: checkpoint inhibitor; drug eruption; PD-1 inhibitor; pembrolizumab; programmed death protein-1 inhibitor; Sneddon-Wilkinson disease; subcorneal pustular dermatosis.



From the Dermatology Department, HCA Healthcare/USF Morsani College of Medicine GME: Largo Medical Center Program, St. Petersburg^a; Department of Dermatology, Bay Pines Veterans Affairs Healthcare System^b; Department of Medicine, Hospital Corporation of America Healthcare/University of South Florida College of Medicine Graduate Medical Education: Largo Medical Center Program, St. Petersburg^c; and Department of Pathology and Laboratory Medicine Services, Bay Pines Veterans Affairs Healthcare System.^d

Funding sources: Supported (in whole or part) by HCA Healthcare and/or an HCA-affiliated entity. The views expressed in this publication represent those of the authors.

IRB approval status: Not applicable.

Correspondence to: Lisa Faye Fronek, DO, Dermatology Department, HCA Healthcare/USF Morsani College of Medicine GME: Largo Medical Center Program, 1560 Central Ave, Apartment 122, St. Petersburg, FL 33705. E-mail: drlisafronek@gmail.com.

JAAD Case Reports 2022;21:185-8.

2352-5126

© 2022 by the American Academy of Dermatology, Inc. Published by Elsevier, Inc. This is an open access article under the CC BY-NC-ND license (<http://creativecommons.org/licenses/by-nc-nd/4.0/>).

<https://doi.org/10.1016/j.jidcr.2021.04.039>

A 79-year-old man with urothelial carcinoma presented with a 1-week history of erythematous, indurated, arcuate plaques studded with pustules (Figs 1 and 2). Nine weeks prior to presentation he received pembrolizumab 200 mg administered as intravenous infusion for a total of three doses; there were no other newly introduced medications to note. The patient also denied any personal or family history of psoriasis. The eruption involved >75% body surface area including the trunk, extremities, and intertriginous regions. Importantly, palms, soles, mucosa, and nail units were spared. The patient denied cutaneous pain, fever, arthralgias, or myalgias. A lesional biopsy submitted for hematoxylin-eosin staining showed a subcorneal pustule with polymorphous infiltrate of neutrophils, lymphocytes, and eosinophils within the papillary dermis (Fig 3), whereas perilesional direct immunofluorescence (DIF) was negative.

Question 1: What is the most likely diagnosis based on history and clinicopathologic features?

- A. Subcorneal pustular dermatosis (SPD)
- B. IgA pemphigus
- C. Acute generalized exanthematous pustulosis (AGEP)
- D. Acute generalized pustular psoriasis of von Zumbusch
- E. Subacute cutaneous lupus erythematosus (SCLE)

Answers:

A. Subcorneal pustular dermatosis (SPD) — Correct. SPD, also referred to as Sneddon-Wilkinson disease, is an idiopathic vesiculobullous disorder that classically presents with polycyclic plaques containing superficial sterile pustules.^{1,2} Although SPD is predominantly associated with IgA paraproteinemia, which was lacking in the abovementioned case of the patient, occasional reports have linked it to drug eruptions as well. In a similar case, Zhao et al² described an intracorneal pustular drug eruption that presented 12 weeks after the introduction of nivolumab.³

B. IgA pemphigus — Incorrect. This immunobullous entity presents with pruritic, arcuate plaques in intertriginous locations and may be associated with IgA monoclonal gammopathy. IgA pemphigus is subdivided into subcorneal pustular dermatosis type and intraepidermal neutrophilic type. Although there is significant clinical overlap between SPD and IgA pemphigus, a defining difference is that IgA pemphigus will have a positive DIF.¹

C. Acute generalized exanthematous pustulosis (AGEP) — Incorrect. AGEP is a febrile pustular drug reaction, commonly to β -lactam antibiotics, macrolides, or calcium channel blockers.¹ Although there have been some reports linking checkpoint inhibitors to AGEP under the category of neutrophilic drug eruptions,^{3,4} we believe that our case is

more consistent with SPD on the basis of the key features of the eruption latency to rash presentation. It should be emphasized that AGEP is typified by a more abrupt onset of nonfollicular-based pustules that will first begin on the face and then become more generalized.² In contrast, our patient had follicular-based pustules and no facial involvement. The timeframe for AGEP is another crucial point. AGEP is classified by a sudden eruption usually within 4 to 5 days but may be up to 2 weeks.⁴ In contrast, our patient was receiving treatment with pembrolizumab for 9 weeks before his first cutaneous symptoms presented. Additionally, AGEP is typically accompanied by systemic symptoms such as fever and peripheral neutrophilia,² all of which were lacking in the case of our patient.

D. Acute generalized pustular psoriasis of von Zumbusch — Incorrect. This severe subtype of psoriasis will feature tender psoriasiform plaques and systemic symptoms such as fever.¹ Leukocytosis and hypocalcemia can be present. Although there may be controversy over the relationship between SPD and pustular psoriasis, the lack of personal or family history of psoriasis is an important fact to consider when distinguishing these entities.

E. Subacute cutaneous lupus erythematosus (SCLE) — Incorrect. SCLE can present as annular plaques with central clearing or papulosquamous plaques on sun-exposed areas. Although SCLE may occur in genetically predisposed individuals, it can be associated with certain medications; causative agents include hydrochlorothiazide, nonsteroidal antiinflammatory drugs, angiotensin-converting enzyme inhibitors, terbinafine, proton pump inhibitors, etc.

Question 2: What is the mechanism of action of pembrolizumab?

- A. Inhibits epidermal growth factor receptor
- B. Inhibits dihydrofolic acid through competing with para-aminobenzoic acid for the binding site of dihydropteroate synthetase

- C. Inhibits checkpoint cytotoxic T-lymphocyte-associated protein 4
- D. Inhibits programmed cell death protein
- E. Inhibits the mammalian target of rapamycin

Answers:

- A. Inhibits epidermal growth factor receptor — Incorrect. This includes medications such as erlotinib and cetuximab.
- B. Inhibits dihydrofolic acid through competing with para-aminobenzoic acid for the binding site of dihydropteroate synthetase — Incorrect. This is the mechanism of action of dapsone, a possible treatment for SPD.¹
- C. Inhibits checkpoint cytotoxic T-lymphocyte-associated protein 4 — Incorrect. This is the mechanism of action of ipilimumab, a monoclonal antibody that neutralizes cytotoxic T-lymphocyte-associated protein 4, resulting in a heightened immune response to tumor cells.⁵
- D. Inhibits programmed cell death protein — Correct. Pembrolizumab, along with nivolumab, is a programmed cell death protein 1 inhibitor approved by the US Food and Drug Administration for metastatic melanoma, Merkel cell carcinoma, cutaneous squamous cell carcinoma, and various solid organ cancers.⁵
- E. Inhibits the mammalian target of rapamycin — Incorrect. This class of medications includes sirolimus and everolimus. These have been used for the treatment of certain solid organ cancers and antirejection mechanisms in solid organ transplant recipients.

Question 3: Which histologic description correlates with the diagnosis/the images shown?

- A. Subcorneal vesicle with neutrophils and negative DIF
- B. Subcorneal neutrophilic vesicle with overlying hyperkeratosis and crust, pseudohyphae within the stratum corneum
- C. Subcorneal vesicle with neutrophils, intraepidermal spongiosis, and eosinophils within the papillary dermis
- D. Basement membrane thickening, vacuolar interface change, mucin deposition, and positive DIF demonstrating IgG, immunoglobulin M, and occasionally C3

E. Subcorneal vesicle with neutrophils and DIF demonstrates intercellular deposition of IgG within the upper layer of the epidermis

Answers:

- A. Subcorneal vesicle with neutrophils and negative DIF — Correct. This appropriately describes SPD and highlights an important distinguishing factor between SPD and IgA pemphigus; SPD will have a negative DIF, whereas IgA pemphigus will demonstrate intercellular deposition of IgA within the upper layer of the epidermis.¹
- B. Subcorneal neutrophilic vesicle with overlying hyperkeratosis and crust, pseudohyphae within the stratum corneum — Incorrect. This describes *Candida* infection, one of the differential diagnoses to consider with a subcorneal blister with neutrophils.
- C. Subcorneal vesicle with neutrophils, intraepidermal spongiosis, and eosinophils within the papillary dermis — Incorrect. This describes the histologic findings of AGEp.²⁻⁴
- D. Basement membrane thickening, vacuolar interface change, mucin deposition, and positive DIF demonstrating IgG, immunoglobulin M, and occasionally C3 — Incorrect. This describes the histology and immunofluorescence patterns observed in SCLE.
- E. Subcorneal vesicle with neutrophils and DIF demonstrates intercellular deposition of IgG within the upper layer of the epidermis — Incorrect. This describes what may be observed in pemphigus foliaceus.

Abbreviations used:

AGEp: acute generalized exanthematous pustulosis
DIF: direct immunofluorescence
SCLE: subacute cutaneous lupus erythematosus
SPD: subcorneal pustular dermatosis

Conflicts of interest

None disclosed.

REFERENCES

1. Watts PJ, Khachemoune A. Subcorneal pustular dermatosis: a review of 30 years of progress. *Am J Clin Dermatol*. 2016;17(6):653-671. <https://doi.org/10.1007/s40257-016-0202-8>
2. Zhao CY, Consuegra G, Chou S, Fernández-Peñas P. Intracorneal pustular drug eruption, a novel cutaneous adverse event in anti-programmed cell death-1 patients that highlights the effect of anti-programmed cell death-1 in neutrophils. *Melanoma Res*. 2017;27(6):641-644. <https://doi.org/10.1097/CMR.0000000000000397>

3. Ravi V, Maloney NJ, Worswick S. Neutrophilic dermatoses as adverse effects of checkpoint inhibitors: a review. *Dermatol Ther*. 2019;32(5):e13074. <https://doi.org/10.1111/dth.13074>
4. Hwang SJ, Carlos G, Wakade D, Sharma R, Fernandez-Penas P. Ipilimumab-induced acute generalized exanthematous pustulosis in a patient with metastatic melanoma. *Melanoma Res*. 2016;26(4):417-420. <https://doi.org/10.1097/CMR.0000000000000261>
5. Seidel JA, Otsuka A, Kabashima K. Anti-PD-1 and anti-CTLA-4 therapies in cancer: mechanisms of action, efficacy, and limitations. *Front Oncol*. 2018;8:86. <https://doi.org/10.3389/fonc.2018.00086>