



## Biomarker of urinary 5-HIAA as a valuable predictor of acute appendicitis

Leila Haji Maghsoudi<sup>a</sup>, Ali Soltanian<sup>a</sup>, Alireza Shirzadi<sup>b</sup>, Reza Alizadeh-Kashani<sup>c</sup>,  
Mojtaba Ahmadinejad<sup>a,\*</sup>

<sup>a</sup> Department of General Surgery, Faculty of Medicine, Alborz University of Medical Sciences, Karaj, Iran

<sup>b</sup> Non-Communicable Disease Research Center, Alborz University of Medical Sciences, Karaj, Iran

<sup>c</sup> Department of Anesthesiology, School of Medicine, Alborz University of Medical Sciences, Karaj, Iran

### ARTICLE INFO

#### Keywords:

5-HIAA  
Acute appendicitis  
Appendectomy  
Biomarker  
Serotonin  
Metabolite

### ABSTRACT

**Background:** Serotonin-containing cells are abundantly found in the appendix. Studies have shown that acute appendicitis is likely to be characterized by altered urinary 5-hydroxyindole acetic acid (5-HIAA), an active serotonin metabolite. The aim of this study is to investigate the diagnostic potential of 5-HIAA as a biomarker for acute appendicitis.

**Method:** This cross-sectional study enrolled patients referred at the Madani Hospital, with right iliac fossa pain, suspected to having the acute appendicitis. Before the initiation of the basic treatment and surgery, urine samples were obtained from the patients. Enzyme-linked immunosorbent assay (ELISA) was used for the analysis of 5-HIAA urinary levels. The obtained data were statistically analyzed using SPSS v18.

**Results:** Of 129 patients included in the study with the mean age of 29 years, 62 (48.1%) were men and 67 (51.9%) were women. Appendectomy was performed in 96 patients, where 81 cases were that of acute appendicitis. The mean levels of 5-HIAA in acute appendicitis group and in the negative appendectomy group was not statistically significant. The sensitivity of the test was 54.3% based on 7.4  $\mu\text{mol/L}$  as cut-off %HIAA value.

**Conclusion:** Our study reports that 5-HIAA urine concentration is not a reliable diagnostic marker for the diagnosis of acute appendicitis.

## 1. Introduction

Acute appendicitis is recognized as the most common cause of severe acute abdominal pain around the world [1]. Non-specific, poorly localized and variably intense abdominal pain are significant indications for differential diagnosis of acute appendicitis [2]. In general, the prevalence of perforated appendicitis is 25.8% [3]. In children under 5 years of age and in patients over 65, its incidence is reported as 45% and 51%, respectively [4]. Furthermore, it can also be walled off [5] and generalized peritonitis can occur if the body fails to encounter the infection [6 and 7]. In cases of appendix perforation, several potentially life-threatening complications such as sepsis, bacterial peritonitis [8,9], small intestinal obstruction and abdominal abscess formation may occur [10,11]. Advanced bacterial peritonitis can be caused by untreated perforated appendicitis and has a mortality rate of 80–100% [12,13]. Therefore, advanced studies are needed to find reliable diagnostic methods for the early diagnosis of acute appendicitis [14]. A system based on clinical observations

\* Corresponding author. Alborz University of Medical Sciences, Karaj, Iran.

E-mail address: [md.m.ahmadinejad@gmail.com](mailto:md.m.ahmadinejad@gmail.com) (M. Ahmadinejad).

<https://doi.org/10.1016/j.plabm.2020.e00198>

Received 29 April 2020; Accepted 11 December 2020

2352-5517/© 2020 The Author(s). Published by Elsevier B.V. This is an open access article under the CC BY-NC-ND license (<http://creativecommons.org/licenses/by-nc-nd/4.0/>).

**Table 1**  
Urinary 5-HIAA level in acute appendicitis and negative appendectomy.

HIAA_group (cut-off 7.4 $\mu\text{mol/L}$ )		Result based on Pathologic report		Total
		Appendicitis	No Appendicitis	
HIAA_group (cut-off 7.4 $\mu\text{mol/L}$ )	Positive	44 (54.3%)	35 (72.9%)	79 (61.2%)
	Negative	37 (45.7%)	13 (27.1%)	50 (38.8%)
Total		81 (100.0%)	48 (100.0%)	129 (100.0%)

and biochemical analysis is used for the diagnosis of appendicitis [15]. Nonetheless, non-classical signs and symptoms are commonly reported as well. Imaging modalities are either associated with unnecessary radiation exposure or low specificity and sensitivity [16,17].

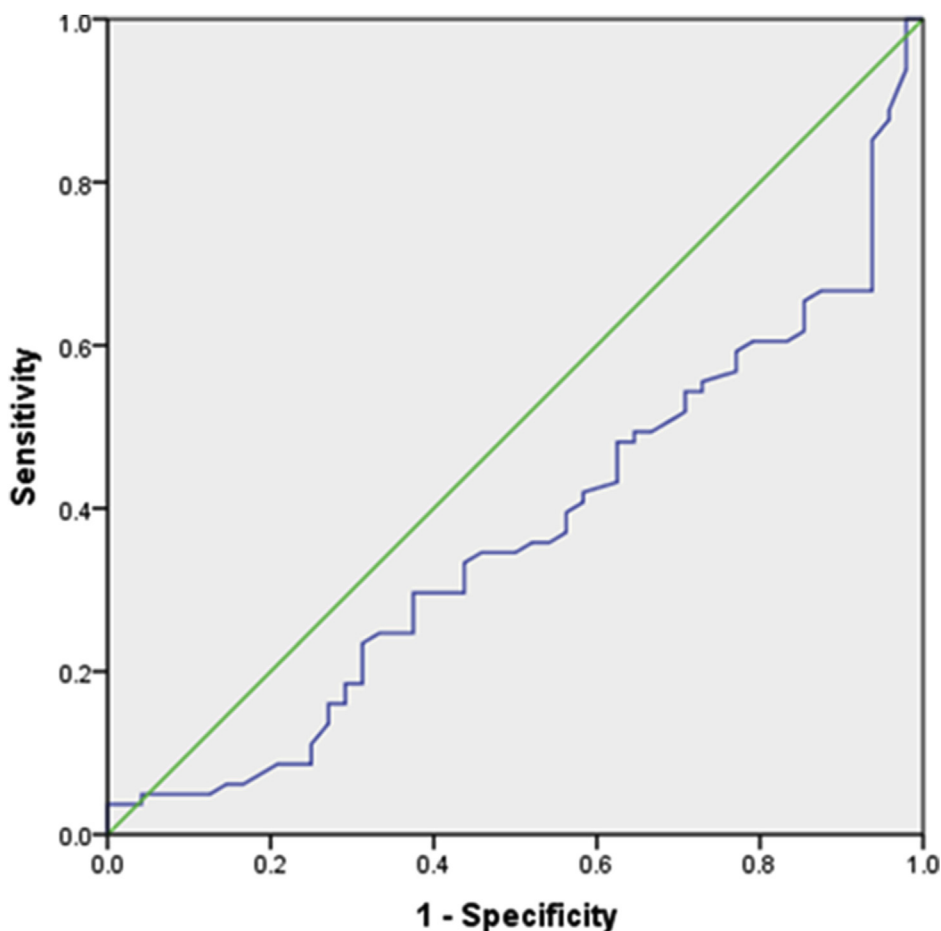
Serotonin-containing enterochromaffin cells are densely located in appendix. 5-Hydroxyindole acetic acid (5-HIAA) is the chief metabolite of serotonin and its increased urinary levels are known to be associated with appendicitis [16,18,19]. Animal models of appendicitis have also revealed significant elevation in urinary 5-HIAA levels, as compared to the controls [13].

Considering the importance of acute appendicitis and its high prevalence in the population, the aim of this study is to evaluate the urinary levels of 5-hydroxy-indoleacetic acid and determine its significance as a diagnostic marker.

## 2. Methods

This was a cross-sectional study conducted at the emergency department of Shahid Madani Hospital in Karaj, Tehran. All the patients with the complaint of right iliac fossa pain, suspected of acute appendicitis were included in the study. Patients under the medications that influence serotonin levels (serotonin and norepinephrine reuptake inhibitors, antidepressants, monoamine oxidase inhibitors and lithium) were excluded from the study.

After obtaining written consent to participate in the study, the patients received initial treatment, prior to which urine samples were



**Fig. 1.** Surface area under the ROC curve in 129 patients.

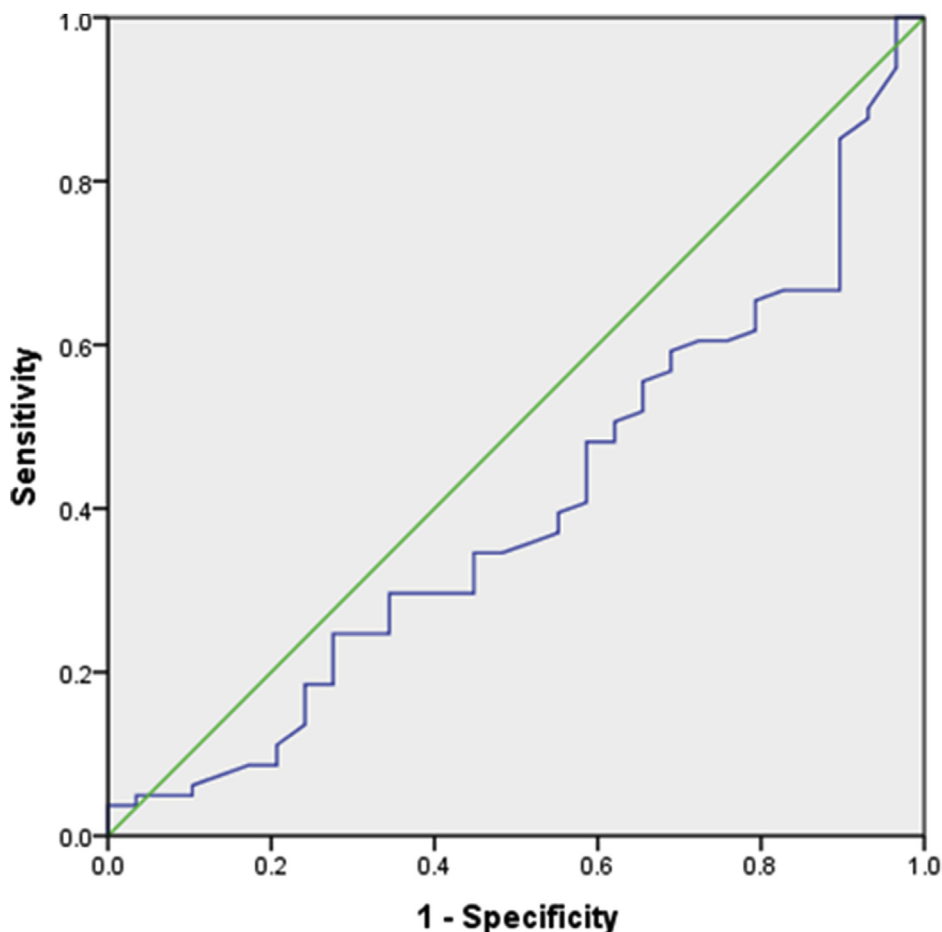


Fig. 2. Area below the ROC curve in 110 patients.

obtained at the time of admission, preoperatively. Acidification of urine samples was achieved and ELISA (enzyme-linked immunosorbent assay) was performed for 5-HIAA [16]. The diagnosis of acute appendicitis was based on the intraoperative findings and associated histopathological outcomes. Medical information of the patients was retrieved from the hospital records that included age, gender, medical history, drug history, symptoms, complains and surgical outcomes. The data were analyzed using SPSS v18. The sensitivity, specificity and value of positive and negative predictive values were evaluated for 5-HIAA test. Chi-square, *t*-test and ANOVA and its nonparametric equivalents were used for comparative analysis. *P*-value <0.05 was considered to be statistically significant. This study was approved by the Research Ethics Board of Alborz University of Medical Sciences (IR.ABZUMS.REC.1397.222).

### 3. Results

Of 129 patients included in the study, 62 (48.1%) were men and 67 (51.9%) were women. The mean age of patients was 29 years (6–85 years). 110 patients underwent surgery, where, appendectomy was performed in 96 patients. Other surgical procedures included 1 liver surgery, 2 ovarian surgery, 5 cholecystectomies, 3 Herniot Ruffy, 2 colonic surgery and 1 case of varicocele.

Of the 96 patients who underwent appendectomy, based on the pathological findings, 81 cases were reported to be that of acute appendicitis and 15 cases were of negative appendectomy. The rate of negative appendectomy was 15.6% in this study.

At the time of admission, the mean levels of urinary 5-HIAA in the acute appendicitis group were 7.27  $\mu\text{mol/L}$  and in the negative appendectomy group was 9.27  $\mu\text{mol/L}$ , which was not statistically significant (Table 1). Based on the calculation and considering the cut-off point of urinary 5-HIAA as 7.4  $\mu\text{mol/L}$  according to the test procedure, the sensitivity, positive predictive value and negative predictive value were 54.3% (CI 73.64%: 96.43%), 27.1% (99/40-CI: 16/56% 96 of 55.7% (CI: 14.44%, 74.44%) and 26% (CI-55.33%: 15/87% 95), respectively. The ROC curve of 129 patients who were included in the study, among which 110 patients who underwent the surgery and 96 patients who underwent appendectomy, was calculated which showed that the ability to predict appendicitis by the means of urinary 5-HIAA might not be acceptable (Figs. 1–3).

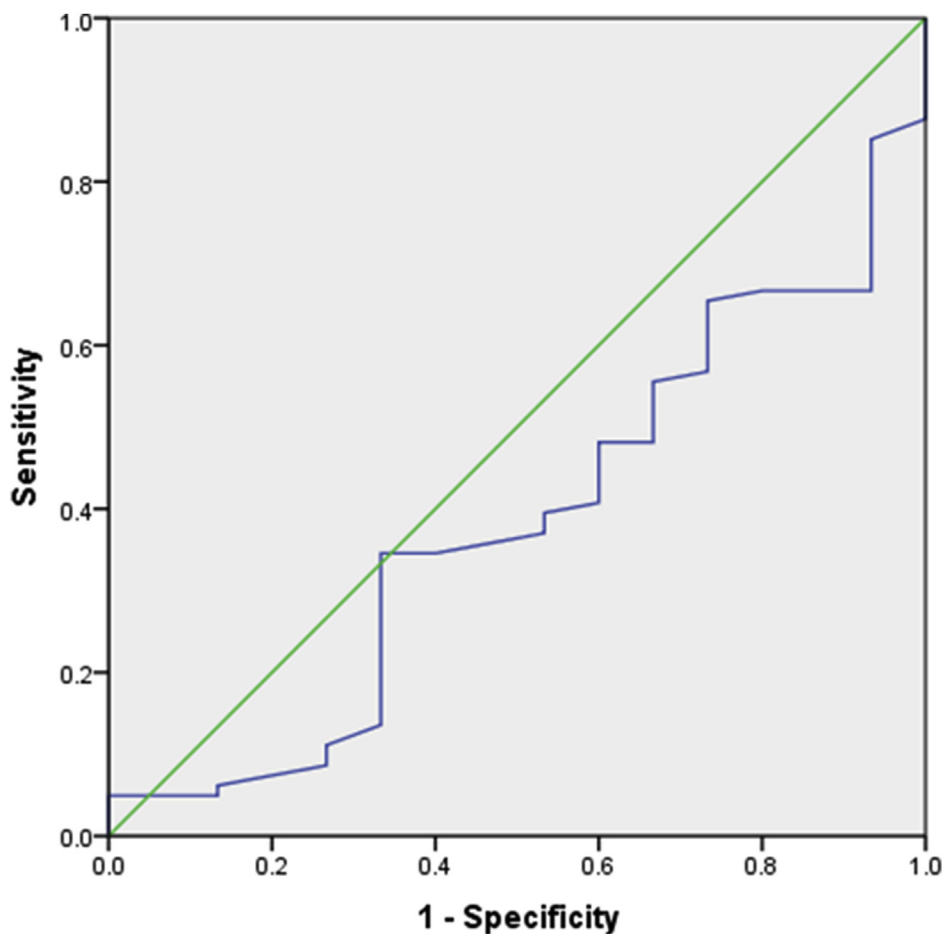


Fig. 3. Area below the ROC curve in 96 patients.

#### 4. Discussion

Correct and early diagnosis is the main goal in the treatment of acute appendicitis. Laboratory tests like leukocyte count, neutrophils [20,21], CRP (c-reactive protein), IL6 (interleukin-6), phospholipase A2, and other inflammatory mediators seem to have relatively low sensitivity and specificity in the differential diagnosis of appendicitis [22,23]. Clinical examination, if used with other diagnostic modalities, could be the most effective tool for the diagnosis of acute appendicitis [24,25].

Studies have recently been conducted on the urinary levels of 5-HIAA for the diagnosis of acute appendicitis [26]. Based on the findings from our study, urinary 5-HIAA cannot be used as a diagnostic predictor for acute appendicitis. We did not report any significant difference in the levels of 5-HIAA in patients presenting acute appendicitis and other pathological conditions.

Rordam et al. stated that in cases of acute appendicitis, serotonin secretion from appendicular enterochromaffin cells was increased, which has also been reported in animal models. Various studies have confirmed these findings, nonetheless, a vast amount of discrepancies are reported in this regards [27,28]. In this study, 5-HIAA levels were found to be lower in urine samples in patients with acute appendicitis. If we consider the cutoff point as 7.4  $\mu\text{mol/L}$  for 5-HIAA, the sensitivity of this test is 54.3% and its specificity is 27.1%. Boland-Parvaz et Al report that urinary 5-HIAA levels decrease in adult perforated appendicitis [29].

Furthermore, Rordam et al. stated that plasma serotonin levels has the sensitivity of 45% and specificity of 95% among acute appendicitis [30]. In a study by IKhanizadeh et al., urinary 5-HIAA had a sensitivity of 98% and specificity 100% in adults, while in the study by Mihmanli et al. the sensitivity was 22% and the specificity was 93% and urinary 5-HIAA was concluded to be inaccurate for the diagnosis of acute appendicitis [31]. Based on the findings of our study, due to high SD and low sensitivity and specificity, this test is not superior to other routine diagnostic methods. 5-HIAA was measured using HPLC (High-performance liquid chromatography), an easy, rapid, and practical method, that is also cost-effective as compared to ultrasound and CT scan. The levels of 5-HIAA can alter after consuming certain types of food and the existence of clinical conditions like carcinoid tumors, acute gastroenteritis, inflammatory bowel disease, celiac disease, and treatment with aminosalicylate. 5-HIAA does not change in a urine sample throughout the day, and its amounts are not related to gender. Even considering these factors for the differential diagnosis of this study, the high level of SD suggests that standardization of this test is not easy for all patients, which reduces the reliability of this test. Our study did not include healthy

control group for the reference range of 5-HIAA and data regarding other biochemical parameters (blood leukocyte and neutrophils count, c-reactive protein, interleukin-6) are also not evaluated.

## 5. Conclusion

Urinary 5-HIAA is reduced in acute appendicitis, but challenges associated with the standardization of this parameter limit its clinical use. Further studies on the sensitivity and specificity of this test in different populations are required with a larger sample size.

## Funding

None.

## Availability of data and material

Data sharing not applicable to this article as no datasets were generated or analyzed during the current study.

## Human and animal rights

No animals were used in this research. All human research procedures followed were in accordance with the ethical standards of the committee responsible for human experimentation (institutional and national), and with the Helsinki Declaration of 1975, as revised in 2013.

## Contributors' statement page

Dr. Leila Haji Maghsoudi: conceptualized and designed the study, drafted the initial manuscript, and reviewed and revised the manuscript.

Dr. Mojtaba Ahmadinejad and Ali Soltanian: Designed the data collection instruments, collected data, carried out the initial analyses, and reviewed and revised the manuscript.

Dr. Alireza Shirzadi and Dr. Reza Alizadeh-Kashani: Coordinated and supervised data collection, and critically reviewed the manuscript for important intellectual content.

All authors made a significant contribution to the work reported, whether that is in the conception, study design, execution, acquisition of data, analysis and interpretation, or in all these areas; took part in drafting, revising or critically reviewing the article; gave final approval of the version to be published; have agreed on the journal to which the article has been submitted; and agree to be accountable for all aspects of the work.

## Declaration of competing interest

The authors declare that they have no known competing financial interests or personal relationships that could have appeared to influence the work reported in this paper.

## References

- [1] A. Singh, M. Mansouri, B.M. Yeh, R.A. Novelline, *Acute Appendicitis*. Emergency Radiology, Springer, 2018, pp. 33–47.
- [2] M.D. Stringer, Acute appendicitis, *J. Paediatr. Child Health* 53 (11) (2017) 1071–1076, <https://doi.org/10.1111/jpc.13737> [published Online First: Epub Date].
- [3] G. Yetkin, M. Basak, A. Işg r, A. Kebudi, I. Akgun, Can negative appendectomy rate be decreased by using spiral computed tomography without contrast material? *Acta Chir. Belg.* 102 (5) (2002) 334–337.
- [4] A. Schwarz, E. Bolke, M. Peiper, et al., Inflammatory peritoneal reaction after perforated appendicitis: continuous peritoneal lavage versus non lavage, *Eur. J. Med. Res.* 12 (5) (2007) 200.
- [5] M. Sand, F.G. Bechara, T. Holland-Letz, D. Sand, G. Mehnert, B. Mann, Diagnostic value of hyperbilirubinemia as a predictive factor for appendiceal perforation in acute appendicitis, *Am. J. Surg.* 198 (2) (2009) 193–198.
- [6] K. Anderson, *Appendicitis*. Pediatric Surgery, 1998.
- [7] N. Maleki-Sadeghi, P. Rahmani, Z. Aghsaefard, G. Heidari, Effects of aminophylline on the levels of neutrophil gelatinase-associated lipocalin (NGAL) in asphyxiated term neonates, *Arch. Physiol. Biochem.* (2020) 1–6.
- [8] T. Dawes, C. Burrows, Abdominal pain and jaundice: appendiceal perforation an important differential, *Emerg. Med. Australasia (EMA)* 19 (3) (2007) 276–278.
- [9] F. Tarhani, A. Nezami, G. Heidari, Evaluating the usefulness of lab-based test for the diagnosis of pneumonia in children, *Int. J. Gen. Med.* (2020).
- [10] M. Faraji-Goodarzi, Sepsis after non-perforated acute appendicitis, *Clinical case reports* 7 (3) (2019) 520–523.
- [11] P. Rahmani, A. Ghouran-Orimi, F. Motamed, A. Moradzadeh, Evaluating the effects of probiotics in pediatrics with recurrent abdominal pain, *Clinical and Experimental Pediatrics* (2020).
- [12] H.Y. Tehrani, J.G. Petros, R.R. Kumar, Q. Chu, Markers of severe appendicitis, *Am. Surg.* 65 (5) (1999) 453.
- [13] O. Menten, M. Eryılmaz, A. Harlak, et al., The importance of urine 5-hydroxyindoleacetic acid levels in the early diagnosis of acute appendicitis, *Am. J. Emerg. Med.* 27 (4) (2009) 409–412.
- [14] M. Faraji-Goodarzi, Pseudo-Bartter syndrome in children with cystic fibrosis, *Clinical Case Reports* 7 (6) (2019) 1123–1126.
- [15] M. Ahmadinejad, T. BahramiBabaheidari, R. NabiAmjad, A. Hashemi, M. Moqadasi, A case report of acute eosinophilic appendicitis, *Alborz University Medical Journal* 8 (1) (2019) 69–74.

- [16] A. Rao, M. Wilson, G. Kennedy, D. Mittapalli, I. Tait, A. Alijani, Spot urinary 5-hydroxyindoleacetic acid is not an ideal diagnostic test for acute appendicitis, *Am. J. Emerg. Med.* 34 (9) (2016) 1750–1753, <https://doi.org/10.1016/j.ajem.2016.05.059> [published Online First: Epub Date].
- [17] A. Nezami, F. Tarhani, N.K. Shoshtari, Organic lesions in the brain MRI of children with febrile seizure, *Current Medical Imaging* (2020).
- [18] D.R. Flum, T. Koepsell, The clinical and economic correlates of misdiagnosed appendicitis: nationwide analysis, *Arch. Surg.* 137 (7) (2002) 799–804.
- [19] R. Hernandez, A. Jain, L. Rosiere, S.O. Henderson, A prospective clinical trial evaluating urinary 5-hydroxyindoleacetic acid levels in the diagnosis of acute appendicitis, *Am. J. Emerg. Med.* 26 (3) (2008) 282–286.
- [20] Z. Aghsaiefard, R. Alizadeh, Drug-induced interstitial nephritis as a result of sodium valproate and triamterene, *Urology Case Reports* 33 (2020) 101329.
- [21] Z. Aghsaiefard, R. Alizadeh, N. Bagheri, Association between neutrophil gelatinase-associated lipocalin (NGAL) and iron profile in chronic renal disease, *Arch. Physiol. Biochem.* (2020) 1–5.
- [22] I.P. Kema, E.G. de Vries, F.A. Muskiet, Clinical chemistry of serotonin and metabolites, *J. Chromatogr. B Biomed. Sci. Appl.* 747 (1–2) (2000) 33–48.
- [23] F. Almassinokiani, M. Ghoraian, H. Akbari, et al., Acute Appendicitis Following Laparoscopic Hysterectomy, 2012.
- [24] J.J. Estrada, M. Petrosyan, J. Barnhart, et al., Hyperbilirubinemia in appendicitis: a new predictor of perforation, *J. Gastrointest. Surg.* 11 (6) (2007) 714–718.
- [25] Z. Aghsaiefard, Z. Hossenifard, R. Alizadeh, T. Ramim, The relationship between hemoglobin level with PTH level and dialysis adequacy in chronic hemodialysis patients, *Tehran Univ. Med. J.* 76 (4) (2018) 257–264.
- [26] A. Mojtaba, H. Seyed Mozaffar, J. Mahnaz, Risk factors associated in acute appendicitis in pregnancy, *Current Women's Health Reviews* 16 (2020) 1–6, <https://doi.org/10.2174/1573404816999201012194315> ([published Online First: Epub Date]).
- [27] S. Apak, A. Kazez, S.K. Ozel, B. Ustundag, N. Akpolat, A. Kizirgil, Spot urine 5-hydroxyindoleacetic acid levels in the early diagnosis of acute appendicitis, *J. Pediatr. Surg.* 40 (9) (2005) 1436–1439.
- [28] A. Jangjoo, A.-R. Varasteh, M.M. Bahar, et al., Is urinary 5-hydroxyindoleacetic acid helpful for early diagnosis of acute appendicitis? *Am. J. Emerg. Med.* 30 (4) (2012) 540–544.
- [29] S. Bolandparvaz, M. Vasei, A.A. Owji, et al., Urinary 5-hydroxy indole acetic acid as a test for early diagnosis of acute appendicitis, *Clin. Biochem.* 37 (11) (2004) 985–989.
- [30] P. Rørdam, P. Mortensen, I. Hindberg, J. Christiansen, Acute appendicitis and plasma concentration of serotonin, *Acta Chir. Scand.* 153 (7–8) (1987) 437–439.
- [31] I. Mihmanli, F. Kantarci, Sonography of scrotal abnormalities in adults: an update, *Diagn. Interventional Radiol.* 15 (1) (2009) 64.