

The value of the sacroiliac joint area as a new morphological parameter of ankylosing spondylitis

Yun-Sic Bang, MD^a, He Won Hwang, MD^a, Hanwool Bae, MD^a, Young-Soon Choi, MD, PhD^b, Youngsu Lim, MD, PhD^b, Jungmin Yi, MD^b, Hyunhae Kim, MD^b, Min-Ying Su, PhD^c, Young Uk Kim, MD, PhD^{b,*}

Abstract

A narrowed sacroiliac joint (SIJ) space has been considered to be a major morphologic parameter of ankylosing spondylitis (AS). Previous studies revealed that the sacroiliac joint thickness (SIJT) correlated with AS in patients. However, irregular narrowing is different from thickness. Thus, we devised a method using the sacroiliac joint cross-sectional area (SIJA) as a new morphological parameter for use in evaluating AS. We hypothesized that the SIJA is a key morphologic parameter in diagnosing AS. SIJ samples were collected from 107 patients with AS, and from 85 control subjects who underwent SIJ-view X-rays that revealed no evidence of AS. We measured the SIJT and SIJA at the SIJ margin on X-rays using our picture archiving and communications system. The SIJT was measured at the narrowest point between the sacrum and the ilium. The SIJA was measured as the entire cross-sectional joint space area of the SIJ in the X-ray images. The average SIJT was 3.09 ± 0.61 mm in the control group, and 1.59 ± 0.52 mm in the AS group. The average SIJA was 166.74 ± 39.98 mm² in the control group, and 68.65 ± 24.11 mm² in the AS group. AS patients had significantly lower SIJT ($P < .001$) and SIJA ($P < .001$) than the control subjects. Receiver operating characteristics curve analysis showed that the best cutoff point for the SIJT was 2.33 mm, with 92.5% sensitivity, 94.1% specificity, and an area under the curve of 0.97 (95% confidence interval: 0.95–0.99). The optimal cutoff point for the SIJA was 106.19 mm², with 93.5% sensitivity, 95.3% specificity, and an area under the curve of 0.98 (95% confidence interval: 0.97–1.00). Although the SIJT and SIJA were both significantly associated with AS, the SIJA parameter was a more sensitive measurement. We concluded that the SIJA is an easy-to-use, fast, cheap, and useful new morphological parameter for predicting AS.

Abbreviations: AS = ankylosing spondylitis, AUC = area under the curve, CI = confidence interval, MRI = magnetic resonance imaging, SIJ = sacroiliac joint, SIJA = sacroiliac joint cross-sectional area, SIJT = sacroiliac joint thickness.

Keywords: Ankylosing spondylitis, cross-sectional area, Sacroiliac joint, thickness

1. Introduction

Ankylosing spondylitis (AS) is a common inflammatory rheumatic disorder that affects the axial skeleton, the spinal column, and adjacent joints, and its progression leads to a decline in the functional capacity of the patients.^[1–3] The involvement of other joints in the complex articulation of the hip may also be present.^[4–6] The evolution of the symptoms and signs of AS is very much related to decreases in spinal mobility, column stiffness, function, and pain.^[7–9] Radiographic images show minimal changes in response to earlier acute inflammation. Thus, the detection of radiographic abnormalities is frequently delayed. In the spine, abnormalities progress from reactive sclerosis (Romanus lesion or “shiny corner”) and erosions and squaring at the edge of the vertebral bodies to bony bridging and syndesmophyte formation.^[7–9] Magnetic resonance imaging (MRI) is sometimes considered when there is a high clinical suspicion of AS but previous X-rays were normal. MRI can facilitate earlier

AS diagnoses, but the results can be normal even in patients with active AS, and the chronic changes of sacroiliac joint inflammation are better seen on standard X-rays.^[10] Additionally, MRI is expensive and not always available. AS inflames the sacroiliac joints located between the pelvis and the base of the spine. This sacroiliitis is one of the first signs of AS. Inflammation often spreads to joints between the vertebrae that make up the spinal column.

These observations led us to search for a new, easy-to-use, objective, and cheap morphological method. Previous studies assessed sacroiliac joint thickness (SIJT) using a single measurement point, described as the approximate halfway, middle or any location on the sacroiliac joint (SIJ).^[7,8,10] However, new bone formation, inflammatory changes, deformity, and asymmetrical narrowing of the SIJ have been reported to occur throughout the SIJ.^[11,12] Thus, different findings may result from the use of different measurement locations. In contrast to the SIJT, the cross-sectional area of the SIJ does not incur

The authors have no conflicts of interest to disclose.

The datasets generated during and/or analyzed during the current study are available from the corresponding author on reasonable request.

^a Department of Anesthesiology and Pain Medicine, CHA Bundang Medical Center, CHA University, Seongnam, Republic of Korea, ^b Department of Anesthesiology and Pain Medicine, Catholic Kwandong University of Korea College of Medicine, International ST. Mary's Hospital, Incheon, Republic of Korea, ^c Department of Radiological Sciences, University of California, Irvine, CA.

* Correspondence: Young Uk Kim, Department of Anesthesiology and Pain Medicine, Catholic Kwandong University, College of Medicine, International ST. Mary's Hospital, Simgokro 100Gil 25 Seo-gu, Incheon City 22711, Republic of Korea (e-mail: uk201@hanmail.net).

Copyright © 2022 the Author(s). Published by Wolters Kluwer Health, Inc. This is an open-access article distributed under the terms of the Creative Commons Attribution-Non Commercial License 4.0 (CCBY-NC), where it is permissible to download, share, remix, transform, and buildup the work provided it is properly cited. The work cannot be used commercially without permission from the journal.

How to cite this article: Bang Y-S, Hwang HW, Bae H, Choi Y-S, Lim Y, Yi J, Kim H, Su M-Y, Kim YU. The value of the sacroiliac joint area as a new morphological parameter of ankylosing spondylitis. *Medicine* 2022;101:45(e31723).

Received: 28 November 2021 / Received in final form: 18 October 2022 / Accepted: 19 October 2022

<http://dx.doi.org/10.1097/MD.00000000000031723>

these measurement differences because it measures the entire cross-sectional area of the SIJ. Therefore, to evaluate the irregular narrowing of the whole SIJ, we devised a method using the sacroiliac joint cross-sectional area (SIJA) as a new morphological parameter. We hypothesized that the SIJA is an important morphological parameter in diagnosing AS. We used SIJ X-rays to compare the SIJA and SIJT between AS patients and a control group.

2. Methods and material

2.1. Patients

This observational study was approved by University of Catholic Kwandong Institutional Review Board (IRB number: IS18RISI0078). We retrospectively reviewed the patients who visited our rheumatic center from December 2014 to February 2018, and who were diagnosed with AS. The inclusion criteria were as follows: a history of chronic dull pain in the gluteal region or lower back combined with stiffness of the lower back, SIJ X-ray views taken and available for review, patients positive for the HLA-B27 biomarker, a past history of inflammation in the heels, joints, or tendon-bone attachments, and/or signs of increased inflammation (erythrocyte sedimentation rate or C-reactive protein). We excluded patients if they had any of the following problems: a history of lumbar or hip surgery, a history of lumbar or hip fracture, or any other neuromuscular disease.

A total of 107 individuals who met our enrollment criteria were included after an AS diagnosis was confirmed by an experienced board-certified rheumatologist and a musculoskeletal radiologist. Fifty-one (47.66%) men and 56 (52.34%) women with a mean age of 42.29 ± 12.06 years (range, 17–71 years) were included in the study (Table 1). All patients underwent an SIJ-view X-ray. To compare the SIJT and SIJA between patients with and without AS, we also enrolled a control group of subjects who underwent SIJ-view X-rays from December 2014 to May 2017, which revealed no evidence of AS. We only enrolled patients in the control group who did not have AS-related symptoms. In the control group, 85 individuals (57 males and 28 females) were enrolled with a mean age of 39.42 ± 11.97 years (range, 18–66 years).

2.2. Image analysis

SIJT and SIJA measurements were performed by the same expert, who was blinded to the SIJ classification. We obtained SIJ X-ray view images at the best visualization of the SIJ. We measured the SIJT and SIJA on X-rays using a picture archiving and communications system (INFINITT; Infinitt Healthcare, Seoul, Korea). The SIJT was measured at the narrowest point. The SIJA was measured as the entire SIJ cross-sectional area (Figs. 1 and 2A and 2B).

Table 1
Comparison of the characteristics of control and AS groups.

Variables	Control group (n = 85)	AS group (n = 107)	Statistical significance
Gender (male/female)	57/28	51/56	NS
Age (yr)	39.42 ± 11.97	42.29 ± 12.06	NS
SIJT (mm)	3.09 ± 0.61	1.59 ± 0.52	$P < .001$
SIJA (mm ²)	166.74 ± 39.98	68.65 ± 24.11	$P < .001$

Data represent the mean \pm SD or the numbers of patients.

AS = ankylosing spondylitis, NS = not statistically significant ($P > .05$), SIJA = sacroiliac joint cross-sectional area, SIJT = sacroiliac joint thickness.

2.3. Statistical analysis

The data are presented as mean and standard deviation. We compared the SIJT and SIJA between the AS and normal control groups using unpaired *t* tests. The validity of the SIJT and SIJA for diagnosing AS was estimated by ROC curves.

3. Results

The average SIJT was 3.09 ± 0.61 mm in the control group and 1.59 ± 0.52 mm in the AS group. The average SIJA was 166.74 ± 39.98 mm² in the control group and 68.65 ± 24.11 mm² in the AS group. AS patients had significantly lower SIJT ($P < .001$) and SIJA ($P < .001$) than the control subjects (Table 1). The ROC curve analysis showed that the best cutoff point for the SIJT was 2.33 mm, with 92.5% sensitivity, 94.1% specificity (Table 2), and an area under the curve (AUC) of 0.97 (95% confidence interval [CI]: 0.95–0.99) (Fig. 3). The optimal cutoff point for the SIJA was 106.19 mm², with 93.5% sensitivity, 95.3% specificity, and an AUC of 0.98 (95% CI: 0.97–1.00) (Table 3; Fig. 3).

4. Discussion

AS is a common, chronic, debilitating, idiopathic inflammatory disease, affecting approximately 1.4% of the general population. AS can be the consequence of a pathological process characterized by bone hypertrophy, new bone formation, sacroiliitis, and enthesitis.^[13–16] AS most frequently presents with clinical symptoms that include spinal ankyloses, fusion, inflammatory back stiffness, and pain. As the disorder progresses, AS has an increasingly negative effect on patients' daily lives.^[17,18] Moreover, it can cause frustration and reactive anxiety, increase the economic burden, and negatively influence patients' social interactions. The extra-axial manifestations of AS include peripheral arthritis, acute uveitis, enthesitis, aortic root, gut inflammation, and psoriasis.^[19] AS also involves both unusual bony overgrowth and inflammatory erosive osteopenia. From the patient's perspective, years of rigid, painful stooped posture incurs significant economic costs and disability. Due to the slowly progressive nature of AS, delays between the onset of symptoms and diagnosis of up to 8 to 10 years have been reported.^[1,2,5] Unfortunately, the most effective medications, biologic agents that inhibit tumor necrosis factor-alpha, are best given early in the disease when the inflammatory burden is greatest.^[18] Considering the insufficient therapeutic options and diagnostic delays, a greater understanding of pathogenesis is required. Various imaging modalities, such as X-rays, MRI, and ultrasonography, are commonly used. A single SIJ X-ray view should be adequate to assess the sacroiliac joints.^[15,20] However, a diagnosis of AS based on radiographic abnormalities is typically delayed because there are no objective diagnostic criteria. MRI is often considered when there is clinical suspicion of AS, but standard X-rays have yielded normal results. MRI may be particularly helpful in early disease, although it can be normal even in patients with active AS, and the chronic changes of sacroiliitis are better seen on standard X-rays. However, MRI is expensive and not always available. Ultrasonography can be useful in detecting enthesitis, but it has challenges related to the detection of spine and sacroiliac problems.^[21–24] Clearly, the diagnosis of AS would be easier if a more reliable morphological parameter could be found. Thus, we undertook investigations aimed at finding a new, easy-to-use, objective, and cheap morphological method. Previous studies assessed SIJT by a single measurement made at the approximate narrowest, middle or any location on the SIJ.^[7,10] However, new bone formation, inflammatory changes, deformity, and asymmetrical narrowing of the SIJ can occur throughout the SIJ. Thus, the SIJT measurement location can dramatically influence the findings. We hypothesized that the

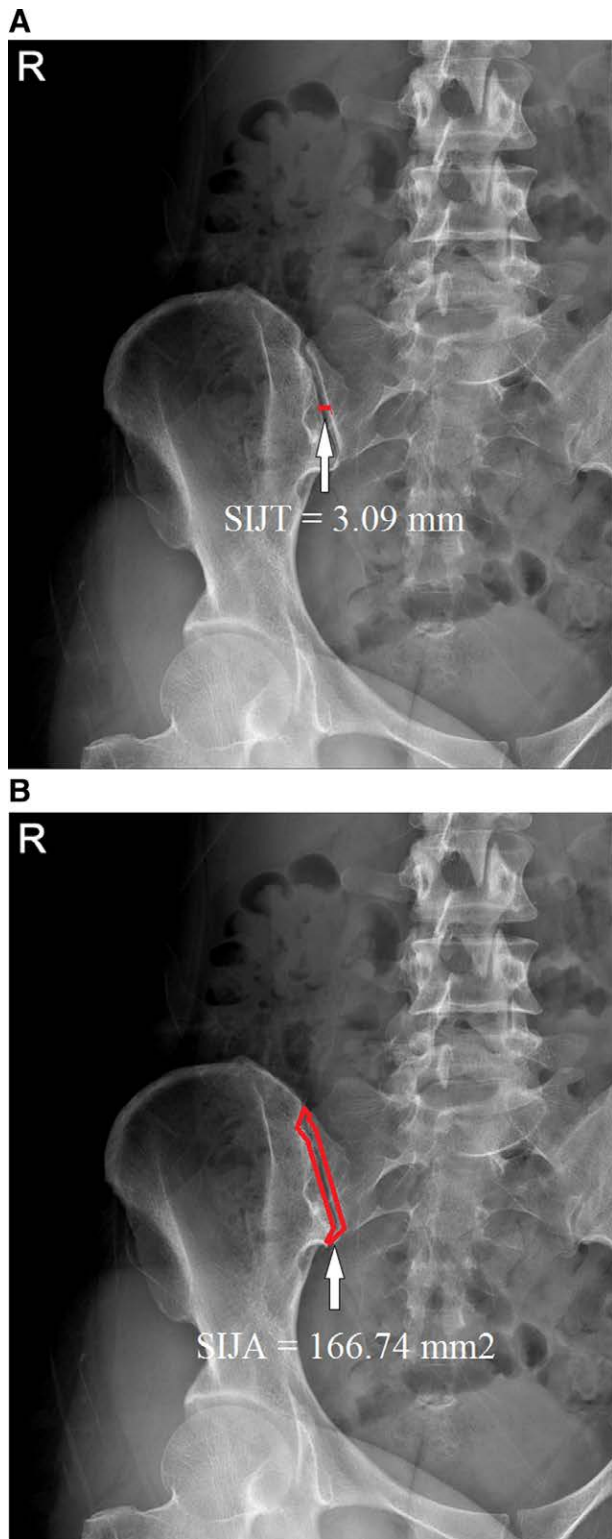


Figure 1. Measurement of both SIJT (white arrow) (A) and sacroiliac joint cross-SIJA (white arrow) (B) in the normal control group was carried out on sacroiliac joint-view X-ray images. SIJA = sacroiliac joint cross-sectional area, SIJT = sacroiliac joint thickness.

entire cross-sectional ligament area of the SIJ may predict AS, and since SIJA measures the entire cross-sectional area of the SIJ, errors due to the measurement location are eliminated. Finally, we found that the SIJA was a better morphologic parameter of AS than the SIJT. In the current study, we found that the SIJA had 93.5% sensitivity, 95.3% specificity, and an

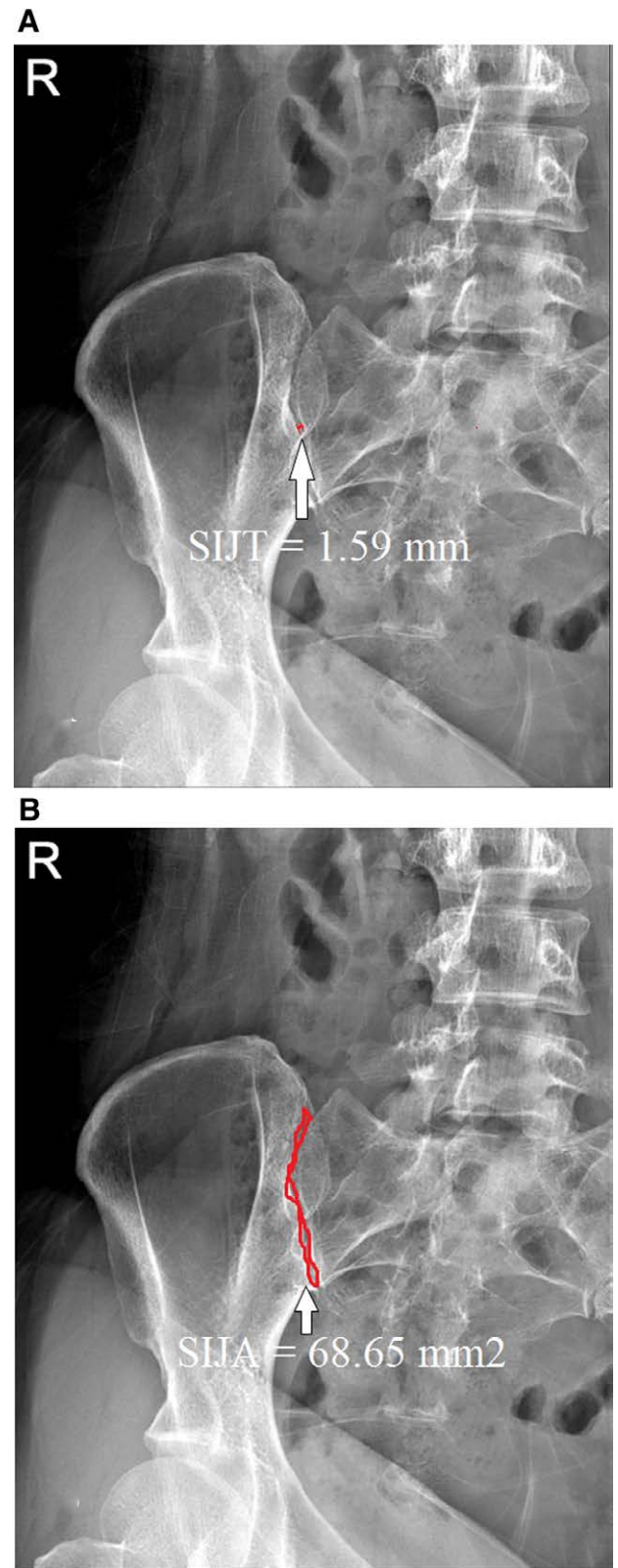


Figure 2. Measurement of both SIJT (white arrow) (A) and SIJA (white arrow) (B) in the ankylosing spondylitis group was carried out on sacroiliac joint-view X-ray images. New bone formation, deformity, and asymmetrical narrowing of the sacroiliac joint were observed. SIJA = sacroiliac joint cross-sectional area, SIJT = sacroiliac joint thickness.

AUC of 0.98 (95% CI: 0.97–1.00) in predicting AS. In contrast, the SIJT had 92.5% sensitivity, 94.1% specificity, and an AUC of 0.97 (95% CI: 0.95–0.99). These findings suggest

Table 2
Sensitivity and specificity of each cutoff point of the SIJT.

SIJT (mm)	Sensitivity (%)	Specificity (%)
1.23	26.2	100
1.51	41.1	97.6
2.08	82.2	96.5
2.33 ^a	92.5	94.1
2.61	99.1	82.4
2.83	100	65.9

SIJT = sacroiliac joint thickness.

^aThe best cutoff point on the receiver operating characteristic curve.

Table 3
Sensitivity and specificity of each cutoff point of the SIJA.

SIJA (mm ²)	Sensitivity (%)	Specificity (%)
48.88	20.6	100
76.29	62.6	98.8
95.33	89.7	98.8
106.19 ^a	93.5	95.3
134.25	98.1	78.8
154.01	100	60

SIJA = sacroiliac joint cross-sectional area.

^aThe best cutoff point on the receiver operating characteristic curve.

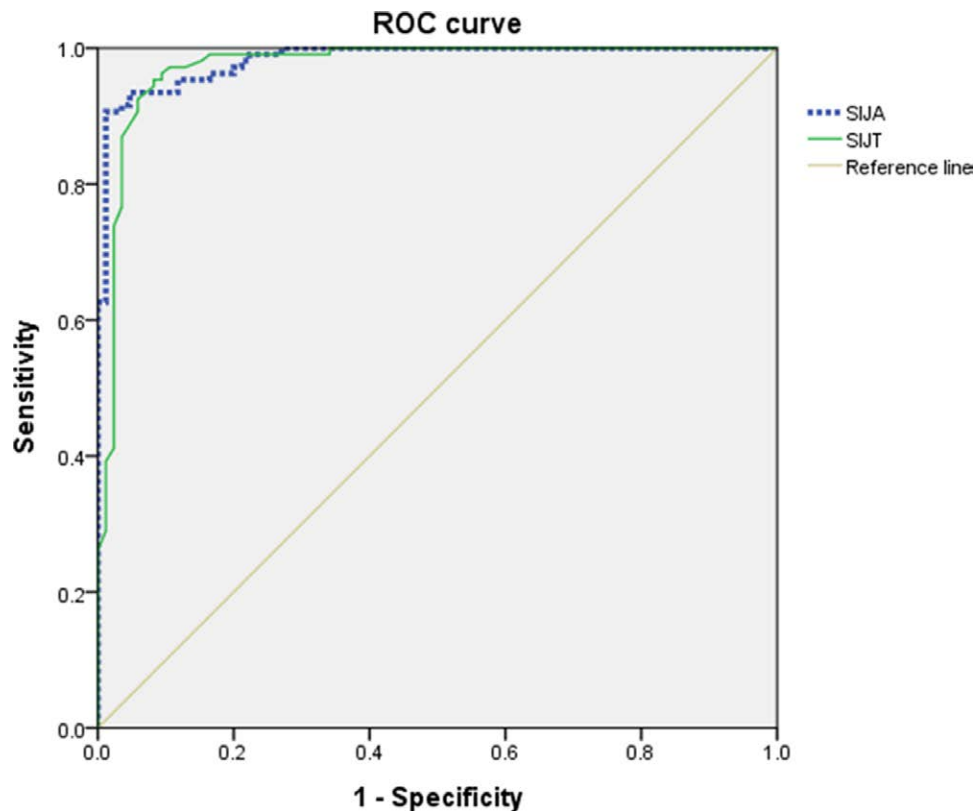


Figure 3. ROC curve of SIJA and SIJT for predicting AS. The best cutoff point of SIJA was 106.19 mm² versus 2.37 mm for SIJT, with a sensitivity of 93.5% versus 92.5%, specificity of 95.3% versus 94.1%, and an AUC of 0.98 versus 0.97, respectively. SIJA AUC (95% CI): 0.98 (0.97–1.00). SIJT AUC (95% CI): 0.97 (0.95–0.99). AS = ankylosing spondylitis, AUC = area under the curve, CI = confidence interval, ROC = receiver operating characteristic, SIJA = sacroiliac joint cross-sectional area, SIJT = sacroiliac joint thickness.

that the SIJA is a better predictor of AS than the SIJT. The greatest advantage the SIJA has over other methods is its ease of use—the physician only needs to select the SIJ X-ray view with a mouse click—validity, and reliability and, therefore, we propose it for use in clinical practice. An additional advantage of this method is that it is less expensive than other imaging modalities, such as MRI and ultrasonography.

To interpret these results, some limitations must be taken into account. The small sample size, despite being enough to test reliability consistently, was relatively small and will be corrected in ongoing validation studies. Second, there was no consensus on the diagnosis of AS. Thus, numerous different diagnostic tools, such as the HLA B-27 biomarker, lumbar spine MRI, ultrasonography, and grading system were used to make the diagnosis.^[18] We chose to focus on the SIJ-view X-ray only for developing our new parameter. Despite these limitations, this was the first objective study to verify SIJA in patients with AS, and we conclude that these findings represent an easy and quick method for detecting AS in any patient using a simple X-ray.

5. Conclusion

Although the SIJT and SIJA were both significantly associated with AS, the SIJA was a more sensitive measurement parameter. We concluded that the SIJA is easy to use, fast, cheap, and a useful new morphological parameter for predicting AS.

Acknowledgments

The authors thank International St. Mary's Hospital.

Author contributions

Conceptualization: Young Uk Kim.

Formal analysis: Young Uk Kim.

Investigation: Yun-Sic Bang.

Methodology: Young-Soon Choi, Youngsu Lim, Hyunhae Kim.

Supervision: Young Uk Kim.

Validation: Young Uk Kim.

Visualization: Young Uk Kim.

Writing – original draft: Young Uk Kim.

Writing – review & editing: Yun-Sic Bang, He Won Hwang, Hanwool Bae, Jungmin Yi, Min-Ying Su, Young Uk Kim.

References

- [1] Esfahani DR, Shah HP, Behbahani M, et al. Spinal subdural hematoma and ankylosing spondylitis: case report and review of literature. *Spinal Cord Ser Cases*. 2018;4:30.
- [2] Macfarlane TV, Abbood HM, Pathan E, et al. Relationship between diet and ankylosing spondylitis: a systematic review. *Eur J Rheumatol*. 2018;5:45–52.
- [3] Yuan Y, Yang J, Zhang X, et al. Carotid intima-media thickness in patients with ankylosing spondylitis: a systematic review and updated meta-analysis. *J Atheroscler Thromb*. 2019;26:260–71.
- [4] Chen B, Li J, He C, et al. Role of HLA-B27 in the pathogenesis of ankylosing spondylitis (review). *Mol Med Rep*. 2017;15:1943–51.
- [5] Sharan D, Rajkumar JS. Physiotherapy for ankylosing spondylitis: systematic review and a proposed rehabilitation protocol. *Curr Rheumatol Rev*. 2017;13:121–5.
- [6] Zao A, Cantista P. The role of land and aquatic exercise in ankylosing spondylitis: a systematic review. *Rheumatol Int*. 2017;37:1979–90.
- [7] Gao D, Li KP, Wen QF, et al. [A preliminary exploration of low-dose semicoronal CT of the sacroiliac joints in the diagnosis of ankylosing spondylitis]. *Zhonghua Nei Ke Za Zhi*. 2016;55:355–60.
- [8] Gao D, Li KP, Wen QF, et al. [Comparative study of different grading criteria of sacroiliac joint computed tomography in ankylosing spondylitis]. *Zhonghua Yi Xue Za Zhi*. 2016;96:3137–41.
- [9] Corbett M, Soares M, Jhuti G, et al. Tumour necrosis factor-alpha inhibitors for ankylosing spondylitis and non-radiographic axial spondyloarthritis: a systematic review and economic evaluation. *Health Technol Assess*. 2016;20:1v–334vi.
- [10] Kang KY, Jung JY, Hong YS, et al. Positive correlation between inflammation on sacroiliac joint MRI and serum C-terminal telopeptide of type-I collagen in ankylosing spondylitis but not in non-radiographic axial spondyloarthritis. *Clin Exp Rheumatol*. 2017;35:415–22.
- [11] Pedersen SJ, Weber U, Said-Nahal R, et al. Structural progression rate decreases over time on serial radiography and magnetic resonance imaging of sacroiliac joints and spine in a five-year follow-up study of patients with ankylosing spondylitis treated with tumour necrosis factor inhibitor. *Scand J Rheumatol*. 2019;48:185–97.
- [12] Guo RM, Lin WS, Liu WM, et al. Quantification of fat infiltration in the sacroiliac joints with ankylosing spondylitis using IDEAL sequence. *Clin Radiol*. 2018;73:231–6.
- [13] Syeda SS, Jugl SM, Gunda P. Review of patient reported outcome measures used in clinical and cost-effectiveness studies to measure utilities in the treatment of psoriatic arthritis and ankylosing spondylitis. *Value Health*. 2015;18:A651.
- [14] Ratz T, Dean LE, Atzeni F, et al. A possible link between ankylosing spondylitis and periodontitis: a systematic review and meta-analysis. *Rheumatology (Oxford)*. 2015;54:500–10.
- [15] Manchikanti L, Staats PS, Nampiarampil DE, et al. What is the role of epidural injections in the treatment of lumbar discogenic pain: a systematic review of comparative analysis with fusion. *Korean J Pain*. 2015;28:75–87.
- [16] Malinowski KP, Kawalec P. The indirect costs of ankylosing spondylitis: a systematic review and meta-analysis. *Expert Rev Pharmacoecon Outcomes Res*. 2015;15:285–300.
- [17] Tarhan F, Argin M, Can G, et al. Coexistence of systemic lupus erythematosus and ankylosing spondylitis: another case report and review of the literature. *Eur J Rheumatol*. 2014;1:39–43.
- [18] Haroon NN, Sriganthan J, Al Ghanim N, et al. Effect of TNF-alpha inhibitor treatment on bone mineral density in patients with ankylosing spondylitis: a systematic review and meta-analysis. *Semin Arthritis Rheum*. 2014;44:155–61.
- [19] Coiffier G, Bouvard B, Chopin F, et al. Common bone turnover markers in rheumatoid arthritis and ankylosing spondylitis: a literature review. *Joint Bone Spine*. 2013;80:250–7.
- [20] Yi YR, Lee NR, Kwon YS, et al. Pulsed radiofrequency application for the treatment of pain secondary to sacroiliac joint metastases. *Korean J Pain*. 2016;29:53–6.
- [21] Abdelbaser I, Mageed NA, Elfayoumy SI, et al. The effect of ultrasound-guided bilateral thoracic retrolaminar block on analgesia after pediatric open cardiac surgery: a randomized controlled double-blind study. *Korean J Anesthesiol*. 2022;75:276–82.
- [22] Agarwal R, Jain G, Agarwal A, et al. Effectiveness of four ultrasonographic parameters as predictors of difficult intubation in patients without anticipated difficult airway. *Korean J Anesthesiol*. 2021;74:134–41.
- [23] Al-Redouan A, Kachlik D. Suprascapular notch cross-sectional area by MRI do not yield accuracy in the diagnosis of suprascapular nerve entrapment – counter point of view [published online ahead of print August 16, 2022]. *Korean J Anesthesiol*. doi:10.4097/kja.22435.
- [24] Baek SJ, Lee JW, Chung S, et al. Clinical usefulness of ultrasound as an early diagnostic tool for neuroleukemiosis – a case report. *Korean J Anesthesiol*. 2021;74:65–9.