

The imaging and pathological features of metastatic leiomyosarcoma in the gallbladder

Yi Guo,¹ Eleanor Chen,¹
Darin J. Davidson,¹ Venu G. Pillarisetty,¹
Robin L. Jones,² Seth M. Pollack^{1,3}

¹University of Washington Medical Center, Seattle, WA, USA; ²Royal Marsden Hospital, London, UK; ³Fred Hutchinson Cancer Research Center, University of Washington, Seattle, WA, USA

Abstract

Uterine leiomyosarcoma is a rare and aggressive malignancy with poor overall prognosis. There have been few reports of metastatic leiomyosarcoma in the gallbladder. We report a case of a 41-year-old female who underwent total abdominal hysterectomy due to presumed uterine fibroids. The postoperative pathology revealed high-grade pleomorphic leiomyosarcoma, with involvement of the uterine serosal surface. She subsequently underwent exploratory laparotomy, followed by pelvic radiation and chemotherapy. Since initial management she has developed metastatic disease and has been under treatment and surveillance for 11 years. She has undergone multiple surgical procedures and numerous lines of systemic therapy for metastatic leiomyosarcoma, including cholecystectomy for a metastatic lesion in the gallbladder. There have been no previous reports of metastatic leiomyosarcoma in the gallbladder. Despite extensive metastatic disease this patient has had prolonged survival with multi-modality management.

Introduction

Uterine leiomyosarcoma is a rare, aggressive smooth muscle malignancy, comprising 1-2% of uterine malignancies.¹ It is often diagnosed incidentally after hysterectomy or myomectomy for a presumed benign leiomyoma or other benign lesions. The prognosis of uterine leiomyosarcoma is very poor due to high rate of recurrence and metastasis.² Despite optimal local management, many patients die of distant metastatic disease. Metastatic sites often include the lungs, liver, brain and bone.³ Other rare metastatic sites have been reported, such as breast, bile duct, bowel, pancreas, skull, adrenal gland and

heart.⁴⁻¹² However, to our knowledge there are no published reports of metastatic leiomyosarcoma of the gallbladder. Here, we present an extremely rare case of uterine leiomyosarcoma, with gallbladder metastasis along with lung, chest wall and thigh metastasis.

Case Report

A 41-year-old woman presented with vaginal bleeding and was found to have uterine fibroids on ultrasound. She underwent total abdominal hysterectomy at another center, and the pathology was reported as high-grade uterine leiomyosarcoma measuring 9 cm. She was then referred to our institution and underwent an exploratory laparotomy, extensive lysis of adhesions and left radical parametrectomy and omentectomy. She subsequently received 6 cycles of adjuvant gemcitabine and docetaxel followed by adjuvant radiation. Two years after the completion of adjuvant chemotherapy a surveillance scan detected lung metastases (Figure 1) and she subsequently underwent a left thorascopic wedge resection followed by 6 cycles of doxorubicin. Six months later a re-staging computed tomography (CT) demonstrated increasing metastatic disease in the lungs and she was treated with 6 cycles of temozolamide. A CT scan following 6 cycles showed stable disease. She then underwent a right thorascopic wedge resection and was treated with 4 cycles of liposomal doxorubicin. A repeat CT showed stable lung nodules. Four cycles of trabectedin were then administered but she tolerated these poorly with grade 3 fatigue. She received 5 cycles of temozolamide with disease progression. She then underwent a left video-assisted thorascopic surgery resection and right thoracotomy wedge resection and was subsequently commenced on gemcitabine and docetaxel with bevacizumab. Following 6 cycles of gemcitabine and docetaxel she continued on single agent bevacizumab, with durable stable disease.

Three months following discontinuation of bevacizumab repeat imaging demonstrated a mass in the gall bladder, measuring 2.8×2.2×1.8 cm (Figure 2A). The patient had no obvious symptoms. Six months later, follow-up CT demonstrated increased size of the mass, measuring 5.0×4.2×2.5 cm (Figure 2B). She then underwent cholecystectomy. Pathology confirmed metastatic leiomyosarcoma in the gallbladder (6.5 cm), with tumor involving the wall of the gallbladder with extension into mucosa but not beyond the serosa and not involving perigallbladder fat (Figure 3). Immunohistochemistry showed the tumor cells to be strongly positive for smooth muscle actin (Figure 4).

Repeat imaging also demonstrated a right

Correspondence: Seth M. Pollack, University of Washington Medical Center, Fred Hutchinson Cancer Research Center, University of Washington, 1959 NE Pacific St, Seattle, WA 98195, USA.
Tel.: +1.2066676629.
E-mail: spollack@fredhutch.org

Key words: Leiomyosarcoma; Uterine; Gallbladder; Metastasis.

Contributions: YG, DJD, VGP, RLJ and SMP collected clinical data of this case, interpreted the data, drafted and revised the manuscript; EC collected and analyzed the pathology figures.

Funding: the Gilman Family Sarcoma Research Fund.

Conflict of interest: the authors declare no potential conflict of interest.

Received for publication: 24 May 2016.
Accepted for publication: 17 August 2016.

This work is licensed under a Creative Commons Attribution NonCommercial 4.0 License (CC BY-NC 4.0).

©Copyright Yi Guo et al., 2016
Licensee PAGEPress, Italy
Rare Tumors 2016; 8:6618
doi:10.4081/rt.2016.6618

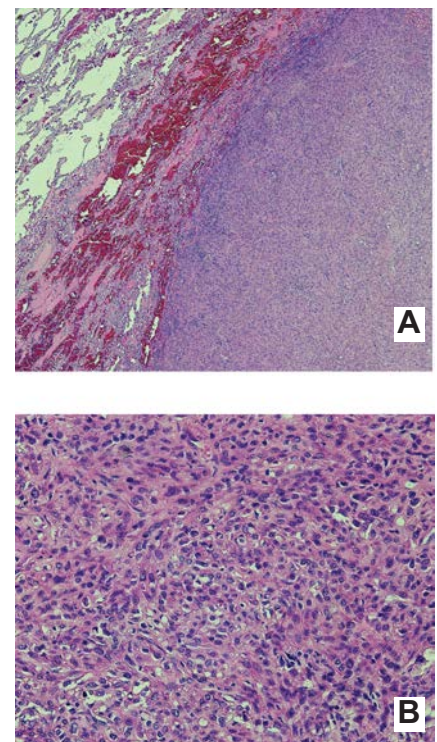


Figure 1. Pathology of lung metastasis, showing the tumor involving the lung parenchyma. A) 4×; B) 20×.

chest wall mass and a right posterior thigh mass. She underwent resection of all those lesions. Most recently, imaging showed multi-

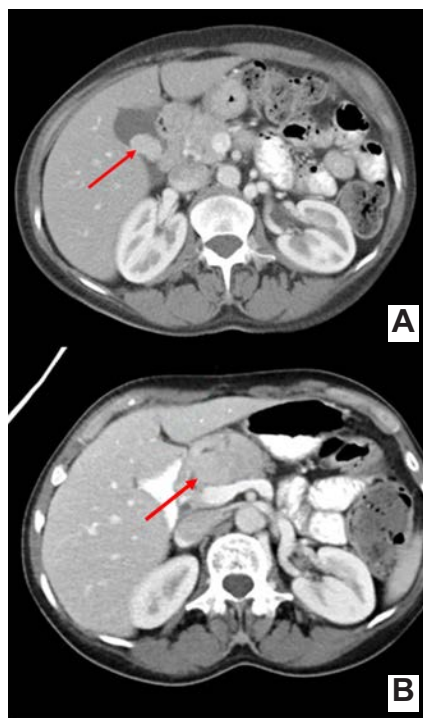


Figure 2. Abdomen computed tomography demonstrated gallbladder lesion. A) Initial lesion size; B) lesion size after 6 months.

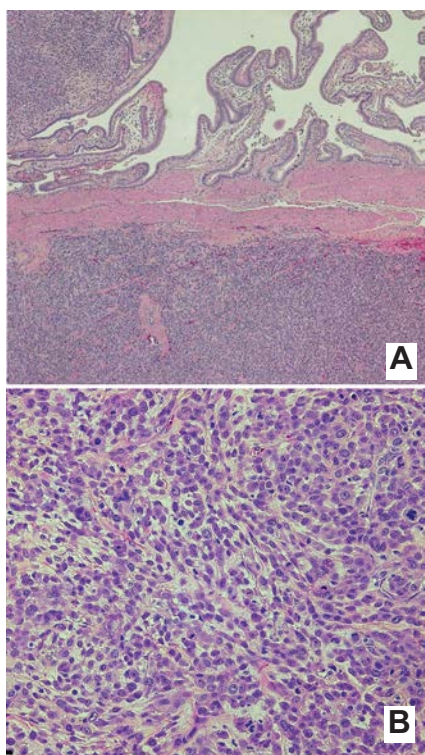


Figure 3. Pathology of gallbladder metastatic leiomyosarcoma. A) 4x; B) 20x.

ple pancreatic nodules, Fine needle aspiration biopsy confirmed metastatic disease. She underwent standard pancreaticoduodenectomy. The pathology from all surgical specimens demonstrated morphological and imaging features consistent with metastatic leiomyosarcoma. As she had persistent lung metastases she commenced gemcitabine and navelbine with a partial response. She had 8 cycles of this schedule. She then went on to surveillance and most recently has been on pazopanib with stable disease. With multi-modality therapy she has lived for over 10 years with metastatic uterine leiomyosarcoma.

Discussion

The common metastatic sites of uterine leiomyosarcoma include lung, liver, brain, and bone.³ Other rare metastatic sites have been reported including pancreas, skull, adrenal gland and heart, bile duct, bowel, breast, orbital and gingival.⁴⁻¹⁴ To the best of our knowledge, we are unaware of any other published reports of uterine leiomyosarcoma with gall bladder metastasis.

Uterine leiomyosarcoma generally disseminates via the blood stream, with the lungs being a common site of metastatic spread. However, the gallbladder does not have a rich blood supply, and it is a rare site for metastatic disease.¹⁵ Our patient had lived for many years with metastatic leiomyosarcoma prior to the identification of a metastasis in the gall bladder. Several cases of primary leiomyosarcoma of the gallbladder have been reported although this is not a common primary site.¹⁵⁻¹⁷

The prolonged survival of our patient with multimodality management, including systemic therapy, surgery and radiation, highlights the importance of managing patients with these rare tumors within a multi-disciplinary team. The median overall survival of

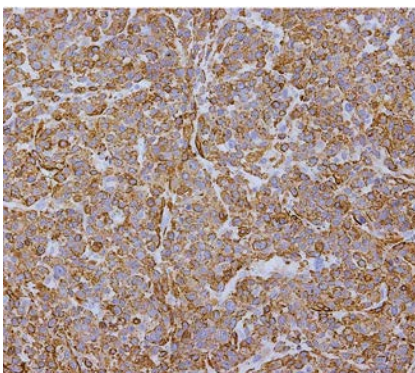


Figure 4. Immunohistochemistry for alpha-smooth muscle actin (IA4) antibody.

patients with metastatic soft tissue sarcoma is in the region of 12-16 months. However, it is clear that in some patients prolonged survival can be achieved with aggressive management and access to novel treatment approaches.¹⁸ Our case also highlights the importance of unusual patterns of metastatic spread in patients with leiomyosarcoma. Physicians need to be aware of such potential metastatic sites so that appropriate management can be initiated.

Conclusions

In conclusion, to our knowledge this is the first report of leiomyosarcoma uterine with metastatic disease in the gall bladder. This case also illustrates the importance of physicians being aware of unusual locations of metastasis and the applicability of multi-modality therapy in patients with metastatic soft tissue sarcoma.

References

1. Major FJ, Blessing JA, Silverberg SG, et al. Prognostic factors in early-stage uterine sarcoma. A Gynecologic Oncology Group study. *Cancer* 1993;71:1702-9.
2. Bathan AJ, Constantinidou A, Pollack SM, et al. Diagnosis, prognosis, and management of leiomyosarcoma: recognition of anatomic variants. *Curr Opin Oncol* 2013;25:384-9.
3. D'Angelo E, Prat J. Uterine sarcomas: a review. *Gynecol Oncol* 2010;116:131-9.
4. Lin CH, Yeh CN, Chen MF. Breast metastasis from uterine leiomyosarcoma: a case report. *Arch Gynecol Obstet* 2003;267:233-5.
5. Perysinakis I, Katopodi A, Avlonitis S, et al. Metastatic leiomyosarcoma of the intrapancreatic bile duct. *J Korean Surg Soc* 2013;84:66-9.
6. Tunio MA, Alasiri M, Saleh RM, et al. Obstructive small bowel metastasis from uterine leiomyosarcoma: a case report. *Case Rep Obstet Gynecol* 2014;2014:603097.
7. Ozturk S, Unver M, Ozturk BK, et al. Isolated metastasis of uterine leiomyosarcoma to the pancreas: Report of a case and review of the literature. *Int J Surg Case Rep* 2014;5:350-3.
8. Iwamoto I, Fujino T, Higashi Y, et al. Metastasis of uterine leiomyosarcoma to the pancreas. *J Obstet Gynaecol Res* 2005;31:531-4.
9. Sweeney JT, Crabtree DK, Yassin R, et al. Metastatic uterine leiomyosarcoma invol-

- ving the pancreas diagnosed by EUS with fine-needle aspiration. *Gastrointest Endosc* 2002;56:596-7.
10. Yip CM, Yang KC, Lo YS, et al. Skull metastasis from uterine leiomyosarcoma: a case report. *Acta Neurol Taiwan* 2006;15:109-13.
 11. Uchino M, Endo G, Shibata I, et al. Uterine leiomyosarcoma metastasis to the skull-case report. *Neurol Med Chir (Tokyo)* 1996;36:469-71.
 12. Yang ST, Liao YH, Lin WC, et al. Unusual metastasis of uterine leiomyosarcoma to the adrenal gland with intravenous extension to the heart. *J Obstet Gynaecol* 2014;34:206-7.
 13. Kim YH, Park IK, Min GE, et al. A case of orbital metastasis of uterine leiomyosarcoma with intracranial extension presenting with proptosis. *Ophthal Plast Reconstr Surg* 2016;32:e51-2.
 14. Cassoni A, Terenzi V, Bartoli D, et al. Metastatic uterine leiomyosarcoma in the upper buccal gingiva misdiagnosed as an epulis. *Case Rep Oncol Med* 2014;2014:402342.
 15. Savlania A, Behera A, Vaiphei K, et al. Primary leiomyosarcoma of gallbladder: a rare diagnosis. *Case Rep Gastrointest Med* 2012;2012:287012.
 16. Park EY, Seo HI, Yun SP, et al. Primary leiomyosarcoma of gallbladder. *J Korean Surg Soc* 2012;83:403-7.
 17. Al-Daraji WI, Makhlof HR, Miettinen M, et al. Primary gallbladder sarcoma: a clinicopathologic study of 15 cases, heterogeneous sarcomas with poor outcome, except pediatric botryoid rhabdomyosarcoma. *Am J Surg Pathol* 2009;33:826-34.
 18. Sleijfer S, Ray-Coquard I, Papai Z, et al. Pazopanib, a multikinase angiogenesis inhibitor, in patients with relapsed or refractory advanced soft tissue sarcoma: a phase II study from the European organisation for research and treatment of cancer-soft tissue and bone sarcoma group (EORTC study 62043). *J Clin Oncol* 2009;27:3126-32.