

# Laryngotracheal foreign body: chicken neck bone

Journal of International Medical Research

2019, Vol. 47(6) 2764–2767

© The Author(s) 2019


Article reuse guidelines:

[sagepub.com/journals-permissions](http://sagepub.com/journals-permissions)

DOI: 10.1177/0300060519848260

[journals.sagepub.com/home/imr](http://journals.sagepub.com/home/imr)



**Nicolae Constantin Balica** ,  
**Adrian Mihail Sitaru, Eugen Radu Boia,**  
**Delia Ioana Horhat, Ion Cristian Mot,**  
**Alexandru Chioreanu and Marioara Poenaru**

## Abstract

We herein present a case involving a 78-year-old patient who had aspirated a laryngotracheal foreign body 3 days prior to hospital admission. The patient had severe congenital intellectual disability; however, no agitation, suffocation, or death occurred despite almost complete laryngeal obstruction. The laryngotracheal foreign body was removed by tracheotomy and suspended microlaryngoscopy.

## Keywords

Laryngotracheal foreign body, intellectual disability, suspended microlaryngoscopy, tracheotomy, chicken bone, laryngeal obstruction

Date received: 4 November 2018; accepted: 12 April 2019

## Introduction

Laryngotracheal foreign body (LTFB) aspiration presents as an emergency, and unless diagnosed and treated promptly, a fatal outcome is almost inevitable.<sup>1</sup> The diagnosis of occult LTFB aspiration is complex.<sup>2</sup> The symptoms are related to the nature, size, location, and time of aspiration of the LTFB.<sup>3</sup> Although less common than bronchial foreign bodies, LTFBs are potentially dangerous.<sup>4,5</sup> Studies analyzing adult patients have shown that a normal

swallowing reflex protects against foreign body aspiration. Some types of central nervous system dysfunction may increase the risk of foreign body aspiration: stroke,

---

ENT Department, University of Medicine and Pharmacy,  
Timisoara, Romania

### Corresponding author:

Delia Ioana Horhat, ENT Department, University of  
Medicine and Pharmacy, Bd. Revolutiei No. 6, Timisoara,  
Timis 300054, Romania.

Email: [deliahorhat@yahoo.com](mailto:deliahorhat@yahoo.com)



loss of consciousness, metabolic encephalopathy, alcoholism, intellectual disability, neurological and/or psychiatric diseases, seizure disorders, consumption of central depressant drugs, inhibition of the pharyngeal or cough reflex, and other disorders.<sup>6-9</sup> Asphyxia may also develop in some patients.<sup>10-12</sup>

In the present case, a patient with severe congenital intellectual disability exhibited no signs or symptoms of LTFB aspiration. Computed tomography revealed almost complete laryngeal obstruction due to an inanimate LTFB (chicken neck bone).

Laryngeal spasm secondary to foreign body aspiration contributes to the development of asphyxia, and the effort of yelling or swallowing facilitates penetration of the foreign body into the larynx and trachea while the coughing reflex becomes inefficient.<sup>13</sup> This case is being reported because the findings could have a great impact on taking the patient's mental condition into consideration in the presence of severe laryngeal obstruction, helping to prevent progression to agitation, suffocation, and a fatal outcome.

## Case presentation

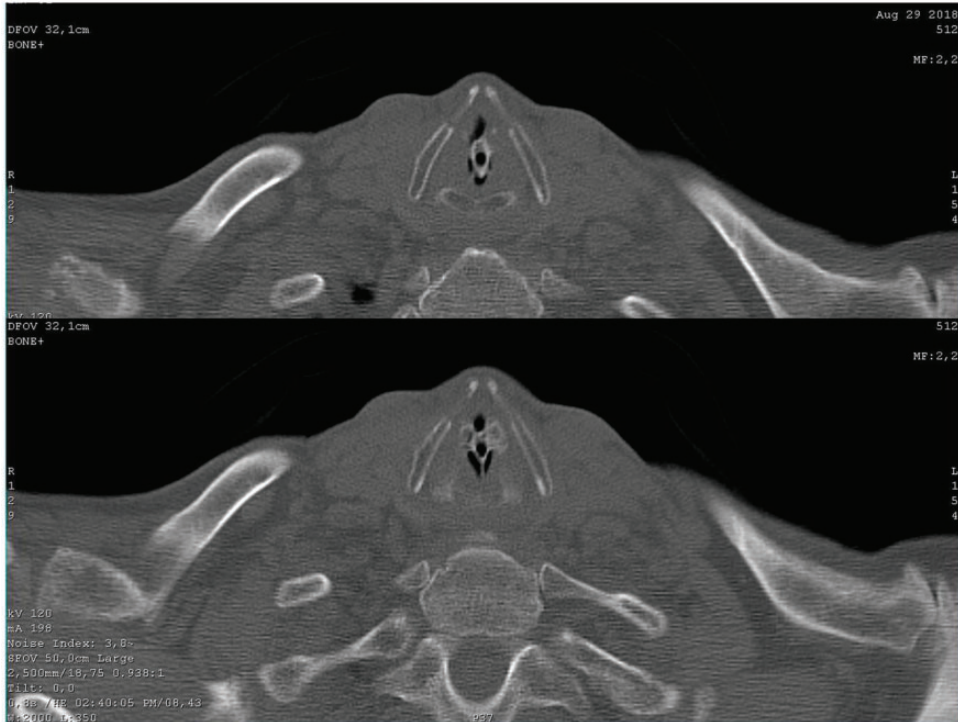
A 78-year-old man with severe congenital intellectual disability (intellectual developmental disorders according to the International Classification of Diseases, Eleventh Revision) presented to the intensive care unit of Timisoara Regional Hospital with possible LTFB aspiration. He did not exhibit the classic penetration syndrome. Clinical examination of the patient revealed mild dysphagia and drooling. Because the patient was unable to provide an accurate anamnesis, a head and neck computed tomography scan was performed (Figure 1) and revealed an LTFB (chicken neck bone). According to the patient's family, the aspiration had occurred 3 days before. No respiratory

signs or symptoms were present (e.g., stridor, intercostal and subcostal retractions, or nasal flaring), and the peripheral capillary oxygen saturation was >95%. We initiated an LTFB extraction procedure with local anesthesia (10% lidocaine), a 70° laryngeal video-endoscope, and laryngeal forceps. Unfortunately, the LTFB was impacted in the glottis, and the patient did not cooperate for the extraction maneuver. Because jet ventilation was not available, we decided to perform a tracheotomy. The LTFB was extracted by suspended microlaryngoscopy under general anesthesia with tracheal intubation (Figure 2). Two days after the surgical procedure, the tracheal tube was removed.

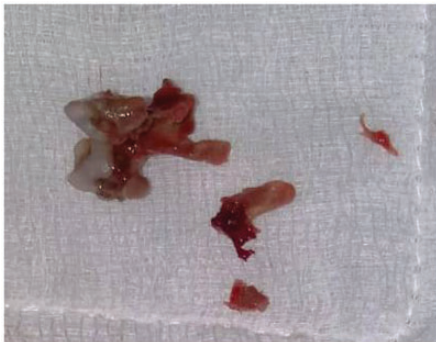This study was approved by the "Victor Babes" University of Medicine and Pharmacy Timisoara, Regional Hospital Timisoara, Romania (34/A/08.01.2018). We obtained verbal consent from the patient's caregiver.

## Discussion

Impaction of a foreign body in the larynx in patients of advanced age is a rare occurrence.<sup>14</sup> A search of PubMed for "laryngeal foreign body chicken" revealed only six articles, of which only three were related to penetration syndrome. In patients with LTFB aspiration involving complete obstruction, respiratory distress is followed by cardiac arrest. In patients with almost complete obstruction, severe respiratory distress develops with cyanosis or a peripheral capillary oxygen saturation of <90% accompanied by tachycardia and agitation or lethargy. Patients with severe obstruction exhibit stridor at rest and severe respiratory distress (severe intercostal and subcostal retractions, nasal flaring, substernal retractions, and severe tachypnea). In moderate and mild cases, the symptoms and signs are less severe and there are no signs indicating a risk of death. A large foreign body



**Figure 1.** Head and neck computed tomography scan.



**Figure 2.** Laryngotracheal foreign body (chicken neck bone).

occupying the laryngotracheal region without any symptoms is an even rarer occurrence.<sup>15</sup>

Careful clinical history-taking and physical examination are mandatory. Foreign bodies located in the laryngeal region are

almost always treated with surgery.<sup>16</sup> Endoscopic examination of the larynx, trachea, and lungs is used to extract the foreign bodies.<sup>17</sup> Early diagnosis and urgent removal of the foreign body are very important for reducing mortality. The physical characteristics, position, and location of the foreign body can influence the outcome, even in skilled hands.<sup>18</sup>

## Conclusions

LTFB aspiration is an emergency, and rapid identification of the LTFB will reduce morbidity and mortality. In patients with severe congenital mental disorders or only mild signs and symptoms, a high index of suspicion for LTFB is necessary. We believe that our patient's lack of agitation was due to his mental condition and might have evolved to suffocation and a fatal outcome.

## Declaration of conflicting interest

The authors declare that there is no conflict of interest.

## Funding

This research received no specific grant from any funding agency in the public, commercial, or not-for-profit sectors.

## ORCID iD

Nicolae Constantin Balica  <https://orcid.org/0000-0001-7755-4608>

## References

- Banerjee A, Rao KS, Khanna SK, et al. Laryngo-bronchial-bronchial foreign bodies in children. *J Laryngol Otol* 1988; 102: 1029–1032.
- Abdulmajid OA, Ebeid AM, Motaweh MM, et al. Aspirated foreign bodies in the trachea-bronchial tree. A report of 250 cases. *Thorax* 1976; 31: 635–640.
- Doust BD, Ting YM and Chuang VP. Detection of aspirated foreign bodies with Xeroradiography. *Radiology* 1974; 111: 725–727. DOI: 10.1148/111.3.725
- Boufersaoui A, Smati L, Benhalla KN, et al. Foreign body aspiration in children: experience from 2624 patients. *Int J Pediatr Otorhinolaryngol* 2013; 77: 1683–1688. DOI: 10.1016/j.ijporl.2013.07.026.
- Zavala DC and Rhodes ML. Foreign body removal: a new role for the fiberoptic bronchoscope. *Ann Otol Rhinol Laryngol* 1975; 84: 650–656. DOI: 10.1177/000348947508400516
- He B, Huang Y, Li Q, et al. Diagnosis of children with occult bronchial foreign body. *Zhonghua Er Ke Za Zhi* 2014; 52: 851–853.
- Berzlanovich MA, Fazeny-Dörner B, Waldhoer D, et al. Foreign body asphyxia. A preventable cause of death in elderly. *Am J Prev Med* 2005; 28: 65–69. DOI: 10.1016/j.amepre.2004.04.002
- Kent SE and Watson MG. Laryngeal foreign bodies. *J Laryngol Otol* 1990; 104: 131–133.
- Chrcanovic BR and Souza LN. Tracheotomy for a foreign body in the larynx. *Oral Maxillofac Surg* 2009; 13: 55–58. DOI: 10.1007/s10006-009-0148-6
- Ekberg O and Feinberg M. Clinical and demographic data in 75 patients with near-fatal choking episodes. *Disphagia* 1992; 7: 205–208.
- Dolkas L, Stanley C, Smith AM, et al. Deaths associated with choking in San Diego county. *J Forensic Sci* 2007; 52: 176–179. DOI: 10.1111/j.1556-4029.2006.00297.x
- Njau SN. Adult sudden death caused by aspiration of chewing gum. *Forensic Sci Int* 2004; 139: 103–106. DOI: 10.1016/j.forsciint.2003.09.021
- Arbarello P, Di Luca NM, Feola T, et al. *Medicina legale*. 2nd ed. Torino: Minerva Medica Ed., 2005, pp.343–345.
- Hada MS, Samdhani S, Chadha V, et al. Laryngeal foreign bodies among adults. *J Bronchology Interv Pulmonol* 2015; 22: 145–147. DOI: 10.1097/LBR.000000000000056
- Jain S, Kashikar S, Deshmukh PT, et al. Impacted laryngeal foreign body in a child: a diagnostic and therapeutic challenge. *Ann Med Health Sci Res* 2013; 3: 464–466. DOI: 10.4103/2141-9248.117937
- Türk B, Ünsal Ö, Kaya KS, et al. Dislocated dental prosthesis sitting at the larynx in an aphasic patient: potentially fatal situation. *J Craniofac Surg* 2017; 28: e655–e657. DOI: 10.1097/SCS.00000000000003795
- Timbo SK, Keita MA, Doumbia-Singare K, et al. Medical handicap and otorhinolaryngologic foreign bodies about 4 original cases. *Mali Med* 2010; 25: 50–55.
- Sazak H, Yazıcı U, Gülgösteren M, et al. Iatrogenic aspiration of a large piece of a wooden spoon in a 14-year-old epilepsy patient. *Ulus Travma Acil Cerrahi Derg* 2011; 17: 359–362.