

# Metachronous Intraductal Papillary Neoplasm of the Bile Duct and Intraductal Papillary Mucinous Neoplasm of the Pancreas in a Patient Diagnosed With Mucinous Adenocarcinoma

Gregory T. Brennan, MD<sup>1</sup>, and John G. Lee, MD<sup>1</sup>

<sup>1</sup>Division of Gastroenterology and Hepatology, University of California Irvine Health, Orange, CA

## ABSTRACT

Intraductal papillary neoplasm of the bile duct (IPNB) is a rare biliary tumor, which shares some radiologic and histologic similarities with pancreatic intraductal papillary mucinous neoplasm (IPMN). IPNB is a recognized precursor lesion of invasive adenocarcinoma. We present a case of metachronous IPNB and IPMN lesions in a patient with mucinous adenocarcinoma of the pancreas who presented with jaundice and abdominal pain. The patient was treated with surgery and adjuvant chemotherapy.

## INTRODUCTION

Pancreatic cysts such as intraductal papillary mucinous neoplasms (IPMNs) are often detected incidentally on abdominal imaging. Up to 38%–68% of IPMNs harbor high-grade dysplasia or pancreatic cancer.<sup>1</sup> Similarly, intraductal papillary neoplasm of the bile duct (IPNB) is a rare biliary tumor characterized by mucin-secreting papillary and/or cystic lesions of the bile ducts.<sup>2,3</sup> IPNBs were only recently distinguished as a separate pathologic entity by the World Health Organization in 2010.<sup>4</sup> As its name suggests, IPNBs share some radiologic and histologic similarities with pancreatic IPMNs.

## CASE REPORT

A 64-year-old white man with a history of main duct IPMN and remote prostate cancer status after prostatectomy presented to the emergency department with progressive generalized abdominal pain radiating to the back and jaundice for 2 weeks. This was associated with fatigue and 20 pounds of unintentional weight loss over the preceding 6 months.

Four years previously, the patient had an endoscopic ultrasound (EUS) for evaluation of an incidental finding on computed tomography (CT) showing pancreatic ductal dilation. EUS showed a 2.8-cm cystic lesion in the head of the pancreas in communication with the main pancreatic duct and upstream main pancreatic duct dilation measuring 3 mm in the body and 1.7 mm in the tail. There was a mucin plug at the pancreatic orifice seen endoscopically. The biliary tree was normal. He was diagnosed with main duct IPMN and was referred for surgical resection, which he declined. The patient was subsequently lost to follow-up until the present encounter 4 years later.

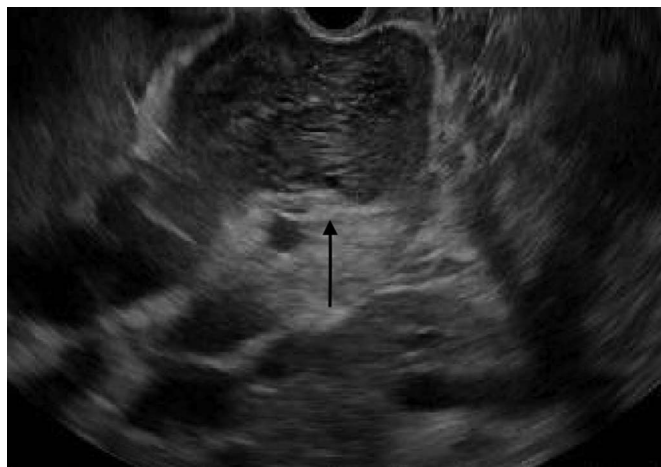The patient presented to the emergency department with normal vital signs. Examination was significant for jaundice, scleral icterus, and mild epigastric tenderness. Albumin was 2.5 g/dL, alkaline phosphatase 404 U/L, total bilirubin 20.5 mg/dL, alanine aminotransferase 131 U/L, aspartate aminotransferase 86 U/L, and normal lipase. Abdominal CT showed new severe intrahepatic and extrahepatic biliary ductal dilatation and marked increased dilatation of the pancreatic duct (measuring 4.2 cm at the head of the pancreas). There was expansion of the pancreatic head secondary to multiple dilated and tubular cystic foci, consistent with interval growth of the previous main duct IPMN.

EUS and endoscopic retrograde cholangiopancreatography were performed. EUS revealed massive extrahepatic biliary dilation up to the common hepatic duct (Figure 1). The pancreatic duct was massively dilated, consistent with previous main duct IPMN now with a new mural nodule seen in the main duct. Endoscopic retrograde cholangiopancreatography showed a gaping biliary orifice (“fish mouth”) filled with mucin, which was new compared with endoscopy 4 years earlier. The pancreatic orifice was covered by a polypoid nodule (Figure 2). Biopsies from both orifices were taken. The pancreatic orifice nodule pathology was intestinal-type papillary mucinous neoplasm with focal high-grade dysplasia. Immunohistochemistry from the biliary orifice was positive for MUC5AC and MUC2, consistent with intestinal-type IPNB (Figure 3). These findings were consistent with metachronous IPNB of the bile duct and IPMN of the pancreatic duct.

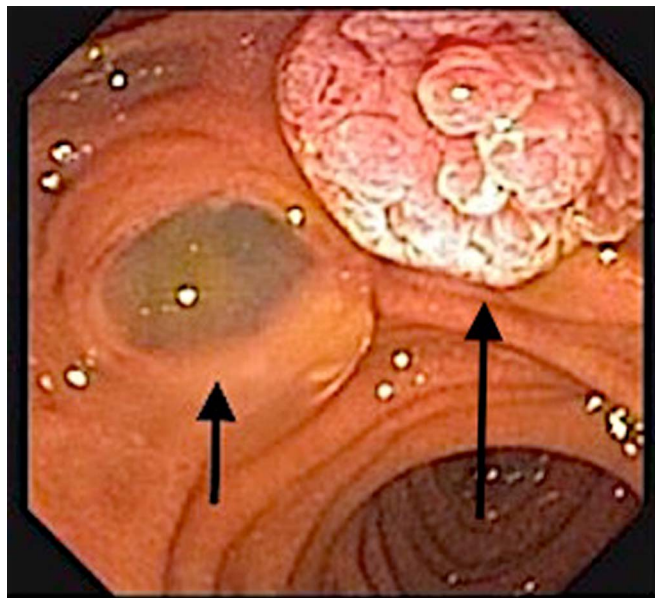
Evaluation for metastatic disease with pancreatic protocol abdominal and chest CT was negative, and the patient underwent attempted Whipple resection. Surgery showed a mixed cystic and solid pancreatic head mass 3 cm in size extending into the porta hepatis and involving the left hepatic artery. Frozen-section specimens from the head of the pancreas and an adjacent lymph node revealed mucinous adenocarcinoma of pancreatic origin. Palliative gastrojejunostomy and choledochojejunostomy were performed because of local invasion and concern that abundant mucin in the bile duct could cause obstructive jaundice and cholangitis. The patient recovered uneventfully and later received palliative chemotherapy with FOLFIRINOX.

## DISCUSSION

IPNB is a rare tumor characterized by intraductal papillary growth that can develop anywhere along the biliary tree. Mucin hypersecretion and biliary dilation can be seen. Clinically, IPNB can present in several ways including asymptomatic biliary dilation seen incidentally on cross-sectional imaging, elevated



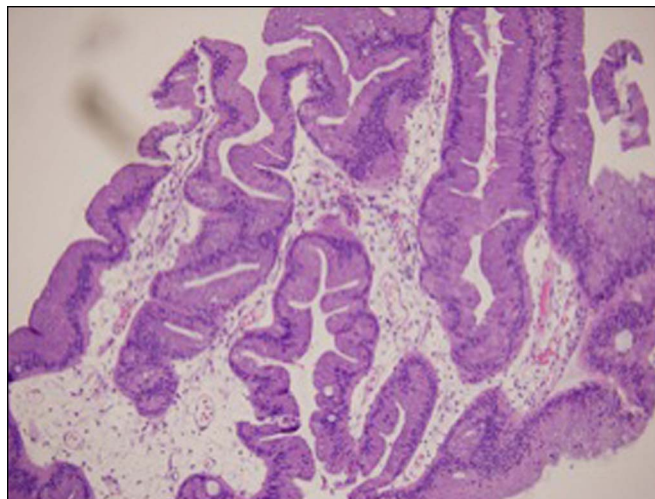
**Figure 1.** Endoscopic ultrasound image of a dilated common bile duct with mucin (arrow points to the dilated CBD with echogenic material representing intraductal mucin).



**Figure 2.** A patulous “fish mouth” ampulla with extruding mucin from the biliary orifice (small arrow) and an adjacent nodule at the pancreatic orifice (large arrow) seen on endoscopy.

liver chemistries, cholangitis or obstructive jaundice from tumor growth, or even mucin plugging. Microscopically, papillary fronds with vascular cores are seen. The pathogenesis is not entirely clear, but most studies come from Japan, China, Korea, and Taiwan involving Asian patients with associated hepatolithiasis and clonorchiasis.<sup>5</sup> Only approximately 11% of reported cases have come from the United States.<sup>5,6</sup> IPNB is most commonly seen in male patients between ages 50 and 70 years.<sup>7</sup>

IPNB has been considered similar to IPMN of the pancreas because of its intraductal papillary growth pattern and microscopic features such as mucin secretion.<sup>7,8</sup> Despite similarities, IPNBs and IPMNs are distinct diseases, and recently, these differences have been delineated. Some now divide IPNB lesions into 2



**Figure 3.** Microscopic findings of papillary mucinous neoplasm of the bile duct (hematoxylin and eosin stain, 100×).

subtypes based on histology, with type 1 being most similar to IPMN and type 2 having higher histopathological grade and more extensive stromal invasion than IPMN.<sup>11</sup> Mucin secretion is more common in IPMN lesions.<sup>8,11</sup> Both IPNB and IPMN lesions carry risk of progression to carcinoma.<sup>8</sup> All surgical candidates should undergo resection of IPNB lesions because of concern for higher risk of malignancy in IPNB compared with IPMN.<sup>8</sup> In most series, the risk of IPNB lesions containing carcinoma is >50%, but risk factors for malignant progression of IPNB are not well defined.<sup>8</sup> In the absence of consensus guidelines for IPNB, it may be reasonable to extrapolate guidelines of pancreatic cysts to determine higher-risk patients with IPNB requiring multidisciplinary care.

Our patient has some interesting findings worth discussion. The time course is important because he initially presented with a main duct IPMN and a normal biliary tree, which rules out a synchronous IPNB. Because the patient had separate biliary and pancreatic orifices, we felt that local invasion was unlikely in the absence of endoscopically visible contiguous spread.<sup>10</sup> The pathology from separate endoscopic biopsies of the orifices showed 2 distinct lesions. It is also unlikely that the IPNB was metastasized from the preexisting IPMN because of the separate orifices and the distinct pathology of the lesions. Therefore, he was diagnosed with metachronous IPMN and IPNB lesions. To our knowledge, there is 1 reported case of synchronous IPNB and IPMN lesions and no reported cases of metachronous lesions.<sup>9</sup> In summary, we present a case of metachronous IPNB and IPMN lesions in a patient with mucinous adenocarcinoma of the pancreas.

## DISCLOSURES

**Author contributions:** Both authors contributed equally to this manuscript. JG Lee is the article guarantor.

**Financial disclosure:** None to report.

Informed consent was obtained for this case report.

Received September 2, 2018; Accepted December 21, 2018

## REFERENCES

1. Elta G, Enestvedt B, Sauer B, Lennon A. ACG clinical guideline: Diagnosis and management of pancreatic cysts. *Am J Gastroenterol*. 2018;113:464–79.
2. Minagawa N, Sato N, Mori Y, Tamura A, Higure A, Yamaguchi K. A comparison between intraductal papillary neoplasms of the biliary tract (BT-IPMNs) and intraductal papillary mucinous neoplasms of the pancreas (P-IPMNs) reveals distinct clinical manifestations and outcomes. *EJSO*. 2013;39:554–8.
3. Rocha F, Lee H, Katabi N, et al. Intraductal papillary neoplasm of the bile duct: A biliary equivalent to intraductal papillary mucinous neoplasm of the pancreas? *Hepatology*. 2012;56:1352–60.
4. Bosman F, Carneiro F, Hruban R. *WHO Classification of Tumours of the Digestive System: World Health Organization Classification of Tumours*, 4th edn. Geneva, Switzerland: WHO Press, 2010.
5. Tan Y, Milikowski C, Toribio Y, Singer A, Rojas CP, Garcia-Buitrago MT. Intraductal papillary neoplasm of the bile ducts: A case report and literature review. *World J Gastroenterol*. 2015;43:12498–504.
6. Wang X, Cai Y, Chen Y, Liu X. Biliary tract intraductal papillary mucinous neoplasm: Report of 19 cases. *World J Gastroenterol*. 2015;14:4261–7.
7. Wan X, Xu Y, Qian J, et al. Intraductal papillary neoplasm of the bile duct. *World J Gastroenterol*. 2013;19:8595–604.
8. Ohtsuka M, Shimizu H, Kato A, et al. Intraductal papillary neoplasms of the bile duct. *Int J Hepatol*. 2014;2014:459091.
9. Fukumura Y, Nakanuma Y, Kakuda Y, Takase M, Yao T. Clinicopathological features of intraductal papillary neoplasms of the bile duct: A comparison with intraductal papillary mucinous neoplasm of the pancreas with reference to subtypes. *Virchows Arch*. 2017;471:65–76.
10. Suchy F. Anatomy, histology, embryology, developmental anomalies, and pediatric disorders of the biliary tract. In: Sleisenger M, Fordtran J, Feldman M, Brandt L, Friedman L (eds). *Sleisenger & Fordtran's Gastrointestinal and Liver Disease*, 10th edn. Philadelphia, PA: Saunders-Elsevier, 2016, pp 1058.
11. Moon D, Lee S, Jung D, et al. Synchronous malignant intraductal papillary mucinous neoplasms of the bile duct and pancreas requiring left hepatectomy and total pancreatectomy. *Korean J Gastroenterol*. 2013;2:129–33.

**Copyright:** © 2019 The Author(s). Published by Wolters Kluwer Health, Inc. on behalf of The American College of Gastroenterology. This is an open-access article distributed under the terms of the Creative Commons Attribution-Non Commercial-No Derivatives License 4.0 (CCBY-NC-ND), where it is permissible to download and share the work provided it is properly cited. The work cannot be changed in any way or used commercially without permission from the journal.