

Relationship between Clinical, MRI, and Arthroscopic Findings: A Guide to Correct Diagnosis of Meniscal Tears

P. Antinolfi¹ R. Crisitiani² F. Manfreda² S. Bruè³ V. Sarakatsianos⁴ G. Placella⁵ M. Bartoli⁵
A. Caraffa^{1,2}

¹Division of Orthopedics and Trauma Surgery, S. Maria della Misericordia Hospital, Perugia, Italy

²Department of Orthopedics and Traumatology, University of Perugia, Italy

³International Orthopedics and Traumatology Institute, Arezzo, Italy

⁴Capio Arthro Clinic/Stockholm Sports Trauma Research Center, Stockholm, Sweden

⁵Department of Orthopaedics, U. Cattolica del Sacro Cuore, Gemelli Hospital, Rome, Italy

Address for correspondence P. Antinolfi, MD, Orthopedic and Traumatology Department, Perugia University Hospital, via G. Dottori, Perugia 06100, Italy (e-mail: pantinolfi@gmail.com).

Joints 2017;5:164–167.

Abstract

Purpose The aim of this prospective study was to compare and correlate clinical, MRI, and arthroscopic findings in cases of suspected meniscal tears. Using arthroscopic findings as the gold standard, the sensitivity, specificity, accuracy, positive predictive value, and negative predictive value of clinical investigation and MRI were evaluated to determine if it is possible, after a careful examination, to bypass MRI and perform directly arthroscopy in suspected cases.

Methods A total of 80 patients with a history of knee trauma, preoperative RX, and MRI underwent arthroscopy over an 8-month period at our department. All patients had a clinical examination performed by an experienced knee surgeon. These examiners evaluated and recorded the results of three tests: medial and lateral joint line tenderness test, McMurray's test, and Apley's test. The injury was classified as a meniscal tear if there were at least two positive tests. Finally, using the arthroscopic findings as the gold standard, sensitivity, specificity, accuracy, positive and negative predictive values of clinical examination, and MRI were evaluated and compared.

Results Clinical examination performed by an experienced knee surgeon reported better sensitivity (91 vs. 85%), specificity (87 vs. 75%), accuracy (90 vs. 82%), positive predictive value (94 vs. 88%), and negative predictive value (81 vs. 71%) than MRI for medial meniscal tears. These parameters showed minimal differences for lateral meniscal tears.

Conclusion Clinical examination performed by an experienced knee surgeon provided equal or better results to diagnose meniscal injuries in comparison to MRI. MRI is not necessary to confirm these lesions and should not be used as the primary diagnostic tool.

Level of Evidence Level II, prospective study.

Keywords

- ▶ meniscus
- ▶ tears
- ▶ knee
- ▶ examination
- ▶ meniscal tears
- ▶ MRI

Introduction

The menisci are essential and play a fundamental role in the knee joint. These are responsible for lubrication, increase the contact area between femur and tibia, decrease the load bearing on the articular cartilage, and increase the stability of the knee.^{1,2}

Meniscus tears, seen in young and old patients, are an extremely common cause of knee pain.³ It is important to make an accurate diagnosis of meniscus tears so that the appropriate treatment can be given. A detailed history and physical examination can help to differentiate patients who have a meniscus tear from those whose knee pain arises from other conditions.^{4,5}

Magnetic resonance imaging (MRI) scanning is considered the gold standard noninvasive method to diagnose meniscal tears.^{6,7} It is routinely used to support the diagnosis of meniscal injuries prior to recommending arthroscopic examination and surgery. Furthermore, patient's history alone is inadequate as a diagnostic tool, and the diagnostic accuracy of clinical tests for meniscal tears has often been questioned. A review of the available literature reveals conflicting results regarding their usefulness.^{8,9}

Our objective was to evaluate and compare sensitivity, specificity, accuracy, positive predictive value (PPV) and negative predictive value (NPV) of clinical examination, and MRI in the diagnosis of meniscal tears, considering arthroscopic findings as the gold standard.

The hypothesis of the study was that there was no significant difference in diagnostic accuracy of MRI and clinical tests to diagnose a meniscal tear.

Methods

All patients with a history of knee injury, who attended our Orthopaedic department from August 2015 to April 2016 and underwent clinical exam, radiographic exam, MRI, and arthroscopy, were considered eligible to enter the study. Exclusion criteria were previous episodes of knee locking, both medial and lateral joint line tenderness, combined cruciate or collateral ligament injuries, degenerative changes, fractures, previous traumas, previous knee surgery, and additional injury to the knee between the time of MRI/clinical diagnosis and surgery.

All the patients were examined by an orthopaedic surgeon with more than 10 years of experience in the field of knee surgery. Patient's history was obtained prior to clinical examination. Clinical assessment was based on medial and lateral joint line tenderness, McMurray's and Apley's tests, and other specific tests to rule out other associated injuries to the knee.

Knee joint line tenderness was assessed with the patient supine and the knee flexed to 90 degrees on lateral and medial sides. McMurray's test was performed in a standard fashion by placing the knee beyond 90 degrees of flexion and then rotating the tibia on the femur into full internal rotation

to test the lateral meniscus, or full external rotation to test the medial meniscus. The same maneuvers were performed in gradually increasing degrees of knee flexion to progressively load more posterior segments of the menisci. Valgus and varus stress were applied. During the maneuver, the joint line is palpated both medially and laterally. Positive test was considered to be a click or pain along the joint line.¹⁰

Apley's test was performed with the patient prone on an examination table and the knee flexed to 90 degrees. The knee of the examiner was placed across the posterior aspect of the patient's thigh and the tibia compressed onto the knee joint while being externally and internally rotated. The test was considered positive if produced pain with external rotation test for medial involvement and internal rotation test for lateral involvement.

Meniscal injury was suspected when at least two of the three tests used were positive.

Meniscal injuries on MRI were scored according to the grading system described by Lotysch et al¹¹ and Crues et al.¹² Grade 3 signal intensity on MRI was defined as an abnormal signal in meniscus extending to the articular surface. Diagnosis of a tear should be made only when definitive findings of high-signal intensity are seen reaching the articular surface (►Fig. 1). A single abnormal image was considered sufficient for diagnosing a meniscus as torn on MRI. Grade 1 and 2 signal changes in meniscus not reaching the articular surface were not considered tears. MRI of the affected knee was performed on a 1.5 Tesla scanner (Magnetom Avanto; Siemens, Munich, Germany). The imaging protocol included sagittal T1, T2, GRE; coronal T2, PD; and axial T2 and GRE sequences. Fat suppression was obtained in all cases with T2 and PD sequences. Imaging parameters were field of view of 14 to 16 cm; 320 × 240 matrix sizes; slice thickness of 3.0 mm; and an intersection gap of 1 mm for both sagittal and coronal images. The MRI scans were reviewed by an expert musculoskeletal radiologist unaware of the findings of the orthopaedic clinical examination.

All patients underwent knee arthroscopy. All arthroscopies were performed by an orthopaedic surgeon with more than 10 years of experience in the field of knee arthroscopic surgery.

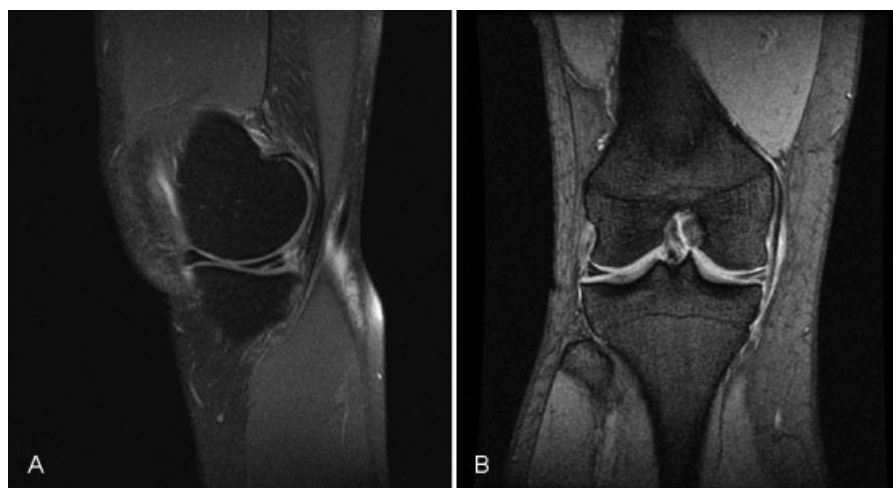


Fig. 1 Grade 3 signal hyperintensity in the medial meniscus. (A) T2 sagittal sequence. (B) T2 coronal sequence.

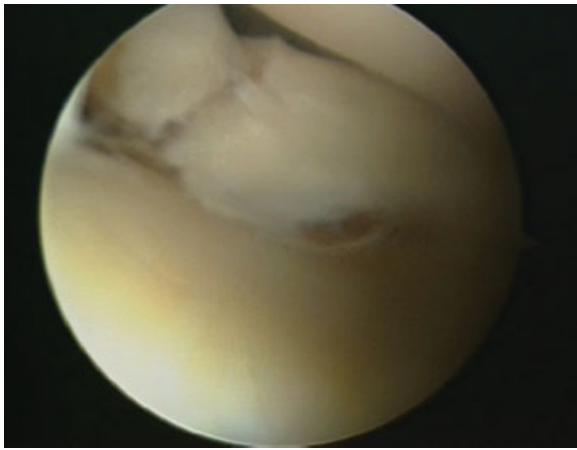


Fig. 2 Arthroscopic view of medial-lateral meniscal tear.

Standard anteromedial and anterolateral portals were used. The surgery was performed under loco-regional anesthesia. Examination of the knee under anesthesia was performed once again to check for any signs of instability. The interval between MRI and arthroscopy was from a minimum of 25 days to a maximum of 50 days (average time was 40 days). Record of clinical, MRI, and arthroscopic findings was kept and compared. Sensitivity, specificity, PPV, NPV, and accuracy of clinical examination findings and MRI were regarded considering arthroscopy as the gold standard (► **Fig. 2**).

Results

The study cohort consisted of 80 patients (48 males and 32 females) with age ranging from 17 to 49 years (mean age, 28.4 years).

There were 49 patients with suspected diagnosis of medial meniscal tear. Clinical diagnosis was confirmed at arthroscopy in 31 cases (true positives). Three patients were false negative (one positive clinical test with meniscal tear confirmed during arthroscopy), 2 were false positive (positive clinical examination with no meniscal tears at arthroscopy), and 13 patients were true negative. In the latter subgroup, we found medial patellar plica in six patients, cartilage injury on the medial femoral condyle in four, and no injuries in three patients.

MRI assessment exhibited 28 true positive, 5 false negative, 4 false positive, and 12 true negative patients.

Table 1 Diagnostic values of clinical examination and MRI for MM tears

	Clinical examination (%)	MRI (%)
Sensitivity	91	85
Specificity	87	75
Accuracy	90	82
PPV	94	88
NPV	81	71

Abbreviations: MM, medial meniscus; MRI, magnetic resonance imaging; NPV, negative predictive value; PPV, positive predictive value.

Table 2 Diagnostic values of clinical examination and MRI for LM tears

	Clinical examination (%)	MRI (%)
Sensitivity	86	85
Specificity	90	91
Accuracy	87	87
PPV	95	94
NPV	75	77

Abbreviations: LM, lateral meniscus; MRI, magnetic resonance imaging; NPV, negative predictive value; PPV, positive predictive value.

Clinical examination showed better sensitivity, specificity, accuracy, PPV, and NPV in comparison to MRI (► **Table 1**).

There were 31 patients with a suspected lateral meniscal tear; of these, clinical exam identified a true positive result in 18 patients. Three patients were false negative, one patient was false positive, and nine patients were true negative. In the latter subgroup, there were three patients with cartilage damage on the lateral femoral condyle, one patient with cartilage damage on the lateral tibial plateau, one patient with lateral patellar plica, and four patients with no intra-articular pathology.

MRI showed grade 3 tears in 17 patients in which the diagnosis was confirmed arthroscopically. There were 3 false negative, 1 false positive, and 10 true negative patients.

Between clinical examination diagnosis and MRI scan diagnosis for lateral meniscal injuries, there were only minimal differences regarding diagnostic values (► **Table 2**).

Discussion

Our objective was to evaluate and compare the diagnostic accuracy of clinical investigation and MRI to establish if it is possible to skip the MRI in cases of suspected meniscal tears. Moreover, the validity of clinical examination and MRI in predicting differences in medial and lateral meniscal injuries was also studied. Previous studies compared clinical examination and MRI scans with arthroscopy of the knee joint as the gold standard. Conflicting results emerge by the review of the literature. Mohan et al,⁴ in their retrospective series of 130 patients, showed that the diagnostic accuracy of clinical examination was 88% for medial meniscal tears and 92% for lateral meniscal tears; they concluded that clinical diagnosis of meniscal tears was as reliable as the MRI scan. Rose et al¹³ found better diagnostic accuracy with clinical exam than with MRI scans in a series of 100 patients. On the contrary, in a prospective series of 145 patients by Abdon et al,¹⁴ clinical examination had only 61% accuracy for meniscal tears. Rangger et al¹⁵ studied 121 patients with a meniscal tear. They concluded that MRI should be performed before arthroscopy of the knee in all cases in which the clinical diagnosis has been reduced to a suspected meniscus injury.¹⁵

Nevertheless, MRI is the main imaging modality of excellence for accurately depicting abnormalities of the menisci and is commonly used because various intra-articular

lesions historically had common symptoms.^{16–18} For this reason, MRI is considered by many orthopaedic surgeons a routine preoperative diagnostic tool to establish or confirm a diagnosis of meniscal tear. However, according to the results of our study, we believe that when a meniscal tear is suspected after a careful clinical examination performed by an experienced knee surgeon, MRI could be avoided as a routine diagnostic tool. If a patient had no clinical symptoms, even though MRI showed meniscal tears, knee arthroscopy was unnecessary.¹³ In many cases, relying on MRI alone without using clinical judgment might have led to inappropriate treatment. In any case, MRI did not prevent “unnecessary surgery.”¹⁹

MRI systems used in this study had 1.5 Tesla field strength considered appropriate for producing diagnostic images of high quality. Magee et al established that MRI of the knee performed at 3.0 Tesla compared favorably in sensitivity and specificity with studies performed at 1.5 Tesla or lower field strength scanners.²⁰ However, their study did not directly compare different field strengths in the same study population. More recently, as suggested by Van Dyck et al,²¹ the use of a 3.0 Tesla MRI did not significantly improve accuracy for evaluating the knee menisci compared with similar 1.5-Tesla protocol.²¹ Therefore, further studies may be needed to determine the true diagnostic performance of different field strength scanners.

The results of our study matched the sensitivity, specificity, and accuracy of clinical examination and MRI for detection of meniscal injuries reported in earlier studies.^{13,22,23}

This study had several limitations. First, sample size was small and no power analysis was provided. Second, the average time between MRI and arthroscopy was almost 6 weeks that could have allowed some meniscus lesion to heal, thus producing false positive MRI. Third, there was a bias because only patients referred for MRI were included in the study. Inherent verification bias affected all patients, as they all had undergone MRI before arthroscopy that probably influenced the decision to perform arthroscopy.

In conclusion, a well-trained qualified surgeon can safely rely on clinical examination for diagnosing meniscal injuries. Clinical examination is at least as accurate as MRI in the hands of a skilled orthopaedic surgeon. When clinical diagnosis is in favor of a meniscal tear, performing an MRI scan prior to arthroscopic examination is unnecessary. MRI should not be used as primary diagnostic tool in meniscal injuries. This expensive imaging modality should be used only for more doubtful, difficult, and complex knee injuries.

References

- Aagaard H, Verdonk R. Function of the normal meniscus and consequences of meniscal resection. *Scand J Med Sci Sports* 1999; 9(03):134–140
- Fox AJ, Wanivenhaus F, Burge AJ, Warren RF, Rodeo SA. The human meniscus: a review of anatomy, function, injury, and advances in treatment. *Clin Anat* 2015;28(02):269–287
- Terry GC, Tagert BE, Young MJ. Reliability of the clinical assessment in predicting the cause of internal derangements of the knee. *Arthroscopy* 1995;11(05):568–576
- Mohan BR, Gosal HS. Reliability of clinical diagnosis in meniscal tears. *Int Orthop* 2007;31(01):57–60
- Nickinson R, Darrah C, Donell S. Accuracy of clinical diagnosis in patients undergoing knee arthroscopy. *Int Orthop* 2010;34(01):39–44
- Crawford R, Walley G, Bridgman S, Maffulli N. Magnetic resonance imaging versus arthroscopy in the diagnosis of knee pathology, concentrating on meniscal lesions and ACL tears: a systematic review. *Br Med Bull* 2007;84(01):5–23
- Rubin DA, Paletta GA Jr. Current concepts and controversies in meniscal imaging. *Magn Reson Imaging Clin N Am* 2000;8(02):243–270
- Esmaili Jah AA, Keyhani S, Zarei R, Moghaddam AK. Accuracy of MRI in comparison with clinical and arthroscopic findings in ligamentous and meniscal injuries of the knee. *Acta Orthop Belg* 2005;71(02):189–196
- Scholten RJ, Devillé WL, Opstelten W, Bijl D, van der Plas CG, Bouter LM. The accuracy of physical diagnostic tests for assessing meniscal lesions of the knee: a meta-analysis. *J Fam Pract* 2001; 50(11):938–944
- Hing W, White S, Reid D, Marshall R. Validity of the McMurray's Test and modified versions of the test: a systematic literature review. *J Manual Manip Ther* 2009;17(01):22–35
- Lotysch M, Mink J, Crues JV, Schwartz SA. Magnetic resonance imaging in the detection of meniscal injuries. *Magn Reson Imaging* 1986;4:185
- Cruces JV III, Mink J, Levy TL, Lotysch M, Stoller DW. Meniscal tears of the knee: accuracy of MR imaging. *Radiology* 1987;164(02):445–448
- Rose NE, Gold SM. A comparison of accuracy between clinical examination and magnetic resonance imaging in the diagnosis of meniscal and anterior cruciate ligament tears. *Arthroscopy* 1996; 12(04):398–405
- Abdon P, Lindstrand A, Thorngren KG. Statistical evaluation of the diagnostic criteria for meniscal tears. *Int Orthop* 1990;14(04):341–345
- Rangger C, Klestil T, Kathrein A, Inderster A, Hamid L. Influence of magnetic resonance imaging on indications for arthroscopy of the knee. *Clin Orthop Relat Res* 1996;(330):133–142
- Morrison WB, Sanders TG. *Imaging of the knee. Problem Solving in Musculoskeletal Imaging*. Mosby Elsevier Inc. 2008:567–568
- Englund M, Niu J, Guermazi A, et al. Effect of meniscal damage on the development of frequent knee pain, aching, or stiffness. *Arthritis Rheum* 2007;56(12):4048–4054
- Link TM, Steinbach LS, Ghosh S, et al. Osteoarthritis: MR imaging findings in different stages of disease and correlation with clinical findings. *Radiology* 2003;226(02):373–381
- Miller GK. A prospective study comparing the accuracy of the clinical diagnosis of meniscus tear with magnetic resonance imaging and its effect on clinical outcome. *Arthroscopy* 1996;12(04):406–413
- Magee T, Williams D. 3.0-T MRI of meniscal tears. *Am J Roentgenol* 2006;187(02):371–375
- Van Dyck P, Vanhoenacker FM, Lambrecht V, et al. Prospective comparison of 1.5 and 3.0-T MRI for evaluating the knee menisci and ACL. *J Bone Joint Surg Am* 2013;95(10):916–924
- Ercin E, Kaya I, Sungur I, Demirbas E, Ugras AA, Cetinus EM. History, clinical findings, magnetic resonance imaging, and arthroscopic correlation in meniscal lesions. *Knee Surg Sports Traumatol Arthrosc* 2012;20(05):851–856
- Kocabay Y, Tetik O, Isbell WM, Atay OA, Johnson DL. The value of clinical examination versus magnetic resonance imaging in the diagnosis of meniscal tears and anterior cruciate ligament rupture. *Arthroscopy* 2004;20(07):696–700