



What Ages Hair?☆

Assaf Monselise, MD^{a,d,*}, David E. Cohen, MD, MPH^b, Rita Wanser^c, Jerry Shapiro, MD^{a,b}

^a Department of Dermatology and Skin Science, University of British Columbia, BC, Canada

^b The Ronald O. Perleman Department of Dermatology, New York University School of Medicine, NY, USA

^c Cicatricial Alopecia Research Foundation, Chairman of the Board, IL, USA

^d Private practice, Tel Aviv, Israel



Background

Hair has always played an important role in the history of mankind. Egyptian hieroglyphics are testimony of the paramount importance of hair for this ancient civilization, not only because of the visual effect, but also because of the erotic symbolism connected with hair. For the ancient Romans hair was not only a question of fashion but was used as a symbol of beauty, virility, class and intellect. In modern western culture having a full head of hair is often associated with desirable qualities such as youthfulness and vitality. Most people experience changes in hair and scalp health as they age. Subsequent hair loss may cause significant distress that deeply affects people's life causing social anxiety and interfering with their well being. Genetic and hormonal changes are important factors in hair loss, but weathering and grooming habits take a toll on our hair as well.

A recent advisory board comprising twelve experts in hair fibers and hair loss was formed to review hair loss in relation to heredity, aging and environmental factors emphasizing measures that may slow alopecia. The following information is a summary of their discussions on these topics.

Definition of a healthy scalp and hair

Although healthy scalp and hair are of prime importance, the general public is not knowledgeable about these issues. Most people have little awareness about how to appropriately care for their hair and scalp. Healthy hair and healthy scalp typically complement each other, so a healthy scalp is needed to give the appearance of healthy hair and vice versa. A healthy scalp is generally defined by a lack of disease or abnormalities; however a person could be bald and perceived as having a healthy scalp.

Experts in the field of dermatology (Rogaine® Scientific Roundtable, 2009) agree that the characteristics of healthy hair include thickness, volume, luster and resilience of the fiber. The majority have agreed that a healthy scalp would have normal follicular density with no scaling, itching, burning or erythema.

Many patients experiencing hair loss assume the problem is related to the scalp if inflammation or flaking is present at the time of hair loss.

They believe that treatment of the scalp would promote future hair growth, although this is frequently not the case.

Chronic scalp inflammation likely diminishes hair health via a variety of mechanisms that are not fully understood. Although research on the effects of chronic scalp inflammation on hair health is limited, a plausible mechanism involves cytokine-driven decrease in the anagen phase hair lengthening as well as miniaturization of the hair follicle. The ideal environment required for a healthy growth of hair still has to be identified, yet changes in the environment surrounding the follicle like sebum excretion, debris, and chronic inflammation could significantly impact the growth and health of hair. On the other hand, treatments targeted at reducing inflammatory scalp conditions, such as dandruff and infection are harsh on the hair shaft and decrease shine and manageability.

Pattern Hair Loss or Age-related thinning

Pattern hair loss (PHL) has a multi-genetic background with half the male population affected by the age of 50 years. Different patterns for hair loss have been identified, including the Norwood-Hamilton pattern (Figure 1), the Ludwig pattern (Figure 2) and the Christmas tree or frontal accentuation pattern (Figure 3) Although the Norwood-Hamilton is traditionally used to describe PHL in men and the Ludwig and Christmas tree pattern for women, the different patterns are not gender restricted and can be used interchangeably. According to available data 38% of women over the age of 50 experience significant hair thinning (Rogaine® Scientific Roundtable, 2009). Women often regard hair loss a problem related to men exclusively and do not recognize this problem until significant hair loss has occurred, thus delaying treatment with minoxidil.

In men, hormonal factors, namely dihydrotestosterone (DHT) levels, play an important factor in the pathophysiology of PHL, with increased 5-alpha-reductase and androgen receptors in the frontal scalp compared to the occiput (Price, 2003). High scalp DHT levels are associated with follicular miniaturization which is characteristic for PHL (Whiting, 2001), however follicular downsizing has been described for senescent alopecia as well (Table 1) (Hordinsky et al., 2002). The pathophysiology of follicular downsizing is not fully understood. It is described as an alteration of the anagen (growth) and telogen (resting) phases of hair growth with a diminished scalp vasculature as an adjustment for the needs of the decrease in size follicles. In fact, the telogen phase during which hair is shed changes as a person ages. In a child, the number of hairs that are shed during this phase is much less compared with an average adult, who typically loses 100 hairs each day. As a person

☆ This article is a reprint of a previously published article. For citation purposes, please use the original publication details; International Journal of Women's Dermatology 1 (2015) 161-166. DOI of original item: 10.1016/j.ijwd.2015.07.004.

* Corresponding Author.

E-mail address: a.mons@yahoo.com (A. Monselise).

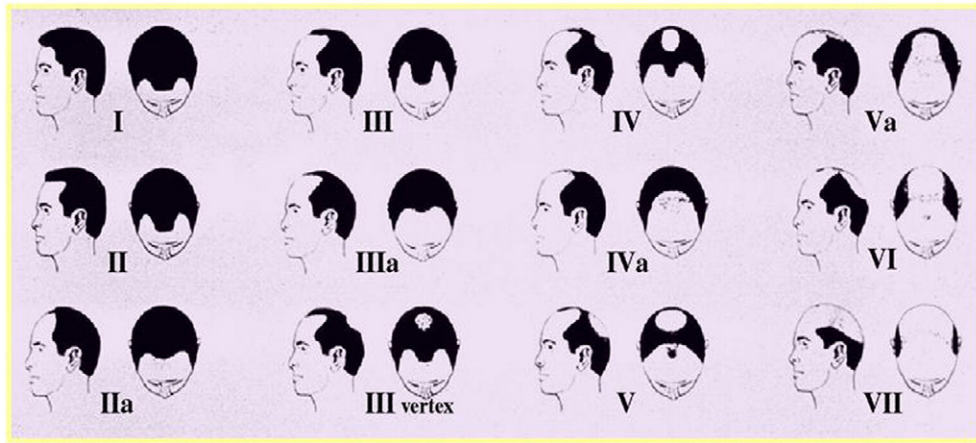


Figure 1. Androgenetic Alopecia in Males. Hamilton-Norwood Classification.

continues to age, the number of hairs that are shed increases, resulting in thinning, which is common in the senior population. Conversely, the anagen phase of hair growth is likely influenced by age and race and appears to shorten as a person ages, however it is unclear when or what triggers a shortening of this phase. Additionally, people from some ethnic backgrounds, such as African American women, appear to be more susceptible to shortening of the anagen phase, as they often experience difficulty in growing and maintaining long hair as they get older.

A direct relationship appears to exist between the degree of scalp inflammation and pattern hair loss especially in men (Jaworsky et al., 1992), and treating this inflammation can reduce the loss of hair. In this regard, minoxidil may exert anti-inflammatory/immunomodulatory effects in the follicle environment (Fiedler and Buys, 1987, 1988). In contrast, research in the area of female PHL suggests that sebum excretion is unchanged in these patients (Birch et al., 2006). Most women with PHL have normal serum androgen levels, suggesting genetic and environmental factors are likely playing a role in alopecia.

Some people experience widespread thinning of their hair as they get older. This condition is defined as senescent alopecia or age-related thinning, and is characterized by a scalp-wide reduction in the number of hairs rather than classic pattern hair loss. Senescent alopecia typically occurs between the ages of 50 and 80 years in a person without a prior history of hair thinning and any underlying scalp diseases, and can be superimposed on PHL. Indeed the distinction between age-related thinning and PHL is confusing since the presence of follicular miniaturization in age-related hair loss is an inconsistent finding. The relation between senescent hair loss and androgens has yet to be determined. A drop in estrogen levels that occur during menopause could

contribute to hair thinning, which is commonly seen in older women. Some areas of the scalp could be dependent on androgens for either hair growth and/or hair loss, and this may explain, for example, the association of Hamilton PHL, which is typical for men, in some women with age-related hair loss. If low androgen plays a major role in senescent alopecia, Estratest® (esterified estrogens combined with methyltestosterone) would be the hormone replacement of choice in women. This drug could also be combined with finasteride in women with low dihydrotestosterone (DHT) levels. However, administration of Estratest and dehydroepiandrosterone (DHEA) supplements has been associated with hair loss in clinical practice, so determining the appropriate dose and product for androgen replacement could be challenging. The ideal androgen level for hair growth must be balanced with the negative effects of androgen administration, such as hirsutism, acne, and osteoporosis. Since minoxidil's stimulatory effect impacts many areas of the scalp, it would indeed help manage senescence and hair loss related to aging alopecia.

Weathering & Grooming

Weathering is defined as the cumulative effect of environmental factors on the physicochemical structure of the hair. Hair damage induced by environmental factors including UV, humidity, wind and chemicals in hair products and procedures, has a negative impact on the growth and texture of the hair fiber. Grooming habits and weathering interplay in the process of hair wearing and both can compound the natural decrease in hair density related to age-related thinning/PHL. Typically in Caucasians and Asians, when the inciting factor is weathering, the

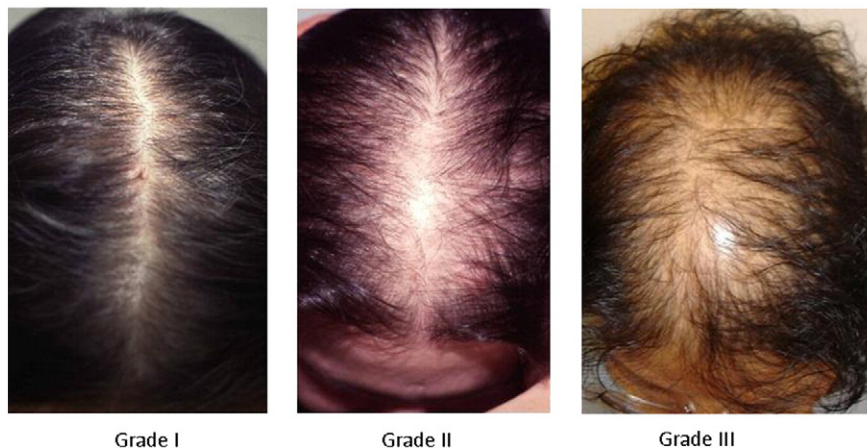

Figure 2. Androgenetic Alopecia in Women. Ludwig Classification.

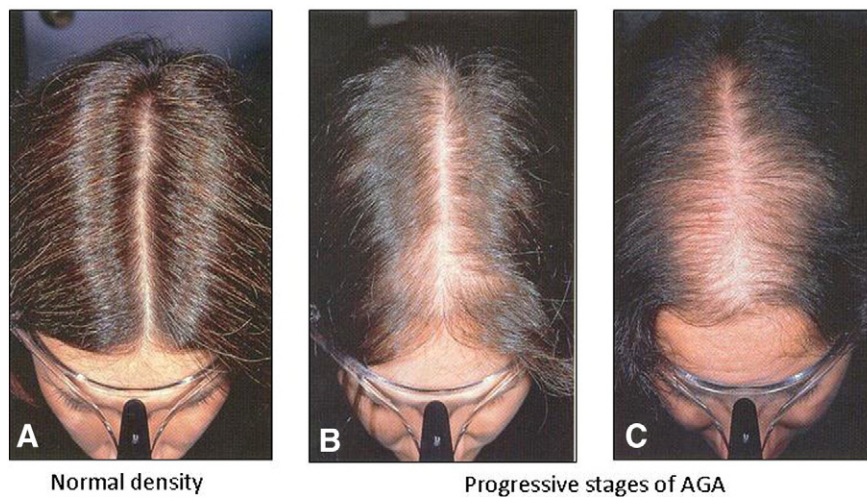


Figure 3. Androgenetic Alopecia (AGA) in Women-Frontal Accentuation (Christmas Tree Pattern).

damage occurs distally on the hair shaft. However, damage to the shaft frequently occurs proximally in African Americans, caused by the harsh chemicals applied on the scalp to relax the hair. The resilience of the hair shaft to weathering is determined by its unique structure. Much of the fiber's strength is given by the cortex and overlying cuticle that serves as a mechanical protective barrier. The latter constitutes about 10% of the fiber's weight and is made of tiny scales that overlap one another like shingles on a roof, with their exposed edges towards the tip of the fiber. The cortex provides strength thanks to keratin which is rich in disulfide bonds. Additionally, melanin which resides in the cortex provides protection to the fiber against UV radiation. The pathogenesis of photo damage involves interaction between iron, water, and UV light with the formation of free radicals. The latter are partially absorbed by melanin which acts as a scavenger of free radicals. However, when an overwhelming amount of free radicals is formed, melanin is degraded and UV light then generates crosslinks between proteins, melting the cortex and making the hair very brittle. Red headed and blond people are more prone to photo-damage since their hair is rich in pheomelanin which is less resistant than eumelanin. Likewise white or graying hair is less protected from UV radiation

The frictional properties of the cuticle determine how the hair feels to touch, how it combs and styles. When the cuticular scales are smooth light is reflected and the hair appears shiny and healthy. Typically, the macroscopic appearance of a damaged fiber is characterized by splitting of the ends, so called *trichoptilosis*. This happens mostly for longer fibers that have been exposed for longer periods to environmental factors. Observation of the hair by scanning electron microscopy reveals progressive damage to the fiber from root to tip, with slight scale lifting proximally and gradual chipping and denudation of the cuticle, with longitudinal fissures and transverse breakage or *trichoschisis* near *trichorrhexis nodosa* like nodes.

Grooming habits have an important impact on the wearing of the hair fiber. Shampooing daily cleanses off the protective layer of sebum that covers the hair, causing the shaft to dry out so it easily gets statically charged and consequentially more prone to friction. Shampoos are

amphiphilic molecules that have both a lipophilic side that binds sebum and a hydrophilic part that binds water. They are divided into groups based on their chemical structure. Those belonging to the anionic group contain negatively charged molecules with stronger and deeper cleansing properties, such as sodium laureth sulfate and sodium lauryl sulfate. Sodium lauryl sulfate was used almost exclusively in shampoos several years ago and is more irritating and damaging to the follicle compared to sodium laureth sulfate. Currently, the majority of shampoos contain sodium laureth sulfate due to its moisturizing properties (Rogaine®Scientific Roundtable, 2009). Shampoos categorized in other chemical groups (cationic, non ionic and amphoteric) include products that have milder cleansing properties, are less irritating and leave the hair more manageable. Shampoos are often marketed based on the type of hair that they are meant for. Those for oily hair have stronger detergent properties while those for permed, permanently dyed, bleached or dry hair, are milder in order to reduce sebum removal. Baby shampoos are usually mild, less irritating and are suitable for daily use.

Permanent waving or relaxing of hair involves chemicals like ammonium thioglycollate, sodium hydroxide and guanidine hydroxide, which are extremely alkaline and cause breakage of disulphide cross-links within the keratin, inducing swelling and softening of the fiber. Reduced cysteine levels in relaxed hair is consistent with hair fragility in comparison to normal unrelaxed hair Khumalo et al., nd. The damaged fiber characteristically breaks along the shaft, leaving the root unaffected and is more often seen on the nape area which is first treated by the stylist and is thereby exposed to the product for longer time. Bleaching products contain hydrogen peroxide or hydrogen persulfate. These chemicals must traverse the cuticle in order to bleach the melanin which lays in the cortex, causing irreversible oxidation of keratin disulfide bonds with weakening the fiber.

Combing and brushing, especially when done tip to root on wet hair can be harsh on the fiber with the development of *trichoschisis*. Wet combing applies force on the hair close to the scalp, making it more damaging than dry combing in which the force is placed on the end of the hair shaft (Rogaine®Scientific Roundtable, 2009). Using wide-toothed combs and brushes with rounded tips is a good protective measure when styling the hair. (Table 2)

In African Americans, straightened hair behaves similar to Caucasian hair, so it is less difficult to comb when it is dry compared with non-straightened hair. The application of oil to African American hair prior to shampooing would lubricate the hair shaft, making hair more manageable, easier to comb, and less susceptible to damage by the shampooing and drying process. Oils may also have antifungal properties, which could ward off scalp infections. However, triglycerides in

Table 1
Defining the characteristics of Senescent Alopecia

Scalp-wide reduction in the number of hairs
Occurs between the ages of 50 and 80 years
No prior history of hair thinning or underlying scalp disease
Presence of follicular miniaturization is inconsistent
Shortening of anagen
Decreased anagen/telogen ratio
<i>Relation to androgens has yet to be determined.(low androgen levels could be a factor)</i>

Table 2

Good grooming habits

Shampoo daily with mild shampoo which is less irritating to the shaft
Apply shampoo to soaked hair with fingertips and rub gently
Avoid frequent perming
Avoid frequent application of permanent dyes
Avoid frequent bleaching
Comb hair root to tip when dry
Use wide-toothed combs and brushes with rounded tips
Avoid frequent use of hair dryers

these oils could be cleaved to free fatty acids that produce inflammation in the hair follicle (Rogaine®Scientific Roundtable, 2009).

Using hair dryers and curling irons can “cook” the hair fiber. Observation with a magnifier reveals the classic picture of *Bubble Hair* (Mirmirani, 2008) (Figure 4) that is given by micro cavities within the shaft, which are formed by the expansion of moisture induced by the high temperatures of these devices. Japanese or ionic hair straightening with ceramic irons that reach temperatures as high as 210°C has been related to widespread breakage of the hair shaft as a result of acquired trichorrhexis nodosa (Mirmirani, 2010). Temporary disruption of hydrogen bonds in the cortex involved in this procedure, imparts the desirable softness to the hair. Interestingly, trichorrhexis nodosa is observed where the cuticle is lost and the cortex has been damaged.

Current Treatment Concepts

Minoxidil

Minoxidil was the first FDA approved medication for male-pattern baldness and has been on the market for more than 20 years. Increased scalp blood flow resulting from local vasodilation has been proposed as a possible mechanism of minoxidil's effect on hair growth however, this mechanism has not been substantiated consistently and not all vasodilators produce hypertrichosis. Because minoxidil has stimulated hair regrowth in several forms of alopecia, different speculations regarding its mechanism of action have been forwarded. These include immunomodulation (Fiedler and Buys, 1987, 1988), targeting specific follicular potassium channels (Davies et al., 2005) or induction of PGE2 synthesis in the dermal papilla fibroblasts (Michelet et al., 1997).

Traditionally, topical minoxidil has shown to be efficacious for male pattern hair loss (MPHL) involving the vertex, with an increase of 30% in hair weight at 96 weeks of treatment compared to placebo (Price et al., 1999). However, significant clinical data has demonstrated minoxidil's



Figure 4. Bubble Hair-Deformed hair shafts due to heat exposure caused by dryers and curling irons.

efficacy for frontal hair loss as well, which is consistent with histologic (Whiting et al., 1999) and photographic evidence suggesting that follicles in the vertex and frontal scalp have the same morphology. Indeed it may take up to one year of treatment before significant changes in hair growth are detectable by consumers. Minoxidil solution has a high safety profile (Shapiro, 2003) with scalp irritation occurring in 7% of patients which has been related to the vehicle (propylene glycol) or minoxidil (Friedman et al., 2002). Minoxidil 5% foam is propylene glycol free and is therefore recommended for patients who are suspected to be sensitive to the vehicle. In the clinical trial of Minoxidil 5% foam (MTF) a decrease in the incidence of irritation was observed on both the foam vehicle and 5% MTF. Furthermore, the incidence of pruritus with 5% MTF was 1.1% vs 6% seen in a separate trial of 5% Minoxidil topical solution (Olsen et al., 2007).

Many dermatologists recommend Minoxidil for age-related thinning as this process involves a decrease in both hair density and the diameter of the hair follicle (Ebling, 1988), which are successfully treated by minoxidil in PHL.

Non approved hair regrowth treatments

A plethora of products for hair loss is available on the market, some of which are easily accessible through different web sites and others are sold in salons (Table 3). Slogans and claims are provided to the public of healthy hair seekers indicating the beneficial effects of these products as solid evidence for promoting hair growth. Hence people may be provided with questionable information regarding their hair problem and treatment options. Products for hair loss are sold as shampoos, solutions, cleansers, foams conditioners, and leave – in agents. An array of natural and non-natural occurring ingredients is mixed into these products (i.e. vitamins, adenosine, retinoic acid, herbal extracts, minoxidil, ketoconazole, copper peptide, amino acids) as remedies for hair loss. It is unknown whether some of these hair products may indeed have beneficial effects on the follicles. Only Rogaine® (containing minoxidil) has established evidence based science to substantiate proven efficacy.

Combinations of minoxidil and retinoic acid probably enhance the penetration of the former but are unlikely beneficial due to the neutralizing effect of the latter on minoxidil. Products that contain both of these components are definitely not recommended by most hair experts due to potential irritation and unproven efficacy. Furthermore, application of enhancing products in combination with minoxidil should be separated by at least 2 hours to permit the absorption of minoxidil into the epidermis and prevent its potential deactivation. The concept of “opening hair follicles” was developed as a marketing strategy for some hair care products with allegedly enhanced hair growth capabilities. However hair follicles are not necessarily closed therefore it is unclear what are the benefits of such products. Nanosome technology has been used to enhance the penetration of some hair products into the epidermis, but whether it is of benefit for growing

Table 3
Treatments

<i>Efficacy proven by clinical trials:</i>
Minoxidil 5% solution (or minoxidil 5% foam if allergy occurs with the solution)
Finasteride (Propecia®) 1mg Tab Once daily (for MPHL)Price et al., 2006
Dutasteride (Avodart®) 2.5mg Tab Once daily (for FPHL)
Dutasteride (Avodart®) 0.5mg Tab Once daily (for MPHL) Stough, 2007; Eun et al., nd; Olsen et al., 2006
<i>Non approved products with limited clinical data :</i>
Finasteride 2.5mg Tab Once daily (for FPHL) Iorizzo et al., 2006
Hair products with Ketoconazole
Hair products with copper peptide
Hair products combining minoxidil and retinoic acid
Hair products with various vitamins, adenosine and herbal extracts
Estratest +/- finasteride (for senescent hair loss)

hair is questionable (Rogaine®Scientific Roundtable, 2009). Claims regarding acceleration of metabolism in the follicle or surrounding circulation by topically applied vitamins and herbal extracts, as well as their nourishing effects on the hair follicle and scalp by direct application are unknown. Many patients take mega doses of vitamins, which could cause more harm than benefit. Indeed, consumption of Vitamin A at doses higher than 5000IU per day may be a risk factor for hair loss.

Hair Fiber Protection

Limited data supports that replacement of amino acids via a shampoo increases the tensile of the hair fiber, however this benefit remains unproven (Rogaine®Scientific Roundtable, 2009). Hair products with sun-screens are useful as they provide protection to the scalp and hair from UV radiation and slow the weathering process. When sun-screens are compounded as leave-in conditioners this can provide moisture to the fiber and improve the manageability of the hair. DHT likely exists on the scalp surface as a component of sebum. It has been suggested that removal of DHT with cleansing products containing ketoconazole can improve hair growth. Literature suggests that ketoconazole has anti-DHT properties, and not only improves seborrhea but also androgenetic thinning (Pierard-Franchimont et al., 1998; Inui and Itami, 2007). While the anti-DHT properties has not been proven to help pattern hair loss, nevertheless the association of ketoconazole may contribute to a healthier scalp. Copper peptide is compounded in some hair products and scientific evidence suggests its beneficial effects on hair growth through stimulation of human dermal papilla cells (Pyo et al., 2007), and as a potent activator of both telogen and anagen follicles in mice (Trachy et al., 1991).

Discussion

Overcoming the denial of hair loss and encouraging people to seek medical attention earlier rather than later would be valuable in the overall management of hair thinning/hair loss. When evident alopecia has ensued, at least 50% of the scalp hair has already been lost. Certain patient populations are more prone to aging and thinning of their hair, particularly those who practice certain grooming procedures, whose hair is graying or fair colored and are inadvertently exposed to weathering factors. Most people do not realize that UV exposure has negative effects not only on the skin but on the hair as well, especially when it is devoid of melanin.

Confusion exists around the definition of senescent alopecia (Kligman, 1988; Ebling, 1988). In-office measurement of age-related changes in hair density is problematic since an efficient instrument or rating scale has not been identified to measure and monitor diffuse thinning of the hair. The scales used for alopecia, such as the SALT (severity of alopecia tool) score, are not highly applicable to the situation of senescent thinning. Establishing a "norm" volume of hair for a patient would be important, as the differences of hair shafts prevents comparisons between patients. Furthermore, normal hair density should be defined for each age bracket, so the severity of hair loss could be determined. Scalp biopsies with horizontal follicular counts are the gold standard for confirming a reduction in hair number (Whiting, 1993) but are problematic in everyday practice. Weathering and grooming habits pose a significant problem in aging patients. Differences between declines in hair quality due to weathering versus aging should be clearly characterized to help guide treatment in these two situations. Grey or chemically/physically treated hair is drier and more easily weathered, so conditioning is necessary to reinforce the cuticular sheath and protect it from damage. A distinction should be made between scalp care and care of the hair shaft and proper education of the public should be instituted. The former requires regular cleaning to remove debris and build-up that can negatively impact hair growth. Before shampooing, untangling the hair is important and emphasis should be directed at lathering the scalp rather than the hair

shaft in order to remove debris and build-up that can negatively impact hair growth. The hair fiber is adequately cleaned as the shampoo is rinsed off the scalp and out of the hair (Rogaine®Scientific Roundtable, 2009). The frequency of shampooing should be tailored according to the oiliness of the scalp, as very oily scalps require daily shampooing. Some experts advocate applying oil to the hair prior to shampooing as a protective measure. The oil would lubricate the hair, making it more manageable and easier to comb. In addition, the oil contains triglycerides that are converted in the scalp epidermis to monoglycerides and diglycerides, which have antifungal properties. However, some of the triglycerides could be cleaved to free fatty acids that have a pro-inflammatory effect on the hair follicle (Rogaine®Scientific Roundtable, 2009). Drying the hair should be done gently by patting with a towel, rather than wrapping the hair. Combing done slowly when the hair has dried out using a wide-tooth comb with rounded tips will eliminate unnecessary tension and breakage of the hair. African American patients compared to Caucasians and Asians, pose a particular challenge for treatment of hair loss having unique hair density, texture, scalp conditions, and styling techniques that could influence treatment response. Additionally, African American women are more susceptible to age-related thinning. This patient population, infrequently shampoo their hair hence promoting the buildup of products on the scalp which may negatively affect hair growth. Shampooing the scalp more frequently could help eliminate unwanted debris but would also wash out the sebum and enhance dryness and irritation. Layering of conditioning products may reduce hair breakage and dryness but on the other hand impair the absorption of hair growth promoting agents like minoxidil. Additionally, Minoxidil may aggravate scalp and hair dryness in these patients making compliance and adherence with treatment difficult. Application of Minoxidil foam over several days could produce a slight scalp residue, which does not affect its efficacy therefore avoiding the need of shampooing daily. Furthermore, this residue could actually have a moisturizing effect since the Minoxidil foam contains long-chain fatty acids found in conditioners. Rogaine®Scientific Roundtable, 2009 Other measures that could improve utilization of minoxidil and compliance of these patients would be an over-the-counter shampoo containing a low-level steroid that targets the mild inflammation and irritation of the scalp associated with minoxidil. A combination of a mild shampoo and conditioner that is rinsed out followed by a leave-in conditioner that is applied while the hair is still wet could help as well. Indeed daily application of conditioners to dry hair between shampoos would not interfere with minoxidil (Rogaine®Scientific Roundtable, 2009). The prevalence and pathophysiology behind follicular miniaturization in senescent alopecia merits further investigation to better understand the potential benefits of minoxidil for this type of hair loss. Identifying the threshold of hair thinning at which minoxidil would be beneficial for senescent alopecia is important. Minoxidil has proven efficacy for AGA in men with frontal (Olsen, 1999). The public should be educated about grooming habits and weathering factors that may aggravate AGA or senescent hair loss. Recommendations for UV protection with a hat or by application of a sunscreen product specific for the hair should be reinforced.

Conclusions

The advisors agreed that aging of hair is an inevitable process that is determined by an interplay of many factors including weathering, grooming habits, UV exposure, hair color, androgenetic alopecia and other age-related thinning. Choice of hair care products is important to the overall health of scalp and hair. Currently, there is no evidence based data to suggest that hair care products are efficacious for more than healthier hair fibers. Further study should be done to determine if use of these products can provide healthier scalp conditions, slow the PHL process, due to androgenetic alopecia and/or age-related thinning. Minoxidil foam and solution has proven efficacy for AGA and

advisors agreed that their clinical evidence suggests this is a useful treatment option for age-related thinning as well.

References

- Birch MP, Lashen H, Agarwal S, Messenger AG. Female pattern hair loss, sebum excretion and the end-organ response to androgens. *Br J Dermatol* 2006;154:85–9.
- Davies GC, Thornton MJ, Jenner TJ, et al. Novel and established potassium channel openers stimulate hair growth in vitro: implications for their modes of action in hair follicles. *J Invest Dermatol* 2005;124:686–94.
- Ebling FJ. The hair cycle and its regulation. *Clin Dermatol* 1988;6:67–73.
- Eun HC, Kwon OS, Yeon JH, et al. Efficacy, safety, and tolerability of dutasteride 0.5 mg once daily in male patients with male pattern hair loss: a randomized, double-blind, placebo-controlled, phase III study. *J Am Acad Dermatol*;63:252–8.
- Fiedler VC, Buys CM. Immunohistochemical characterization of the cellular infiltrate in severe alopecia areata before and after minoxidil treatment. *Dermatologica* 1987;175(Suppl. 2):29–35.
- Fiedler VC, Buys CM. Direct T-cell effects of minoxidil. *Clin Dermatol* 1988;6:148–51.
- Friedman ES, Friedman PM, Cohen DE, Washenik K. Allergic contact dermatitis to topical minoxidil solution: etiology and treatment. *J Am Acad Dermatol* 2002;46:309–12.
- Hordinsky M, Sawaya M, Roberts JL. Hair loss and hirsutism in the elderly. *Clin Geriatr Med* 2002;18:121–33 vii.
- Inui S, Itami S. Reversal of androgenetic alopecia by topical ketoconazole: relevance of anti-androgenic activity. *J Dermatol Sci* 2007;45:66–8.
- Iorizzo M, Vincenzi C, Voudouris S, Piraccini BM, Tosti A. Finasteride treatment of female pattern hair loss. *Arch Dermatol* 2006;142:298–302.
- Jaworsky C, Kligman AM, Murphy GF. Characterization of inflammatory infiltrates in male pattern alopecia: implications for pathogenesis. *Br J Dermatol* 1992;127:239–46.
- Khumalo NP, Stone J, Gumedze F, McGrath E, Ngwanya MR, de Berker D. 'Relaxers' damage hair: evidence from amino acid analysis. *J Am Acad Dermatol*;62:402–8.
- Kligman AM. The comparative histopathology of male-pattern baldness and senescent baldness. *Clin Dermatol* 1988;6:108–18.
- Michelet JF, Commo S, Billoni N, Mahe YF, Bernard BA. Activation of cytoprotective prostaglandin synthase-1 by minoxidil as a possible explanation for its hair growth-stimulating effect. *J Invest Dermatol* 1997;108:205–9.
- Mirmirani P. What is your diagnosis? Bubble hair. *Cutis* 2008;82:176–84.
- Mirmirani P. Ceramic flat irons: improper use leading to acquired trichorrhhexis nodosa. *J Am Acad Dermatol* 2010;62:145–7.
- Olsen EA. The midline part: an important physical clue to the clinical diagnosis of androgenetic alopecia in women. *J Am Acad Dermatol* 1999;40:106–9.
- Olsen EA, Hordinsky M, Whiting D, et al. The importance of dual 5alpha-reductase inhibition in the treatment of male pattern hair loss: results of a randomized placebo-controlled study of dutasteride versus finasteride. *J Am Acad Dermatol* 2006;55:1014–23.
- Olsen EA, Whiting D, Bergfeld W, et al. A multicenter, randomized, placebo-controlled, double-blind clinical trial of a novel formulation of 5% minoxidil topical foam versus placebo in the treatment of androgenetic alopecia in men. *J Am Acad Dermatol* 2007;57:767–74.
- Pierard-Franchimont C, De Doncker P, Cauwenbergh G, Pierard GE. Ketoconazole shampoo: effect of long-term use in androgenic alopecia. *Dermatology* 1998;196:474–7.
- Price VH. Androgenetic alopecia in women. *J Invest Dermatol Symp Proc* 2003;8:24–7.
- Price VH, Menefee E, Strauss PC. Changes in hair weight and hair count in men with androgenetic alopecia, after application of 5% and 2% topical minoxidil, placebo, or no treatment. *J Am Acad Dermatol* 1999;41:717–21.
- Price VH, Menefee E, Sanchez M, Kaufman KD. Changes in hair weight in men with androgenetic alopecia after treatment with finasteride (1 mg daily): three- and 4-year results. *J Am Acad Dermatol* 2006;55:71–4.
- Pyo HK, Yoo HG, Won CH, et al. The effect of tripeptide-copper complex on human hair growth in vitro. *Arch Pharm Res* 2007;30:834–9.
- Rogaine®Scientific Roundtable. Short Hills NJ. April, 2009.
- Shapiro J. Safety of topical minoxidil solution: a one-year, prospective, observational study. *J Cutan Med Surg* 2003;7:322–9.
- Stough D. Dutasteride improves male pattern hair loss in a randomized study in identical twins. *J Cosmet Dermatol* 2007;6:9–13.
- Trachy RE, Fors TD, Pickart L, Uno H. The hair follicle-stimulating properties of peptide copper complexes. Results in C3H mice. *Ann N Y Acad Sci* 1991;642:468–9.
- Whiting DA. Diagnostic and predictive value of horizontal sections of scalp biopsy specimens in male pattern androgenetic alopecia. *J Am Acad Dermatol* 1993;28:755–63.
- Whiting DA. Possible mechanisms of miniaturization during androgenetic alopecia or pattern hair loss. *J Am Acad Dermatol* 2001;45:S81–6.
- Whiting DA, Waldstreicher J, Sanchez M, Kaufman KD. Measuring reversal of hair miniaturization in androgenetic alopecia by follicular counts in horizontal sections of serial scalp biopsies: results of finasteride 1 mg treatment of men and postmenopausal women. *J Invest Dermatol Symp Proc* 1999;4:282–4.