

Favipiravir-Induced Drug Fever in a Young Adult COVID-19 Patient

Dhigishaba M. Jadeja¹, Nirmal R. Patel²

1. Internal Medicine, Gujarat Adani Institute of Medical Sciences, Bhuj, IND 2. Internal Medicine, Gujarat Cancer Society Medical College, Ahmedabad, IND

Corresponding author: Dhigishaba M. Jadeja, dhigishabajadeja@gmail.com

Abstract

Severe acute respiratory syndrome coronavirus 2 has had an indelible effect, with 153,738,171 cases recorded globally as per the World Health Organization's dashboard. The medical establishment is racing to find repurposed medications that can be successful against this novel coronavirus due to a shortage of new drugs to treat the disease. Favipiravir, an antiviral drug originally developed for influenza, is one of the drugs that has recently received a lot of attention, particularly in India. Here, we present a case of favipiravir-induced drug fever in a young adult coronavirus disease 2019 patient.

Categories: Internal Medicine

Keywords: favipiravir, fever, covid-19

Introduction

As of February 23, 2021, the novel causative virus, the severe acute respiratory syndrome coronavirus 2 (SARS-CoV-2), has affected 13,060,542 people and caused 167,642 deaths, with a case fatality rate of 1.28% in India, which was 1.60% on September 22, 2020 [1]. Coronavirus disease 2019 (COVID-19) has induced a negative effect on social, economic, and psychological well-being in addition to causing physical discomfort [2]. Hypercytokinemia, which usually appears in the second week of COVID-19 and is associated with immunodeficiency as well as hyperinflammation, also known as a cytokine storm, is a feature of SARS-CoV-2 [3]. COVID-19 was previously believed to be a pulmonary illness, but studies have shown that it also affects other tissues in the body [4-6]. Furthermore, several studies have been reported in the literature regarding the symptomatic reinfection or extrapulmonary complication in previously recovered COVID-19 patients [7,8]. Owing to a lack of new medicines to combat the disease, the medical community is racing to identify repurposed antivirals that may be effective against this novel coronavirus. Remdesivir may be a novel antiviral therapy, but its effectiveness is unknown. Favipiravir, an antiviral drug originally developed for influenza, is one of the drugs that has recently received a lot of consideration, particularly in India. However, there is a scarcity of information on adverse reactions and limited sources are available on favipiravir-induced drug fever. Drug fever is difficult to diagnose in such a disease that presents with fever, especially if the drug is a new treatment for an evolving infectious disease like COVID-19. Here, we present a case of favipiravir-induced drug fever in a young adult COVID-19 patient.

Case Presentation

A 27-year-old male presented to the COVID care clinic with the complaint of fever, weakness, backache, headache, and dry cough. The patient's past medical history was unremarkable.

The patient began experiencing weakness on February 24th, 2021. On the third day of illness, with the emergence of backache, headache, and dry cough, he came to the COVID care center. His vital signs on presentation showed blood pressure of 121/89 mmHg, heart rate of 84 beats per minute, a temperature of 37.8°C, respiratory rate of 18 breaths per minute, and arterial oxygen saturation of 97% (room air). His physical examination was unremarkable, but the patient was lethargic. He tested positive for SARS-CoV-2 by reverse transcriptase-polymerase chain reaction (RT-PCR) from a nasopharyngeal swab. Laboratory data showed normal white blood cell counts, reduced lymphocytes, lactate dehydrogenase (LDH) of 230 U/L (reference range: 135-225 U/L), and C-reactive protein (CRP) of 24 mg/L. His D-dimer level was within the reference range.

On the fourth day of positive RT-PCR for SARS-CoV-2, he was started on favipiravir (1,800 mg twice on the first day followed by 600 mg thereafter), azithromycin 500 mg, and other supportive therapy, including a multivitamin. His clinical condition including fever and other symptoms improved on the sixth day of clinical illness. He remained afebrile until the 10th day of clinical illness. Then, he developed a fever of 38.2°C, thought to be caused by bacterial pneumonia or favipiravir-induced drug fever. Laboratory findings on the 11th day of illness showed normal complete blood count, CRP, LDH, interleukin-6, and procalcitonin. Repeated blood and urinary cultures revealed no evidence of a new infectious source. The chest X-ray was unremarkable. Hence, we diagnosed favipiravir-induced drug fever. The patient's fever eventually decreased after discontinuing favipiravir, and there was no worsening of symptoms. His fever was

Review began 04/15/2021

Review ended 05/05/2021

Published 05/09/2021

© Copyright 2021

Jadeja et al. This is an open access article distributed under the terms of the Creative Commons Attribution License CC-BY 4.0., which permits unrestricted use, distribution, and reproduction in any medium, provided the original author and source are credited.

How to cite this article

Jadeja D M, Patel N R (May 09, 2021) Favipiravir-Induced Drug Fever in a Young Adult COVID-19 Patient. Cureus 13(5): e14928. DOI 10.7759/cureus.14928

relieved without antimicrobial treatment and he was discharged on the following day (Figure 1).

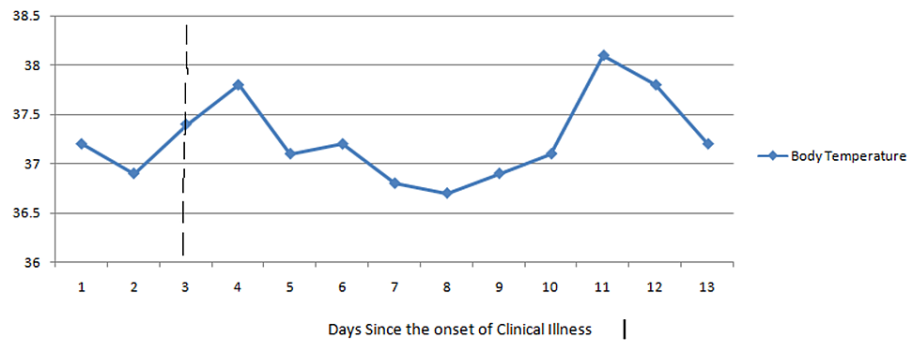


FIGURE 1: Timeline of favipiravir administration and body temperature.

Scattered line represents the clinical illness on the day of favipiravir administration.

Discussion

Favipiravir inhibits RNA polymerase, which is responsible for gene replication in RNA virus cells, and thereby prevents viral replication [9]. In vitro, favipiravir has moderate antiviral activity against SARS-CoV-2, an RNA virus, and is predicted to be a COVID-19 therapeutic agent [10]. Elevated blood uric acid levels are a common favipiravir side effect; however, levels rapidly return to normal after the drug is stopped, and most studies found few hyperuricemia symptoms [11]. Cases of drug fever caused by favipiravir, such as the one described here, are also rare. Drug fever is characterized as a fever that occurs with the administration of a drug and disappears after the drug is stopped where no other source can be found after a thorough physical examination and adequate laboratory tests [12]. Patients usually experience fever several days after taking the causative drug, and it goes down within 48-72 hours after stopping the drug [13,14]. In the present case, there was no other possible source of pyrexia observed other than favipiravir. If pyretolysis is not confirmed within 72 hours of stopping the medication, the diagnosis of drug fever may be ruled out [15]. In patients with COVID-19, treated with favipiravir, fever developed after hospital admission on day 11, according to a previous study [16]. In addition, secondary infection is common in COVID-19 patients [12]. Furthermore, as there is an increasing trend of telemedicine during the pandemic [17], it is important to diagnose such drug fever as early as possible when the patient is in self-isolation. These results indicate that determining the therapeutic progress in COVID-19 requires assessing a new-onset fever during therapy. The risk of favipiravir-induced fever should be kept in mind to prevent excessive antiviral or antimicrobial therapy.

Conclusions

Fever is an adverse effect of favipiravir, and a drug fever should be considered if a fever occurs during favipiravir therapy in COVID-19 patients. This preliminary report could aid in the diagnosis of fever in COVID-19 patients taking favipiravir. Early accurate diagnosis can not only eliminate ineffective, potentially dangerous, and costly diagnostic and therapeutic treatments but may also prevent excessive hospital isolation and bed occupancy, as well as save healthcare workers' time and effort.

Additional Information

Disclosures

Human subjects: Consent was obtained or waived by all participants in this study. **Conflicts of interest:** In compliance with the ICMJE uniform disclosure form, all authors declare the following: **Payment/services info:** All authors have declared that no financial support was received from any organization for the submitted work. **Financial relationships:** All authors have declared that they have no financial relationships at present or within the previous three years with any organizations that might have an interest in the submitted work. **Other relationships:** All authors have declared that there are no other relationships or activities that could appear to have influenced the submitted work.

References

1. Ansari AZ, Desai HD, Sharma K, Jadeja DM, Patel R, Patel Y, Desai HM: Prevalence and cross states comparison of case fatality rate and recovery rate of COVID 19/SARS-COV-2 in India. *J Family Med Prim Care*. 2021, 10:475-80. [10.4103/jfmprc.jfmprc_1088_20](https://doi.org/10.4103/jfmprc.jfmprc_1088_20)
2. Desai HD, Sharma K, Jadeja DM, Desai HM, Moliya P: COVID-19 pandemic induced stress cardiomyopathy: a literature review. *Int J Cardiol Heart Vasc*. 2020, 31:100628. [10.1016/j.ijcha.2020.100628](https://doi.org/10.1016/j.ijcha.2020.100628)
3. Desai HD, Sharma K, Parikh A, et al.: Predictors of mortality amongst tocilizumab administered COVID-19

- Asian Indians: a predictive study from a tertiary care centre. *Cureus*. 2021, 13:e13116. [10.7759/cureus.13116](https://doi.org/10.7759/cureus.13116)
4. Desai HD, Jadeja DM, Sharma K: Takotsubo syndrome a rare entity in patients with COVID-19: an updated review of case-reports and case-series. *Int J Cardiol Heart Vasc*. 2020, 29:100604. [10.1016/j.ijcha.2020.100604](https://doi.org/10.1016/j.ijcha.2020.100604)
 5. Singhavi R, Sharma K, Desai HD, Patel R, Jadeja D: A case of hemolytic anemia with acute myocarditis and cardiogenic shock: a rare presentation of COVID-19. *Cureus*. 2020, 12:e10657. [10.7759/cureus.10657](https://doi.org/10.7759/cureus.10657)
 6. Sharma K, Desai HD, Patoliya JV, Jadeja DM, Gadhya D: Takotsubo syndrome a rare entity in COVID-19: a systemic review-focus on biomarkers, imaging, treatment, and outcome. *SN Compr Clin Med*. 2021, 3:62-72. [10.1007/s42399-021-00743-4](https://doi.org/10.1007/s42399-021-00743-4)
 7. Desai HD, Sharma K, Patoliya JV, Ahadov E, Patel NN: A rare case of varicella-zoster virus reactivation following recovery from COVID-19. *Cureus*. 2021, 13:e12423. [10.7759/cureus.12423](https://doi.org/10.7759/cureus.12423)
 8. Vora T, Vora P, Vora F, Sharma K, Desai HD: Symptomatic reinfection with COVID-19: a first from western India. *J Family Med Prim Care*. 2021, 10:1496-8. [10.4103/jfmprc.jfmprc_2002_20](https://doi.org/10.4103/jfmprc.jfmprc_2002_20)
 9. Shannon A, Selisko B, Le N, et al.: Favipiravir strikes the SARS-CoV-2 at its Achilles heel, the RNA polymerase. *bioRxiv*. 2020, [10.1101/2020.05.15.098731](https://doi.org/10.1101/2020.05.15.098731)
 10. Dauby N, Van Praet S, Vanhomwegen C, Veliziotis I, Konopnicki D, Roman A: Tolerability of favipiravir therapy in critically ill patients with COVID-19: a report of four cases. *J Med Virol*. 2021, 93:689-91. [10.1002/jmv.26488](https://doi.org/10.1002/jmv.26488)
 11. Mishima E, Anzai N, Miyazaki M, Abe T: Uric acid elevation by favipiravir, an antiviral drug. *Tohoku J Exp Med*. 2020, 251:87-90. [10.1620/tjem.251.87](https://doi.org/10.1620/tjem.251.87)
 12. Mackowiak PA, LeMaistre CF: Drug fever: a critical appraisal of conventional concepts. An analysis of 51 episodes in two Dallas hospitals and 97 episodes reported in the English literature. *Ann Intern Med*. 1987, 106:728-33. [10.7326/0003-4819-106-5-728](https://doi.org/10.7326/0003-4819-106-5-728)
 13. Lipsky BA, Hirschmann JV: Drug fever. *JAMA*. 1981, 245:851-4. [10.1001/jama.1981.03310330041024](https://doi.org/10.1001/jama.1981.03310330041024)
 14. Patel RA, Gallagher JC: Drug fever. *Pharmacotherapy*. 2010, 30:57-69. [10.1592/phco.30.1.57](https://doi.org/10.1592/phco.30.1.57)
 15. Mourad O, Palda V, Detsky AS: A comprehensive evidence-based approach to fever of unknown origin. *Arch Intern Med*. 2003, 163:545-51. [10.1001/archinte.163.5.545](https://doi.org/10.1001/archinte.163.5.545)
 16. Takoi H, Togashi Y, Fujimori D, et al.: Favipiravir-induced fever in coronavirus disease 2019: a report of two cases. *Int J Infect Dis*. 2020, 101:188-90. [10.1016/j.ijid.2020.09.1450](https://doi.org/10.1016/j.ijid.2020.09.1450)
 17. Sharma K, Desai HD: Role of self-measured home blood pressure monitoring (HBPM) and effectiveness of telemedicine during the era of COVID-19 pandemic. *SN Compr Clin Med*. 2021, 3:1071-5. [10.1007/s42399-021-00852-0](https://doi.org/10.1007/s42399-021-00852-0)