

Case Report

Serious Penetrating Craniocerebral Injury Caused by a Nail Gun

Yong Hyun Jeon, M.D., Ph.D.,¹ Dong Min Kim, M.D., Ph.D.,² Sung Hoon Kim, M.D., Ph.D.,³ Seok Won Kim, M.D., Ph.D.⁴

Departments of Anatomy,¹ Internal Medicine,² Neurosurgery,⁴ College of Medicine, Chosun University, Gwangju, Korea

Department of Rehabilitation Medicine,³ Wonju Christian Hospital, Yonsei University Wonju College of Medicine, Wonju, Korea

Penetrating cerebral injuries caused by foreign bodies occur rarely due to the substantial mechanical protection offered by the skull. Throughout most of history, the brain, residing in a "closed box" of bone, has not been vulnerable to external aggression. Recently, we encountered a serious penetrating craniocerebral injury caused by a nail gun. Total excision of the offending nail via emergency craniotomy was performed, but the patient's neurologic status was not improved in spite of aggressive rehabilitative treatment. Here, we report on this troublesome case in light of a review of the relevant literature.

Key Words : Head · Injury · Penetrating.

INTRODUCTION

Penetrating cerebral injuries caused by foreign bodies other than bullets are relatively rare due to the substantial mechanical protection provided by the skull. In clinical practice, such injuries are mostly due to industrial accidents and criminal assaults^{2,8)}. Several descriptions of foreign bodies such as wood pencils or metal penetrating the cranium have appeared in the literature^{5,6)}. However, suicide attempts and self-inflicted nail gun injuries are rarely reported. A good neurological outcome can be expected if the free ends of the nails can be seen in the operative field and if the brainstem and major vessels are spared¹²⁾. Here we report on a difficult case of deep-seated intracranial nail gun injury in which the free end of the nail was not seen.

CASE REPORT

A 43-year-old man was referred to the emergency room due to altered mental status subsequent to a self-inflicted nail gun wound. During a quarrel with a co-worker, he attempted suicide by shooting himself with a nailing gun at his workplace. On physical examination, he was found to have an open laceration about 2×1 cm in the left parietal region. On neurological examination, he was found to be drowsy with a Glasgow coma scale of 14 (E4 V4 M4).

He showed right side hemiparesis (Grade II/Grade I). Plain skull radiographs revealed a 5-cm, linear, nail-shaped foreign body piercing the brain (Fig. 1).

A computed tomography (CT) scan of the brain showed the presence of a metallic foreign body in the left parietal lobe. It reached almost to the pons, and multiple fracture fragments were also seen impacted into the parietal lobe (Fig. 2).

Treatment with a combination of ceftriaxone, chloramphenicol, and metronidazole was initiated and tetanus immunization was administered. The patient was operated immediately and a local scalp incision was made at the nail entry site. After a small

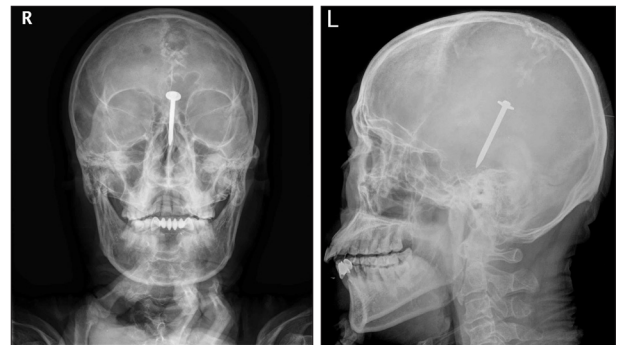


Fig. 1. Preoperative simple radiographs show the nail passing through the left parietal calvarium deep to the proximal brainstem.

• Received : December 16, 2013 • Revised : January 10, 2014 • Accepted : February 1, 2014

• Address for reprints : Seok Won Kim, M.D., Ph.D.

Department of Neurosurgery, School of Medicine, Chosun University, 365 Pilmun-daero, Dong-gu, Gwangju 501-717, Korea
Tel : +82-62-220-3126, Fax : +82-62-227-4575, E-mail : chosunns@chosun.ac.kr

• This is an Open Access article distributed under the terms of the Creative Commons Attribution Non-Commercial License (<http://creativecommons.org/licenses/by-nc/3.0>) which permits unrestricted non-commercial use, distribution, and reproduction in any medium, provided the original work is properly cited.

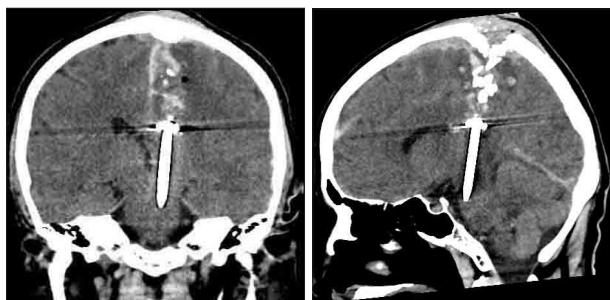


Fig. 2. Preoperative coronal and sagittal computed tomography scans reveal a penetrating metallic nail. Multiple fracture fragments are also observed.




Fig. 3. Photograph of the metallic nail after removal.

circumferential craniectomy, the nail was cautiously removed under intraoperative C-arm guidance to prevent further vascular insult or neurological aggravation (Fig. 3). After washing the wound with antibiotics, it was closed in layers over a drain.

The postoperative period was uneventful and the patient exhibited no further neurological aggravation, evidence of infection, or symptoms of raised intracranial pressure. However, in spite of aggressive rehabilitative treatment for 3 months, his right side hemiparesis was not improved and he could not ambulate by himself.

DISCUSSION

Although gunshot injury is rare in Korea due to gun control, penetrating cranial injuries still occur, mostly from shotguns¹⁰. Other causes are infrequent and include criminal assaults and industrial accidents⁹. A few cases of deliberate, self-inflicted, penetrating brain injury from nail guns have been reported^{12,13}. In most of these cases, patients survive with a good neurological outcome if the brainstem and major cerebral vessels have been spared and the offending nail is seen during physical examination. However, in our case, the free end of the nail was not seen and only the penetration site could be observed. As a result, we were obliged to remove the foreign body using blind technique.

Neuroimaging is vital for surgical decision-making in any penetrating head injury, offering guidance as to the best surgical approach, the size and site of the craniotomy, and the route of extraction of the foreign body, as well as informing the decision to

choose non-surgical management. Simple radiographs are helpful for intracranial localization of metallic foreign bodies^{1,2,5}. In the case of non-metallic bodies, cranium defects or the foreign body itself can occasionally be seen¹⁴. CT scanning of the brain is now the primary modality used in the neuroradiologic evaluation of patients with penetrating head injury. This is because CT scanning is quick and provides improved identification of in-driven bone and missile fragments, characterization of the missile trajectory, evaluation of the extent of brain injury, and detection of intracranial hematomas and mass effects¹¹. In contrast, magnetic resonance imaging has limitations that restrict its use in practice. The strength of the magnetic field poses a danger when any ferromagnetic metals are present as foreign bodies. For the same reason, we could not use a three-dimensional navigation system in our patient. It is recommended that documenting vascular damage should be performed using cerebral angiography when the foreign body is located just beneath the major arterial or venous systems¹.

In spite of the development of antibiotics, infectious complications are frequently seen in the penetrating head wound patients. Prompt surgical exploration is mandatory to reduce the mortality and complication rate. Despite antibiotic treatment, the morbidity rate is 33% in cases receiving prompt surgical treatment and rises to 53% in cases where surgery is delayed⁹. Small sized foreign bodies located deep in the brain can be left in place^{7,10,12}. If the foreign body is not in close proximity to major arteries or veins and has extracranial components, a blind removal without craniotomy can be performed. However, deterioration and death have been described after removal in such cases^{3,4}. Surgery should be performed for removal of a contaminated foreign body, repair of vascular or dural damage, or drainage of intracranial masses^{6,7}. Bony fragments should also be excised to prevent complications. Removed foreign bodies should be cultured for aerobic, anaerobic, or fungal pathogens. In our case, all cultures were negative. Complications of attempts to treat this kind of injury include meningitis, cerebral abscess, hematomas, cerebral aneurysm, hydrocephalus, and focal neurological deficits⁷.

CONCLUSION

This case demonstrates that a nail gun is a potentially dangerous tool capable of causing a penetrating brain injury. Emergency surgical removal should be performed to save the patient's life even in cases of deep penetrating injuries caused by a nail gun.

References

1. Bakay L, Glasauer FE, Grand W : Unusual intracranial foreign bodies. Report of five cases. *Acta Neurochir (Wien)* 39 : 219-231, 1977
2. Bell RS, Vo AH, Roberts R, Wanebo J, Armonda RA : Wartime traumatic aneurysms : acute presentation, diagnosis, and multimodal treatment of 64 craniocervical arterial injuries. *Neurosurgery* 66 : 66-79; discussion 79, 2010
3. Gökçek C, Erdem Y, Köktekir E, Karatay M, Bayar MA, Edebalı N, et al. : Intracranial foreign body. *Turk Neurosurg* 17 : 121-124, 2007

4. Greene KA, Dickman CA, Smith KA, Kinder EJ, Zabramski JM : Self-inflicted orbital and intracranial injury with a retained foreign body, associated with psychotic depression : case report and review. **Surg Neurol** 40 : 499-503, 1993
5. Hansen JE, Gudeman SK, Holgate RC, Saunders RA : Penetrating intracranial wood wounds : clinical limitations of computerized tomography. **J Neurosurg** 68 : 752-756, 1988
6. Kaiser MC, Rodesch G, Capesius P : CT in a case of intracranial penetration of a pencil. A case report. **Neuroradiology** 24 : 229-231, 1983
7. Kelly AJ, Pople I, Cummins BH : Unusual craniocerebral penetrating injury by a power drill : case report. **Surg Neurol** 38 : 471-472, 1992
8. Lee JI, Ko JK, Cha SH, Han IH : An unusual case of cerebral penetrating injury by a driven bone fragment secondary to blunt head trauma. **J Korean Neurosurg Soc** 50 : 532-534, 2011
9. Miller CF, Brodkey JS, Colombi BJ : The danger of intracranial wood. **Surg Neurol** 7 : 95-103, 1977
10. Miner ME, Cabrera JA, Ford E, Ewing-Cobbs L, Amling J : Intracranial penetration due to BB air rifle injuries. **Neurosurgery** 19 : 952-954, 1986
11. Offiah C, Twigg S : Imaging assessment of penetrating craniocerebral and spinal trauma. **Clin Radiol** 64 : 1146-1157, 2009
12. Sani S, Jobe KW, Byrne RW : Successful repair of an intracranial nail-gun injury involving the parietal region and the superior sagittal sinus. Case report. **J Neurosurg** 103 : 567-569, 2005
13. Winder MJ, Monteith SJ, Lightfoot N, Mee E : Penetrating head injury from nailguns : a case series from New Zealand. **J Clin Neurosci** 15 : 18-25, 2008
14. Yamamoto I, Yamada S, Sato O : Unusual craniocerebral penetrating injury by a chopstick. **Surg Neurol** 23 : 396-398, 1985