

Does the Beighton Score Correlate With Specific Measures of Shoulder Joint Laxity?

Noah A. Whitehead,^{*†‡} MBChB, Khalid D. Mohammed,^{§||¶} MBChB, FRACS, and Mark L. Fulcher,^{†‡} MBChB, MMedSci, FACSEP

Investigation performed at Sportsmed Canterbury, Christchurch, New Zealand

Background: Evaluation of shoulder joint laxity is an important component of the shoulder examination, especially in the setting of shoulder instability. Measures of generalized joint laxity, particularly the Beighton score, are often recorded and used to help make management decisions in these cases. However, no evidence is available to show that the Beighton score corresponds to specific measures of shoulder joint laxity.

Purpose: To assess the correlation between the Beighton score and validated measures of shoulder joint laxity.

Study Design: Cross-sectional study; Level of evidence, 3.

Methods: A total of 160 participants (age range, 16-35 years) with no history of shoulder joint abnormality were examined. The Beighton score, glenohumeral external rotation (standing and lying), glenohumeral abduction, and the sulcus sign were recorded. The relationship between the Beighton score and each measure of shoulder joint laxity was assessed.

Results: A high proportion of participants (34%) had a Beighton score of 4 or higher. Rates of positive shoulder laxity tests were lower (11%-19%). A positive Beighton score was a poor predictor of abnormal shoulder laxity, with low sensitivity (range, 0.40-0.48) and low positive predictive values (range, 0.13-0.31). Spearman correlation coefficients demonstrated poor correlation between the Beighton score and all measures of shoulder joint laxity when assessed as continuous variables (range, 0.29-0.45).

Conclusion: The Beighton score has poor correlation with specific measures of shoulder joint laxity and should not be considered equivalent to these tests as a method of clinical assessment.

Keywords: shoulder; shoulder instability; biomechanics of ligament; clinical assessment/grading scales; generalized joint laxity

Traumatic shoulder joint instability is a common clinical condition and is associated with high rates of recurrence. In patients who experience instability prior to age 30 years, recurrence rates of up to 90% have been reported.⁹ Surgical stabilization is often indicated and has been shown to significantly reduce the risk of recurrent instability.⁷ A number of intrinsic and extrinsic factors must be considered when one is identifying suitable surgical candidates and determining the most appropriate form of surgical

intervention. Shoulder joint laxity is one of these factors.^{2,4} An assessment of shoulder joint laxity is used as part of the Instability Severity Index Score, an externally validated and frequently cited tool used to predict the risk of recurrent instability after arthroscopic stabilization.² Along with evaluating other clinical features, this measure assesses glenohumeral external rotation and abduction to reflect anterior or inferior shoulder joint laxity. We use this scoring system in clinical practice to determine whether to use an arthroscopic Bankart or a Bristow-Laterjet procedure to treat shoulder instability.

Determining true laxity of the glenohumeral joint can be challenging because of the complexity of the combined motions of the glenohumeral and scapulothoracic articulations. Traditional measures of shoulder joint laxity involve the assessment of anterior and posterior glenohumeral translation, techniques that have been shown to be poorly reproducible and for which abnormal laxity values have been difficult to define.^{13,25} For these reasons, many practitioners also routinely assess for signs of generalized joint laxity (GJL), on the assumption that this corresponds to laxity of soft tissue structures at the shoulder joint. The Beighton and Horan Joint Mobility Index, commonly referred to as the Beighton score, is the most widely used

*Address correspondence to Noah Whitehead, MBChB, Axis Sports Medicine Specialists, 71 Merton Road, Auckland, New Zealand (email: n.whitehead@axisportsmedicine.co.nz).

†School of Population Health, University of Auckland, New Zealand.

‡Axis Sports Medicine Specialists, Auckland, New Zealand.

§Elmwood Orthopaedics, Christchurch, New Zealand.

||Christchurch School of Medicine, University of Otago, New Zealand.

¶Christchurch Public Hospital, Christchurch, New Zealand.

The authors declared that they have no conflicts of interest in the authorship and publication of this contribution.

Ethical approval for this study was provided by the University of Auckland.

The Orthopaedic Journal of Sports Medicine, 6(5), 2325967118770633

DOI: 10.1177/2325967118770633

© The Author(s) 2018

measure of GJL.²⁷ This tool is popular because of its simplicity and reported excellent intraobserver and interobserver reliabilities.³ Several studies suggest that individuals with GJL as defined by the Beighton score are at increased risk of certain musculoskeletal injuries.²⁷ Less consistent evidence is available demonstrating an association between the Beighton score and a history of shoulder instability,^{12,20,22} although a number of review articles continue to include GJL as a risk factor for recurrent instability.^{18,24}

For the Beighton score to be considered relevant to the assessment of shoulder laxity, new data are required that demonstrate a significant correlation between the variables described above. The purpose of this study was to compare the Beighton score with validated measures of shoulder laxity in a large group of participants with no history of shoulder abnormality. We aimed to determine whether the Beighton score corresponds with these measures, which may clarify whether it is an appropriate tool to guide management decisions in patients evaluated for shoulder instability.

METHODS

Approval for this study was given by the Human Participants Ethics Committee at the University of Auckland (reference No. 016893). Data were collected from a convenience sample of participants evaluated at a single sports medicine clinic between April and December 2016. Participants were aged between 16 and 35 years and were excluded if they had any history of shoulder joint abnormality or any systemic disorder affecting joint movement and/or function. After each participant answered a standardized questionnaire that assessed whether he or she met the study criteria, the participant underwent focused clinical examination performed by a single examiner (N.A.W.).

The presence or absence of GJL was determined by assessment of the Beighton score. The Beighton score involves 9 separate range of motion measurements as follows:

- Trunk and hip flexion—a positive test defined as the ability to place the palms flat on the floor while keeping the knees extended.
- Bilateral knee extension—a positive test defined as at least 10° of hyperextension.
- Bilateral elbow extension—a positive test defined as at least 10° of hyperextension.
- Bilateral thumb to forearm apposition—a positive test defined as the ability to appose the thumb and volar aspect of the forearm.
- Bilateral little finger extension—a positive test defined as at least 90° of hyperextension.

The technique of assessment was performed as described by Boyle et al³ in their reproducibility study and is demonstrated in Figure 1. Each positive test was awarded 1 point, and the composite score was placed in

one of two categories, 0-3 (negative for GJL) and 4-9 (positive for GJL).²⁷

Standing glenohumeral external rotation was assessed as performed for the Instability Severity Index Score.² The participant's elbows were flexed to 90° with forearms in a neutral pronated position. The elbows were kept in contact with the trunk in the midaxillary line, and the participant was instructed to actively, externally rotate at both shoulders as far as able without lifting or shifting the position of the elbows. The examiner measured the range of external rotation with a goniometer using the ulnar styloid as a reference point. A result greater than 85° for this test was considered positive for anterior joint laxity.²

External rotation was also assessed with the participant supine, as described by Ropars et al²³ (the "elbow on the table" method). The participant's elbow was flexed to 90° and rested by the participant's side on the examination table. A gentle pressure was applied to the participant's wrist, encouraging external rotation at the shoulder until resistance was felt. Range of external rotation was measured with a goniometer as described above and was considered positive for anterior joint laxity if greater than 90°.²³

The range of passive glenohumeral abduction as a measure of inferior joint laxity was performed as described by Gagey and Gagey⁶ and used in the Instability Severity Index Score.² The examiner stood behind the participant, pressing down on the shoulder girdle at its lowest position to stabilize the scapula. The relaxed upper limb was lifted into abduction until resistance was felt. The examiner measured range of motion with a goniometer with the fulcrum placed over the posterior process of the acromion and using the lateral epicondyle of the humerus as a reference point. The test was considered positive if the range of movement was greater than 105°.⁶

The sulcus sign was performed with the participant sitting on the examination table with his or her arm relaxed at the side and with the shoulder in a position of neutral rotation. The examiner placed a hand on the participant's shoulder to stabilize the scapula while applying a distracting force by using the other hand to pull down on the participant's arm. The magnitude of inferior glenohumeral joint translation was estimated by observing the formation of a sulcus between the inferior margin of the acromion and the humeral head and was graded 0 to 1 (<1 cm), 2 (1-2 cm), or 3 (>2 cm). A sulcus sign of grade 2 or 3 was considered significant. The examination techniques used to assess shoulder joint laxity are illustrated in Figure 2.

Sensitivity, specificity, positive predictive value, and negative predictive value were determined for a positive Beighton score as a predictive tool for abnormal shoulder joint laxity tests. Spearman correlation coefficients (SCCs) were determined by comparing the Beighton score and each shoulder laxity test as continuous variables. Differences in mean laxity values between participants with a positive and negative Beighton score were assessed by use of a linear regression model (a generalized linear model for the sulcus sign) controlling for age and sex. Data analysis was conducted using SAS statistics software (v 9.4; SAS Institute).

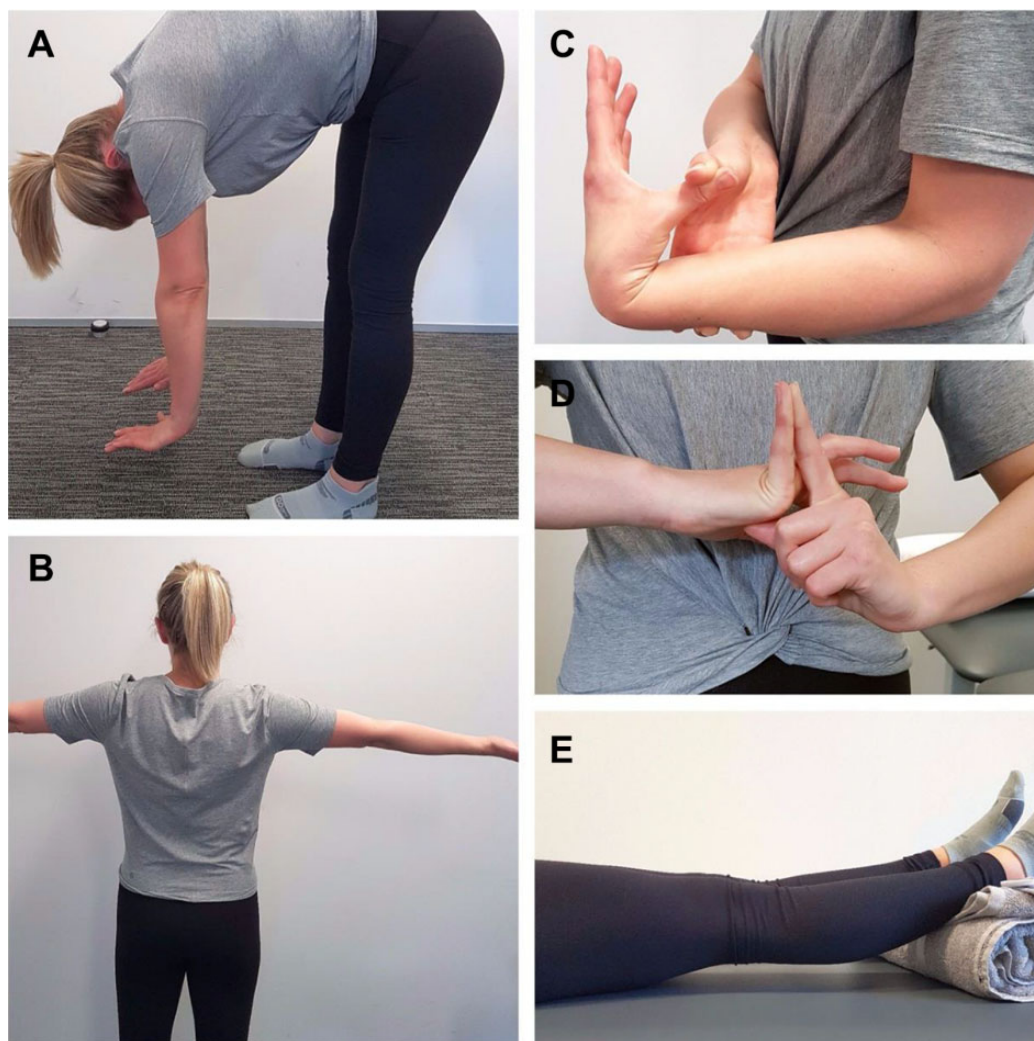


Figure 1. Assessment of the Beighton score. (A) Trunk and hip flexion—a positive test is defined as the ability to place the palms flat on the floor while keeping the knees extended. (B) Elbow extension—a positive test is defined as at least 10° of hyperextension. (C) Thumb to forearm apposition—a positive test is defined as the ability to appose the thumb and forearm. (D) Little finger extension—a positive test is defined as at least 90° of hyperextension. (E) Knee extension—a positive test is defined as at least 10° of hyperextension. With the exception of trunk and hip flexion, all measurements are performed bilaterally.

RESULTS

Characteristics of the study participants are presented in Table 1. Of the 160 participants, 55 (34%) had a Beighton score of 4 or higher, 25 (16%) of the participants had a positive value for standing external rotation, 29 (18%) had a positive value for lying external rotation, 18 (11%) had a positive value for abduction, and 30 (19%) had a positive sulcus sign. As expected, females were significantly more likely to have a positive Beighton score (odds ratio [OR], 3.8; 95% CI, 1.8-8.0). Positive values for external rotation, both standing (OR, 5.0; 95% CI, 1.6-15.4) and lying (OR 4.7; 95% CI, 1.7-13.1), and for abduction (OR 3.0; 95% CI, 1.0-9.7) were also more common in women. A positive sulcus sign was equally likely in men and women (OR, 1.0). Small but significant differences were found in the mean values for standing and lying external rotation and abduction

between participants with a positive and those with a negative Beighton score ($P \leq .03$). No difference was noted in the mean grade of sulcus sign between these groups.

The sensitivity, specificity, and positive and negative predictive values for a positive Beighton score as a predictive tool for abnormal individual shoulder laxity tests are presented in Table 2 along with the percentages of agreement between the Beighton score and these tests. Sensitivity was low for all laxity measures (range, 0.40-0.48), as were positive predictive values (range, 0.13-0.31). Specificity was moderate for all laxity measures (range, 0.66-0.69), and the negative predictive values were high (range, 0.81-0.90). When a positive value for either external rotation or abduction was regarded as representative of shoulder joint laxity (as was defined in the Instability Severity Index Score), the sensitivity (0.46) and positive predictive value (0.25) remained low. We also tested the effect of increasing

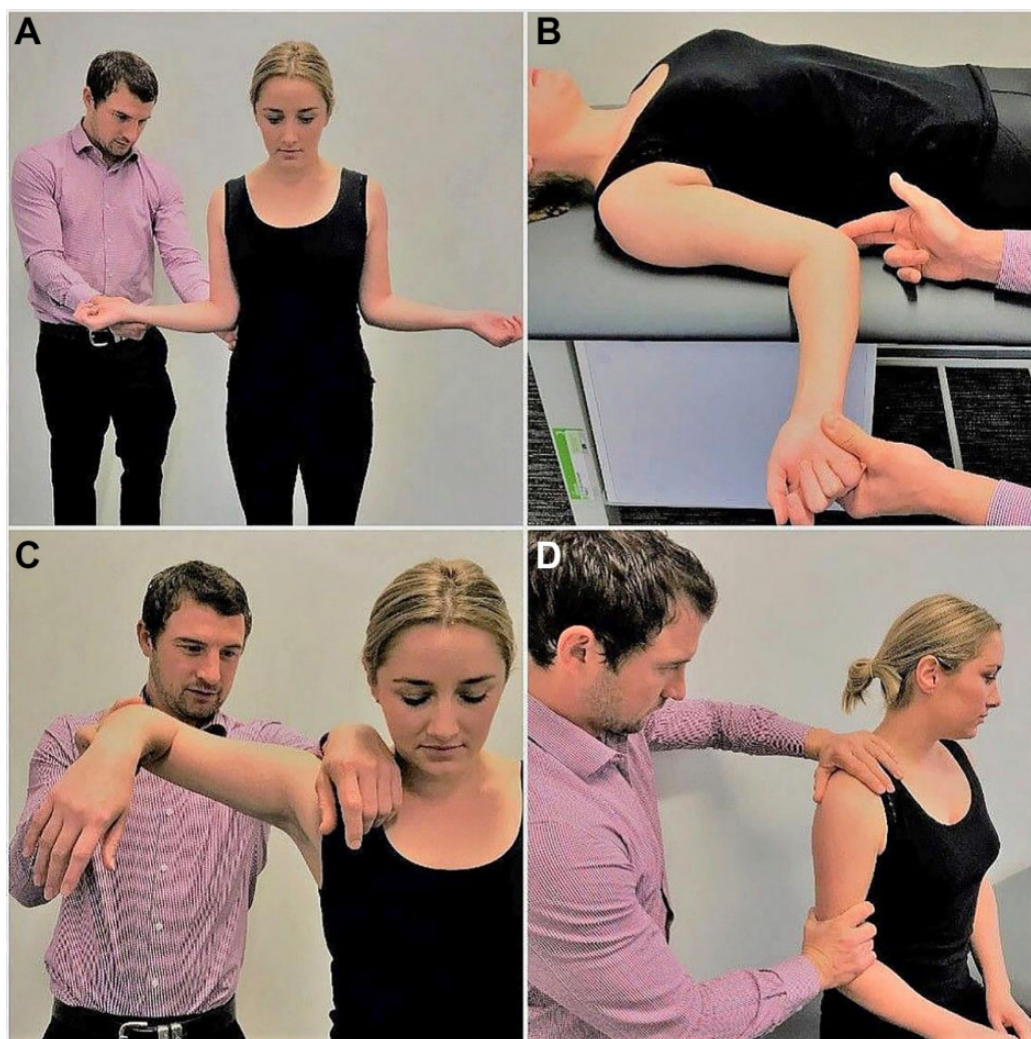


Figure 2. Clinical examination techniques used to assess shoulder laxity. (A) Standing external rotation. (B) Lying external rotation. (C) Gagey test for hyperabduction. (D) Sulcus sign.

TABLE 1
 Characteristics of Study Population and Results of Examination
 for Beighton Score and Shoulder Joint Laxity Tests

	Total Population	Beighton-Positive Group ^a	Beighton-Negative Group ^a	<i>P</i>
Participants, n	160	55 (34%)	105 (66%)	
Age, y, mean (range)	24.7 (16-35)	24.7 (16-35)	24.7 (16-35)	
Male, n	70	13	57	
Female, n	90	42	48	
Standing external rotation, deg, mean	64	70	60	.01
Standing external rotation >85°, n	25 (16%)	12	13	.12
Lying external rotation, deg, mean	76	81	73	.03
Lying external rotation >90°, n	29 (18%)	14	15	.67
Abduction, deg, mean	94	97	92	.03
Abduction >105°, n	18 (11%)	7	11	.76
Sulcus sign, mean	1.0	1.1	0.9	.48
Sulcus sign >1, n	30 (19%)	12	18	.92

^a“Beighton-positive” indicates participants with a Beighton score ≥ 4 ; “Beighton-negative” indicates a score < 4 .

TABLE 2
Positive Beighton Score as a Predictor of Abnormal Shoulder Laxity Tests^a

	Sensitivity	Specificity	Positive Predictive Value	Negative Predictive Value	Agreement, %
Standing external rotation >85°	0.48 (0.28-0.67)	0.68 (0.60-0.76)	0.22 (0.11-0.33)	0.88 (0.67-0.89)	65
Lying external rotation >90°	0.48 (0.30-0.76)	0.69 (0.60-0.76)	0.25 (0.13-0.36)	0.86 (0.79-0.92)	65
Abduction >105°	0.42 (0.20-0.64)	0.66 (0.58-0.74)	0.13 (0.04-0.22)	0.90 (0.84-0.95)	63
Abnormal abduction or external rotation	0.46 (0.30-0.62)	0.69 (0.61-0.77)	0.31 (0.19-0.43)	0.81 (0.73-0.88)	63
Sulcus sign grade >1	0.40 (0.22-0.58)	0.67 (0.59-0.75)	0.22 (0.11-0.33)	0.83 (0.76-0.89)	62

^aCI's are given in parentheses.

the cut-off value for a positive Beighton score to 6 or higher. This produced only a modest increase in the positive predictive values, which ranged from 0.25 to 0.44 for all shoulder laxity tests.

The Beighton score and shoulder laxity values were compared as continuous variables by use of SCCs. The Beighton score had a poor correlation with standing external rotation (SCC, 0.45), lying external rotation (SCC, 0.36), passive glenohumeral abduction (SCC, 0.29), and the sulcus sign (SCC, 0.29).

DISCUSSION

This study demonstrates that the Beighton score is poorly correlated with specific measures of shoulder joint laxity, namely glenohumeral external rotation, abduction, and the sulcus sign. In the current study, a positive Beighton score provided little value in predicting abnormal shoulder laxity as defined by specific cut-off values published in the literature.^{2,6,8,23} SCCs comparing the Beighton score and each measure of shoulder joint laxity as continuous variables varied from 0.29 to 0.45. This is considered to represent weak to modest correlation.²⁶ These correlation coefficients were considered significant ($P < .05$ in each case). P values also confirmed a small but significant difference between mean values for external rotation and abduction between groups with a positive and negative Beighton score (Table 1). This was consistent with the low levels of positive correlation presented.

The cut-off value for the diagnosis of GJL by use of the Beighton score was arbitrary, although a score of 4 or higher is most commonly cited in the literature.²⁷ Using a higher threshold value is expected to lower sensitivity but also to reduce the number of false-positive results. As stated, increasing the threshold for a positive Beighton score to 6 or higher resulted in only a small improvement in the positive predictive values and did not alter the study conclusions.

It is currently common clinical practice to record the Beighton score as part of the shoulder examination even though several previous studies have failed to demonstrate

a clear correlation between the Beighton score and anterior and posterior glenohumeral joint translation.^{14,25} Unfortunately, it is difficult to interpret these data because a wide range of normal laxity values have been reported,^{1,14} and the assessment of glenohumeral translation is associated with poor reliability.¹³ For this reason, we compared the Beighton score with alternative measures of shoulder laxity.

The literature provides support for the tests used in our study. The ranges of glenohumeral external rotation and abduction have been shown in cadaveric studies to be limited by the inferior glenohumeral ligament,^{6,17} an important stabilizer of the shoulder joint. Other studies have shown the range of external rotation and abduction to be increased in participants with a history of shoulder instability.^{4,6} These movements can be assessed by practitioners with a range of clinical experience, with excellent intra-examiner and interexaminer reliabilities.^{11,15} The sulcus sign has traditionally been considered the best measure of inferior shoulder joint laxity.^{1,24} As with measures of anterior and posterior glenohumeral joint translation, a wide range of inferior translation is often reported and is not considered an abnormal finding.¹⁶ However, one study, consisting of more than 1200 participants, found a sulcus sign of 2 or greater to be significantly associated with a history of shoulder instability.⁸ Interexaminer reproducibility of the sulcus sign has also been reported to be excellent when low laxity values are equalized.¹³

The current study has some limitations. First, the use of a convenience sample of participants, despite the broad inclusion criteria, may limit generalizability of the data. The proportion of participants with a positive Beighton score was higher than reported in most prevalence studies.^{10,21} This may reflect differences in the study population, who were all patients presenting to a specialist sports medicine clinic for the assessment of musculoskeletal injury. A population subset with high rates of joint laxity is appropriate for the aims of this study and does not change the nature of the conclusions drawn.

Second, the results may have been affected by observer error. No reproducibility data were provided as part of the study, although previous publications have provided validation for each of the tests used. As well, examination

results were not subject to blinding. This introduces the potential for bias, but any bias is limited by the objective nature of the data.

Third, a gold standard measure of shoulder joint laxity is not available, which limited the ability to draw broad and clinically meaningful conclusions from the data. We are only able to comment confidently about relationships with the specific tests performed. These tests were chosen because they have received validation in the literature, as discussed. The sulcus sign was performed in neutral rotation only and not in external rotation, which is performed routinely by some practitioners to assess competency of the rotator interval. This study did not investigate the association between laxity measures and the risk of shoulder injury or the response to treatment (which includes failure of surgical stabilization). It is possible that the Beighton score may have an association with these important clinical variables, independent of a relationship with shoulder laxity.

Fourth, the study population consisted of asymptomatic participants in whom the Beighton score and measures of shoulder joint laxity have little clinical relevance. It is possible that a greater correlation would be found between the Beighton score and shoulder range of motion values in patients who have anterior or inferior shoulder instability or, particularly, in patients with multidirectional instability, among whom there are high rates of GJL.¹⁹

The current study also has strengths. First, the number of participants included is much larger than in previous similar studies.^{5,14,25} Second, the shoulder laxity tests performed have been validated in the literature with acceptable levels of reproducibility. Third, the tests were performed by a single examiner, which eliminates potential error from interexaminer variability.

CONCLUSION

This study adds to the literature investigating the relevance of the Beighton score to shoulder joint laxity. The data set provides evidence that there is poor correlation between the Beighton score and the validated measures of shoulder laxity performed, a finding that has implications for clinical practice. The Beighton score cannot be considered as an equivalent alternative to shoulder laxity tests. Clinicians should be cautious when using the Beighton score as part of the shoulder laxity examination and when using this information to plan the management of shoulder joint instability.

Future studies investigating the relationship between GJL and shoulder joint laxity should present reproducibility data and include blinding of examination results. Ideally, participants would be prospectively followed to see whether, irrespective of the relationship with shoulder laxity, the presence of GJL has implications for the risk of shoulder instability and subsequent management of this condition.

ACKNOWLEDGMENT

The authors thank Dr Deborah Robinson, who helped with study design.

REFERENCES

1. Bahk M, Keyurapan E, Tasaki A, et al. Laxity testing of the shoulder: a review. *Am J Sports Med.* 2007;35(1):131-144.
2. Balg F, Boileau P. The instability severity index score: a simple pre-operative score to select patients for arthroscopic or open shoulder stabilisation. *J Bone Joint Surg Br.* 2007;89(11):1470-1477.
3. Boyle KL, Witt P, Riegger-Krugh C. Intrarater and interrater reliability of the Beighton and Horan joint mobility index. *J Athl Train.* 2003;38(4):281-285.
4. Chahal J, Leiter J, McKee MD, et al. Generalized ligamentous laxity as a predisposing factor for primary traumatic anterior shoulder dislocation. *J Shoulder Elbow Surg.* 2010;19(8):1238-1242.
5. Emery RJ, Mullaji AB. Glenohumeral joint instability in normal adolescents: incidence and significance. *J Bone Joint Surg Br.* 1991;73(3):406-408.
6. Gagey OJ, Gagey N. The hyperabduction test. *J Bone Joint Surg Br.* 2001;83(1):69-74.
7. Handoll HHG, Almayyah MA, Rangan A. Surgical versus non-surgical treatment for acute anterior shoulder dislocation. *Cochrane Database Syst Rev.* 2004;(1):CD004325.
8. Jia X, Ji JH, Petersen SA, et al. An analysis of shoulder laxity in patients undergoing shoulder surgery. *J Bone Joint Surg Am.* 2009;91(9):2144-2150.
9. Kane P, Bifano SM, Dodson CC, et al. Approach to the treatment of primary anterior shoulder dislocation: a review. *Phys Sportsmed.* 2015;43(1):54-64.
10. Klemp P, Williams SM, Stansfield SA. Articular mobility in Maori and European New Zealanders. *Rheumatology (Oxford).* 2002;41(5):554-557.
11. Kolber MJ, Hanney WJ. The reliability and concurrent validity of shoulder mobility measurements using a digital inclinometer and goniometer: a technical report. *Int J Sports Phys Ther.* 2012;7(3):306-313.
12. Koyonos L, Kraeutler MJ, O'Brien DF, et al. A prospective cohort study investigating the effect of generalized joint hypermobility on outcomes after arthroscopic anterior shoulder stabilization. *Phys Sportsmed.* 2016;44(4):380-384.
13. Levy AS, Lintner S, Kenter K, et al. Intra- and interobserver reproducibility of the shoulder laxity examination. *Am J Sports Med.* 1999;27(4):460-463.
14. Lintner SA, Levy A, Kenter K, et al. Glenohumeral translation in the asymptomatic athlete's shoulder and its relationship to other clinically measurable anthropometric variables. *Am J Sports Med.* 1996;24(6):716-720.
15. MacDermid JC, Chesworth BM, Patterson S, et al. Intratester and intertester reliability of goniometric measurement of passive lateral shoulder rotation. *J Hand Ther.* 1999;12(3):187-192.
16. McFarland EG, Campbell G, McDowell J. Posterior shoulder laxity in asymptomatic athletes. *Am J Sports Med.* 1996;24(4):468-471.
17. Mihata T, Lee Y, McGarry MH, et al. Excessive humeral external rotation results in increased shoulder laxity. *Am J Sports Med.* 2004;32(5):1278-1285.
18. Olds M, Ellis R, Donaldson K, et al. Risk factors which predispose first-time traumatic anterior shoulder dislocations to recurrent instability in adults: a systematic review and meta-analysis. *Br J Sports Med.* 2015;49(14):913-922.
19. Provencher MT, Romeo AA. Posterior and multidirectional instability of the shoulder: challenges associated with diagnosis and management. *Instr Course Lect.* 2008;57:133-152.
20. Ranalletta M, Bongiovanni S, Suarez F, et al. Do patients with traumatic recurrent anterior shoulder instability have generalized joint laxity? *Clin Orthop Relat Res.* 2012;470(4):957-960.
21. Remvig L, Jensen DV, Ward RC. Epidemiology of general joint hypermobility and basis for the proposed criteria for benign joint hypermobility syndrome: review of the literature. *J Rheumatol.* 2007;34(4):804-809.
22. Robinson CM, Howes J, Murdoch H, et al. Functional outcome and risk of recurrent instability after primary traumatic anterior shoulder

- dislocation in young patients. *J Bone Joint Surg Am.* 2006;88(11):2326-2336.
23. Ropars M, Fournier A, Campillo B, et al. Clinical assessment of external rotation for the diagnosis of anterior shoulder hyperlaxity. *Orthop Traumatol Surg Res.* 2010;96(suppl 8):S84-S87.
 24. Saccomanno MF, Fodale M, Capasso L, et al. Generalized joint laxity and multidirectional instability of the shoulder. *Joints.* 2013;1(4):171-179.
 25. Sauers EL, Borsa PA, Herling DE, et al. Instrumented measurement of glenohumeral joint laxity and its relationship to passive range of motion and generalized joint laxity. *Am J Sports Med.* 2001;29(2):143-150.
 26. Taylor R. Interpretation of the correlation coefficient: a basic review. *J Diagn Med Sonogr.* 1990;6(1):35-39.
 27. Wolf JM, Cameron KL, Owens BD. Impact of joint laxity and hypermobility on the musculoskeletal system. *J Am Acad Orthop Surg.* 2011;19(8):463-471.