


The Jailed Sinoatrial Node: An Interesting Case of Cardiogenic Shock Secondary to Sinus Arrest Following Percutaneous Intervention

Journal of Investigative Medicine High
Impact Case Reports
Volume 10: 1–4
© 2022 American Federation for
Medical Research
DOI: 10.1177/23247096221114524
journals.sagepub.com/home/hic


Ebubechukwu Ezeh, MD¹ , Esiemoghie Akhigbe, MD¹,
Mohammad Amro, MD², Ebad Ur Rahman, MD³ ,
Saad Malik, MD¹, Kanaan Mansoor, MD⁴,
and Mehiar Elhamdani, MD⁴

Abstract

Complete occlusion of the sinoatrial node artery can be a complication of percutaneous intervention (PCI) to the right coronary artery (RCA). When this happens, dysfunction of the sinus node may follow resulting in sinus arrest. When this occurs, it is usually transient and as such, is typically not accompanied by hemodynamic instability. Permanent sinus arrest and shock state may, however, occur on rare occasions. The presence of junctional rhythms on the electrocardiogram (ECG) may predict the occurrence of these permanent arrhythmias and cardiogenic shock. In this case report, we present a 78-year-old woman who developed cardiogenic shock secondary to sinus arrest following PCI to RCA. Her ECG showed junctional rhythm, and she went on to require permanent ventricular pacing. This illustrates a known but rare complication of PCI to RCA.

Keywords

sinoatrial, coronary, pacemaker, cardiogenic, bradycardia

Introduction

The anatomy of the sinus node (SN) artery (SNA) is highly variable. It often has one of 2 origins—either the right coronary artery (RCA) or the left circumflex branch.¹ In almost 60% of cases, the SNA originates from RCA. In another 30%, it originates from the circumflex artery.² In the remaining 10% of cases, the SN has a dual blood supply from the RCA and circumflex arteries.² Although SNA occlusion is a known complication of percutaneous intervention (PCI) to proximal RCA, the incidence of sinus arrest resulting from SN arterial ischemia is rare.³ When this occurs, it is mostly transient and rarely causes unstable hemodynamics³; it usually reverts to normal sinus within few days. Here, we describe a rare case in which SN artery occlusion resulted in cardiogenic shock in a patient who underwent RCA stent placement.

Case Presentation

A 78-year-old woman with medical history significant for hypertension and nonobstructive coronary artery disease presented to our hospital with a 3-day history of shortness of breath on exertion. She reported associated lightheadedness and palpitations that last for a few minutes. On

¹Marshall University, Huntington, WV, USA

²Palestinian Ministry of Health and Higher Education, Nablus, Palestine

³Saint Mary's Medical Center, Huntington, WV, USA

⁴Marshall Cardiology Department, Huntington, WV, USA

Received March 29, 2022. Revised June 18, 2022. Accepted July 3, 2022.

Corresponding Author:

Ebubechukwu Ezeh, MD, Internal Medicine Department, School of Medicine, Marshall University, Huntington, WV 25701, USA.

Email: ezehe@marshall.edu



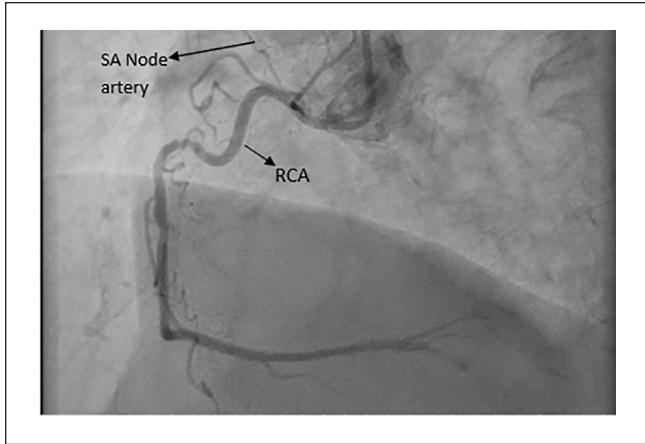


Figure 1. Patent SA node artery.
Abbreviation: SA, sinoatrial.

physical examination, patient was anxious. Vital signs were heart rate 95 beats per minute (bpm), blood pressure 164/85 mm Hg, and oxygen saturation 96%. Electrocardiogram (ECG) at this time showed sinus rhythm with a rate of 97 bpm. Echocardiogram showed critical aortic stenosis with mean gradient 68 mm Hg, aortic valve area 0.8 cm². She was worked up for transcatheter aortic valve replacement. Left heart catheterization was performed and showed 70% stenosis in both the ostial and mid segments of the RCA. The pre-intervention sinoatrial (SA) node artery is shown in Figure 1.

Percutaneous intervention to the ostial and proximal RCA was performed using everolimus drug-eluting stents. Postprocedure residual stenosis was 0% with a complete thrombolysis in myocardial infarction flow.

Approximately 8 hours after the intervention, the patient started experiencing multiple symptomatic sinus pauses with bradycardia while on telemetry. Electrocardiogram performed at this time showed junctional rhythm with a heart rate of 30 bpm as in Figure 2. She was hemodynamically unstable with systolic blood pressure in the 60 seconds. She had weak peripheral pulses and cold, clammy extremities. Dobutamine was infused until emergent temporary pacemaker wire was pulled into right ventricle (RV). On placement in the right ventricular apex, pacer was checked, and the patient was ventricularly pacing. The sheath was sutured in place and balloon deflated and the patient was sent to the regular floor in stable condition with RV pacing at a rate of 70 with output of 10 mA and a good capture. Her blood pressure and clinical status improved. She was thought to have experienced SN infarction from occlusion of sinus nodal artery during the PCI to RCA. This was confirmed by a detailed postprocedure review of the patient's coronary angiography which demonstrated occlusion SA node artery as shown in Figure 3.

Patient continued to be pacer-dependent 5 days later. A joint decision was, therefore, made with the patient to proceed with the placement of a dual-chamber permanent pacemaker. This is shown in Figure 4. Patient was discharged to in a stable condition but was lost to follow-up.

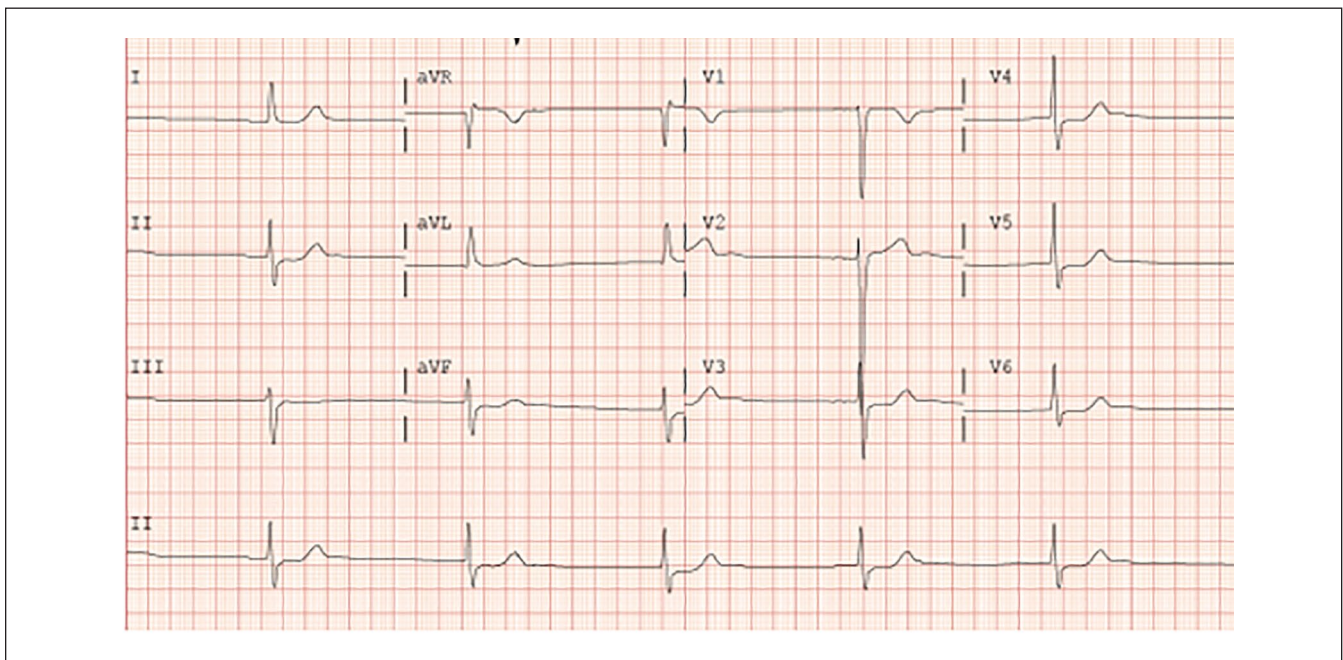


Figure 2. ECG showing junctional rhythm.

Discussion

Although it is a documented complication of PCI, the actual occurrence of SN dysfunction from an ischemic origin is relatively rare.⁴ One study indicates that SNA occlusion during angioplasty occurs in only about 5.3% of all PCIs involving the RCA's proximal segment and the circumflex artery.⁵ When it occurs, sinus node artery occlusion (SNO) has been reported to induce variable arrhythmias which include sinus bradycardia, sinus arrest, junctional escape rhythm, and sinoatrial block.⁶ Our patient experienced sinus bradycardia and sinus arrest which resulted in cardiogenic shock.

Sinus node dysfunction (SND) usually occurs during the first 24 hours of PCI⁵ as was the case with our patient. Sinus node dysfunction caused by occlusion of the SN artery during PCI, however, typically disappears almost within the first 24 to 48 hours, or if longer, in less than 1 week. This was not the case in our patient as she went on to require placement of dual-chamber pacemaker which is an uncommon sequela.⁷ In one study that reported 15 cases of periprocedural SNO, only 1 patient required permanent pacemaker implantation.⁵ This makes our case peculiar.

Again, sinus arrest caused by SNA occlusion does not usually result in hemodynamic instability.⁸ More serious and permanent arrhythmia may be predicted by the presence of junctional or escaped nodal rhythms following SNO, and patients who manifest these are more likely require to ventricular pacing.⁶ This was the case with our patient as she had junctional rhythm as shown on the ECG above. She ended up requiring permanent pacing. Rarely, SN artery occlusion may require revascularization on account of cardiogenic shock.⁸ Our patient did not need this as her shock state improved with inotropes and eventually pacing.

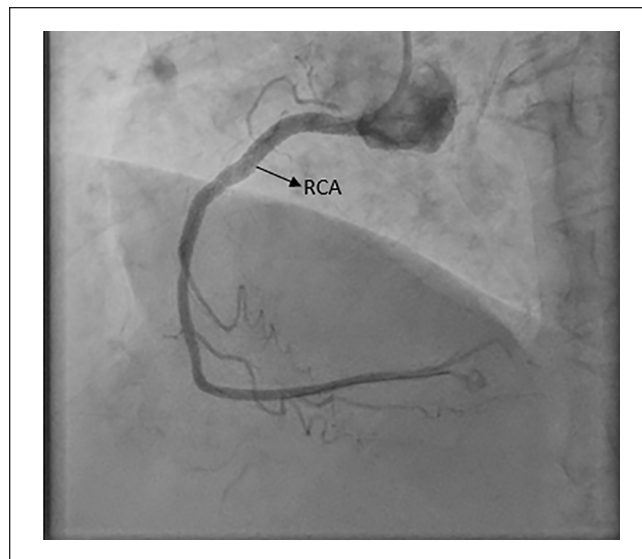


Figure 3. Post RCA stent showing poorly visualized SA node artery.

Abbreviations: RCA, right coronary artery; SA, sinoatrial.

Conclusion

Although uncommon, acute occlusion of SN artery following PCI should be promptly recognized as it can be complicated by cardiogenic shock. This is especially true if ECG shows junctional rhythm and patient becomes hemodynamic unstable following PCI. For this reason, close postprocedure monitoring of hemodynamics is important. Also, close follow-up of patient who develop SND following PCI is equally important as the SN may potentially recover function after several months.

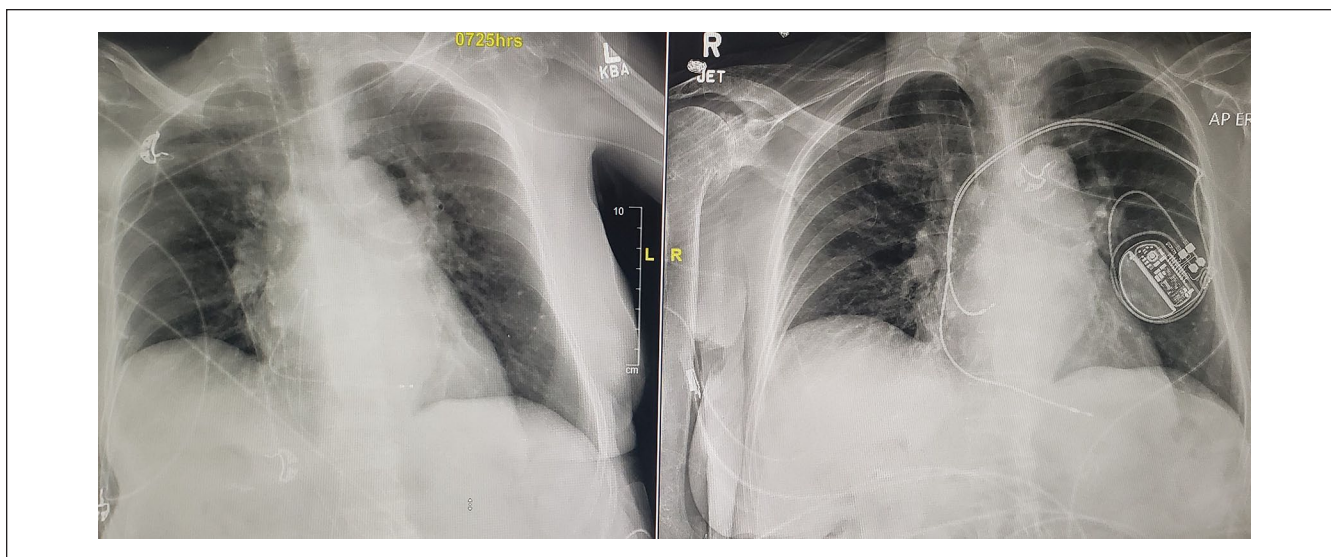


Figure 4. Depicting patient's chest x-ray on admission (left) and after the placement of pacemaker (right).

Authors' Note

Prior Presentation of Abstract Statement: The abstract of this paper was accepted and presented as a poster at the American College of Cardiology (ACC) conference that was held in April 2022 at Washington DC.

Declaration of Conflicting Interests

The author(s) declared no potential conflicts of interest with respect to the research, authorship, and/or publication of this article.

Funding

The author(s) received no financial support for the research, authorship, and/or publication of this article.

Ethics Approval

Our institution does not require ethical approval for reporting individual cases or case series.

Informed Consent

Informed consent for patient information to be published in this article was not obtained because our institution does not require consent for anonymized patient information.

ORCID iDs

Ebubekwu Ezech  <https://orcid.org/0000-0003-4700-4546>

Ebad Ur Rahman  <https://orcid.org/0000-0002-4743-5680>

References

1. Boppana VS, Castaño A, Avula U, et al. Atrial coronary arteries: anatomy and atrial perfusion territories. *J Atrial Fibr.* 2011;4(3):375. doi:10.4022/jafib.375.
2. Kyriakidis MK, Kourouklis CB, Papaioannou JT, et al. Sinus node coronary arteries studied with angiography. *e-Am J Cardiol.* 1983;51:749-750.
3. Deeprasertkul P, Thakur RK. Sinus arrest following right coronary artery stent implantation. *Int Arch Med.* 2012;5:11.
4. Rubenstein JJ, Schulman CL, Yurchak PM, et al. Clinical spectrum of the sick sinus syndrome. *Circulation.* 1972;46:5-13.
5. Koren O, Antonelli D, Khamaise R, Ehrenberg S, Rozner E, Turgeman Y. Sinus node dysfunction due to occlusion of the sinus node artery during percutaneous coronary intervention. *J Interv Cardiol.* 2021;2021:8810484. doi:10.1155/2021/8810484.
6. Haraki T, Hirase H, Hoda S, Hashimoto M, Higashi M. Sinus dysfunction after stent implantation in the right coronary artery immediately recovered after reflow in the sinus node artery. *Cardiovasc Interv Ther.* 2014;29(2):173-176. doi:10.1007/s12928-013-0208-6.
7. Kotoku M, Tamura A, Naono S, Kadota J. Sinus arrest caused by occlusion of the sinus node artery during percutaneous coronary intervention for lesions of the proximal right coronary artery. *Heart Vessels.* 2007;22(6):389-392.
8. Nakamura T, Sasaki W, Matsumoto M. Cardiogenic shock caused by sinus node artery occlusion following stent implantation. *IHJ Cardiovasc Case Rep.* 2019;3(3):91-94. doi:10.1016/j.ihjccr.2019.12.005.