

Ependymitis, Leukoencephalitis, Hydrocephalus, and Thrombotic Vasculitis Following Chronic Infection by Mouse Hepatitis Virus 3 (MHV 3)*

M. Tardieu^{1,2}, A. Goffinet^{1,3}, G. Harmant-van Rijckevorsel^{1,3}, and G. Lyon¹

¹ Unité de Neurologie du Développement, Université de Louvain, Ecole de Médecine, Bruxelles, Belgium

² Unité de Recherche INSERM U 56, Hôpital de Bicêtre, F-94200 Bicêtre, France

³ Chargé de Recherche of the FNRS, Belgium

Summary. Mouse hepatitis virus 3 (MHV 3) is either avirulent (resistant mice), hepatotropic (susceptible mice), or neurotropic (semisusceptible mice), depending on the strain of mice infected. In semisusceptible mice, infection led first to a transient meningitis, ependymitis, and leukoencephalitis, followed by a permanent communicating hydrocephalus and, later on, to a chronic thrombotic vasculitis affecting meningeal and parenchymal vessels at the brain stem level. Small foci of ischemic necrosis related to vascular occlusions were seen in the dorsal brain stem. Cyclophosphamide treatment of semisusceptible mice significantly reduced the meningeal infiltrates but did not prevent the development of hydrocephalus and other neuropathologic changes. Identical lesions occurred in fully susceptible mice infected with a low dose of virus, but no neurologic disorder could be induced in genetically resistant mice even following immunosuppression or intracranial inoculation. The leukoencephalitis differed from the demyelinating lesions observed with MHV 4. Vascular lesions were of particular interest. More attention should be given to the possibility of virus induced chronic cerebral vasculitis in man.

Key words: MHV 3 – Viral vasculitis – Experimental hydrocephalus – Experimental leukoencephalitis

Introduction

Differences in susceptibility to virus infection depend on characteristics of injected virus (Weiner et al. 1977;

* Supported by the Fonds National de la Recherche Scientifique, Belgium, grant no. 3.4540.81, by the Fonds de Développement Scientifique, Faculté de Médecine, Université de Louvain, and by INSERM contract CRL 82 60 36

Offprint requests to: Professor G. Lyon, Service de Neurologie Pédiatrique, Cliniques Universitaires Saint-Luc, UCL, Avenue Hippocrate 10, B-1200 Bruxelles, Belgique

Wolinsky and Stroop 1978), the route of infection (Johnson 1964), and on host genetic factors and immune function (Allison 1965; Hirsch et al. 1970; Levy-Leblond et al. 1979). Mouse hepatitis virus 3 (MHV 3), a member of the corona virus group, is either avirulent, hepatotropic, or neurotropic, depending on the strain of mice infected. Adult A/J mice are fully resistant to the virus. Susceptible strains (e.g., DBA/2 or BALB/c) develop an acute hepatic necrosis leading to death within a few days. Some mouse strains (e.g., C3H/He) as well as F 1 hybrids between resistant and susceptible strains exhibit a “semisusceptibility” resulting either in early death or, in surviving animals, in the development of a chronic disease with neurologic manifestations and virus persistence (Dupuy et al. 1975; Le Prevost et al. 1975a, b). Ependymitis and vasculitis have been reported (Virelizier et al. 1975). Susceptibility or resistance to MHV 3 infection has been shown to be under the influence of at least two major gene complexes, one for the acute disease and the other, H-2 linked, for the chronic disease (Levy-Leblond et al. 1979). In addition to genetic factors, one of us has observed that host defense against MHV 3 infection requires at least three types of immunocompetent cells: T-lymphocytes, splenic macrophages, and NK-like lymphoid cells (Tardieu et al. 1980).

The aim of the present neuropathologic study was to better delineate the interaction of MHV 3 with the different cells of the central nervous system (CNS), as influenced by the genetic background and immunologic status of the host. Of particular interest were an early transient leukoencephalitis and a chronic thrombotic vasculitis in the later stage of the disease.

Material and Methods

Mice

Inbred mouse strains C3H/He Orl, DBA/2 Orl, BALB/c Orl, A/J Orl were purchased from the Centre de Sélection et d'Élevage

d'Animaux de Laboratoire, 45 Orléans-La Source, France. (C57Bl/6 × A/J) FI hybrids (thereafter designed as BAF 1 mice) were bred in our mouse colony as previously described (Le Prevost et al. 1975a).

Virus

Passage, assay, and recovery of MHV 3 were performed in susceptible DBA/2 mice as reported previously (Le Prevost et al. 1975a). Virus titer was expressed in LD 50/g of tissue.

The virus was injected intraperitoneally (i.p.) at a dose of 10^3 LD 50 in 0.1 ml of saline buffer unless otherwise specified. In a group of A/J strain mice, 10^3 LD 50 of viral suspension were injected intracerebrally through a burhole in the parietal bone (total injected volume: 1 μ l). A total of 158 mice were injected. Ninety-one survived and were available for study.

Histological Procedures

At various times after infection [on days 2, 4, 7, 9, 14, 21, 28, 35, 43, 60, 78, 90, 100, and 130 post infection (p.i.)], mice were anesthetized with ether and perfused through the left ventricle with either formaldehyde (4% w/v in phosphate buffer) for opto-microscopic studies, or formaldehyde (2% w/v in phosphate buffer) plus glutaraldehyde (2.5% v/v) for electron-microscopic studies. The whole cranium was fixed overnight. The brain was then removed, embedded in paraffin, and sliced coronally on a serial basis for the preparation of paraffin sections which were processed by conventional techniques. In a series of mice prepared for electron-microscopic studies, selected fragments of ependyma, white matter, cortex and brain stem were obtained, postfixed in 1% OsO₄, and embedded in epoxy resin. Semithin sections were stained with toluidine blue or with the PAS method. Thin sections were stained with uranyl acetate and lead citrate and examined using a Philips EM 300 electron microscope.

Immunomodulating Treatments

Cyclophosphamide Treatment. Cyclophosphamide was reconstituted with saline buffer and a freshly prepared solution was injected i.p. at a dose of 150 mg/kg. Cyclophosphamide treatment, in semisusceptible BAF 1 mice, given either before or just after MHV 3 infection, leads to 100% mortality (Willenborg et al. 1973). To avoid acute mortality, cyclophosphamide was injected on days 7, 10, 14 p.i. or 10 and 14 p.i. In some experiments, A/J strain mice were injected with cyclophosphamide 9, 13, and/or 17 days before infection.

⁸⁹Strontium Treatment. 100 μ Ci of ⁸⁹strontium (⁸⁹Sr) were injected i.p. in BAF 1 mice on two separate occasions, 5 weeks apart. Six weeks after the last injection, animals were considered "⁸⁹Sr-treated", as described previously (Tardieu et al. 1980). MHV 3 was injected 5 weeks after the second injection.

Results

Neuropathological Analysis of MHV 3-induced Disease in Semisusceptible Mice

After infection, 54 (62%) of the semisusceptible mice (BAF 1, CH 3) survived and developed a progressive neurologic disease characterized by incoordination, paresis of the hind limbs, enlargement of the head, and progressive neurologic deterioration leading to death within 3–5 months. In this group of animals, no neuropathologic changes could be detected when examined on days 2 and 4 p.i. The first abnormalities, at 7 days p.i., consisted of an important meningeal in-

filtration of polymorphonuclear and mononuclear cells. At 14 days p.i., the infiltrate consisted of small lymphocytes, plasmocytes, and macrophages.

After 21 days p.i., the diffuse meningeal infiltrate diminished progressively and was minimal after 60 days p.i. During the same period inflammatory cuffing of meningeal vessels became progressively more marked. Perivascular inflammatory cells consisted of small lymphocytes, plasmocytes, and macrophages.

Between 7 and 14 days p.i. perivascular infiltrations of mononuclear cells and microglial nodules appeared in the hemispheric white matter (Fig. 1a). In rare instances, a microglial nodule was observed in the adjacent cortex. At 21 days the inflammatory lesions in the white matter had disappeared, leaving widespread destruction and cavitation (Fig. 1b).

At 10 days p.i., the first signs of an ependymitis appeared. Between 21 and 35 days p.i. the granular ependymitis was particularly marked. Inflammatory lesions predominated in the fourth ventricle and aqueduct (Fig. 2a). Focal aggregates of inflammatory cells consisting of mononuclear cells were formed beneath the ependyma and the ependymal cell line was focally disrupted. Some of these granulomas bulged into the ventricular lumen and became even detached to form rosettes which were found free in the CSF or were attached to the cilia of the ependymal cells. Under the electron microscope, these granulomatous buds were seen to consist of lymphocytes and histio-monocytes together with ependymocytes. No viral particles could be seen within the affected ependymal cells. The cells of the subependymal aggregates did not stain with an antiserum against GFAP, suggesting that they did not contain proliferating astrocytes. No changes were detected in the chroid plexus. After 35 days p.i., the ependymal lesions became progressively less active and demonstrated residual scarring. The ependymal cell line was focally disrupted, and in the posterior part of the fourth ventricle it was completely destroyed. Proliferation of subependymal atocytes was not conspicuous (Fig. 2b).

The first evidence of ventricle enlargement was noted at 21 days p.i. Hydrocephalus progressed throughout the life span of the animals. On serial sectioning of the aqueduct no stenosis was observed at 100 and 130 days p.i. In mice killed after 45 days p.i. vascular lesions were observed. Numerous meningeal arterioles showed severe alterations: hyaline necrosis of the media, fragmentation of the elastic lamina and intimal proliferation (Fig. 3). Some arterioles and capillaries were occluded by an inflammatory thrombus (Figs. 3, 4) consisting of plasmocytes, a few polymorphonuclear leukocytes, and necrotic cells of uncertain origin (Fig. 5). Between 60–130 days p.i. vasculitis and thrombosis were seen to affect intraparenchymal ves-

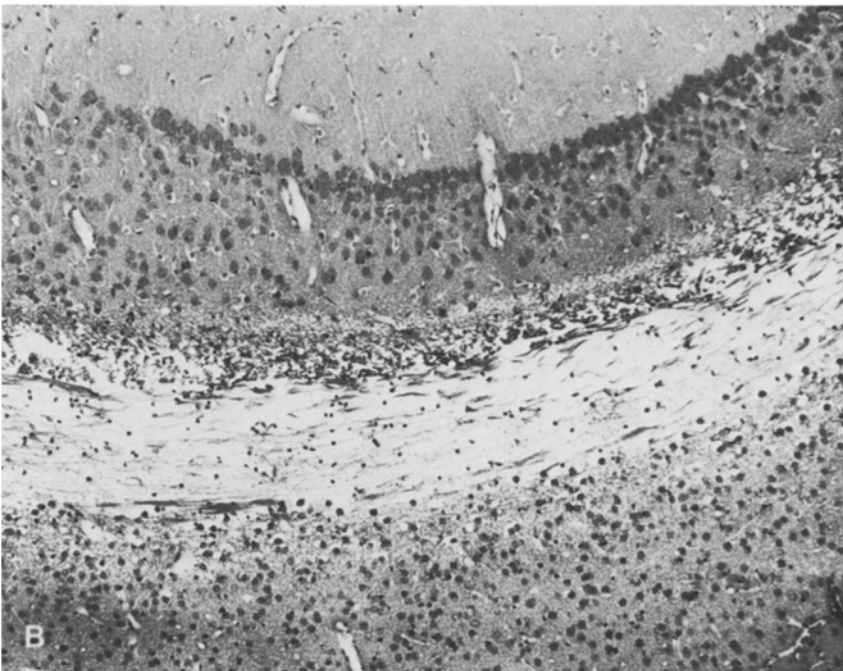
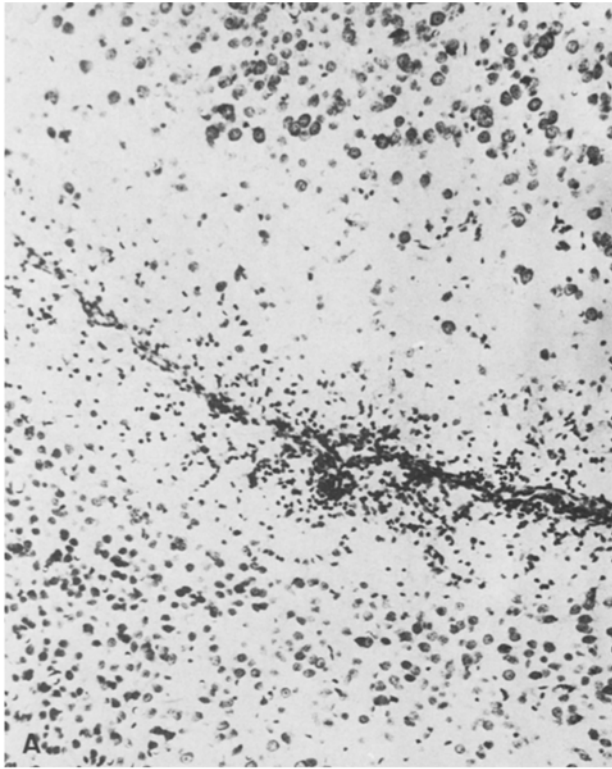


Fig. 1A, B. Inflammatory nodules in hemispheric white matter. Neocortex is situated below and subiculum above the central white matter. Fragments of ependyma are seen amidst the inflammatory cells. **A** 9 days p.i. Nissl, $\times 108$. **B** Widespread destruction of cerebral white matter, no inflammation; 21 days p.i. HE, $\times 94$

sels beneath the IV ventricle and in the dorsolateral part of the brain stem (Fig. 6). At some points, the nervous tissue surrounding these vessels showed distinct signs of ischemic necrosis, characterized by the presence of macrophages and proliferating astrocytes. Aggregates of inflammatory cells were seen around vessels and in

the surrounding parenchyma. No microglial nodules and no intranuclear inclusions were observed.

The infected semisusceptible mice which died acutely during week 1 showed lesions similar to those observed in fully susceptible mice, i.e., acute hepatitis with a normal appearance of the CNS.

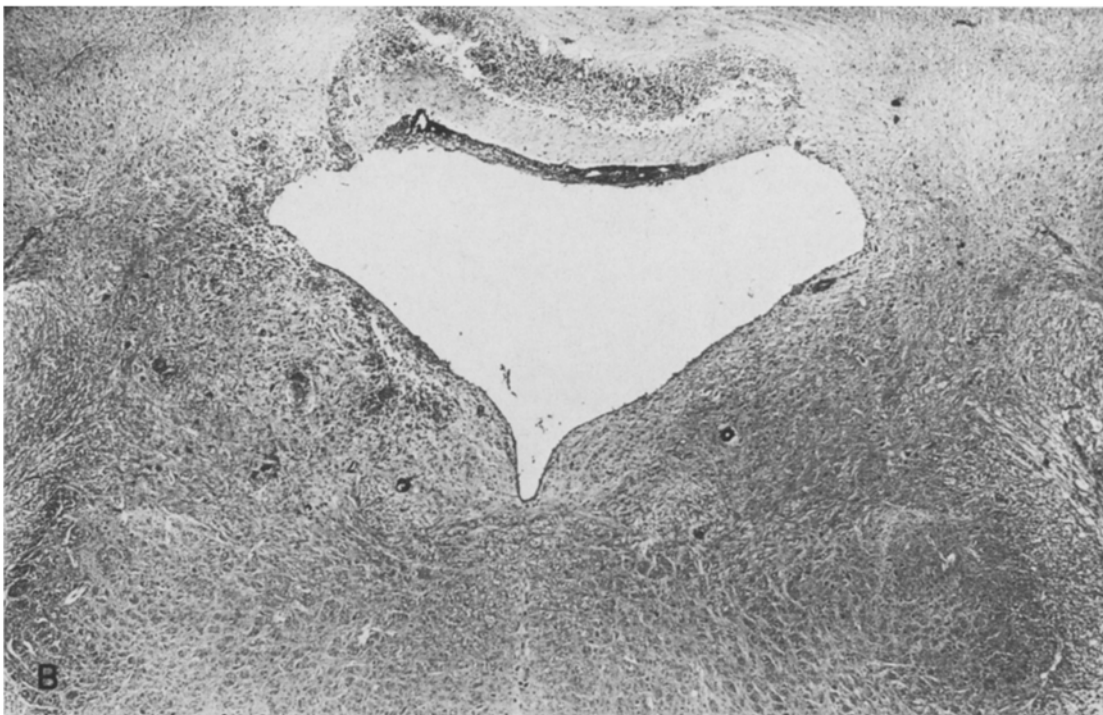
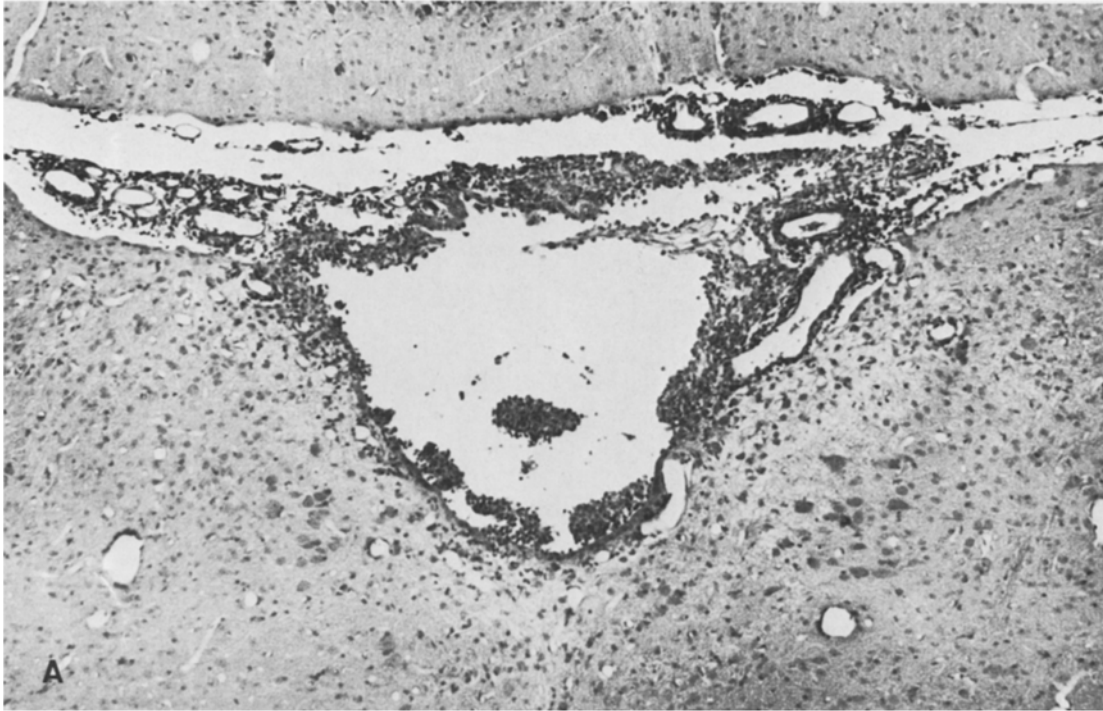

Fig. 2A, B. Ependymitis of the fourth ventricle; aggregates of inflammatory cells beneath the ependyma, attached to the ventricular wall or free in the ventricle. **A** 21 days p.i. HE, $\times 80$. **B** Enlarged fourth ventricle; the ependymal inflammation has subsided; widespread destruction of the ependymal lining. Subependymal inflammatory aggregates, mostly perivascular. 78 days p.i. HE, $\times 30$

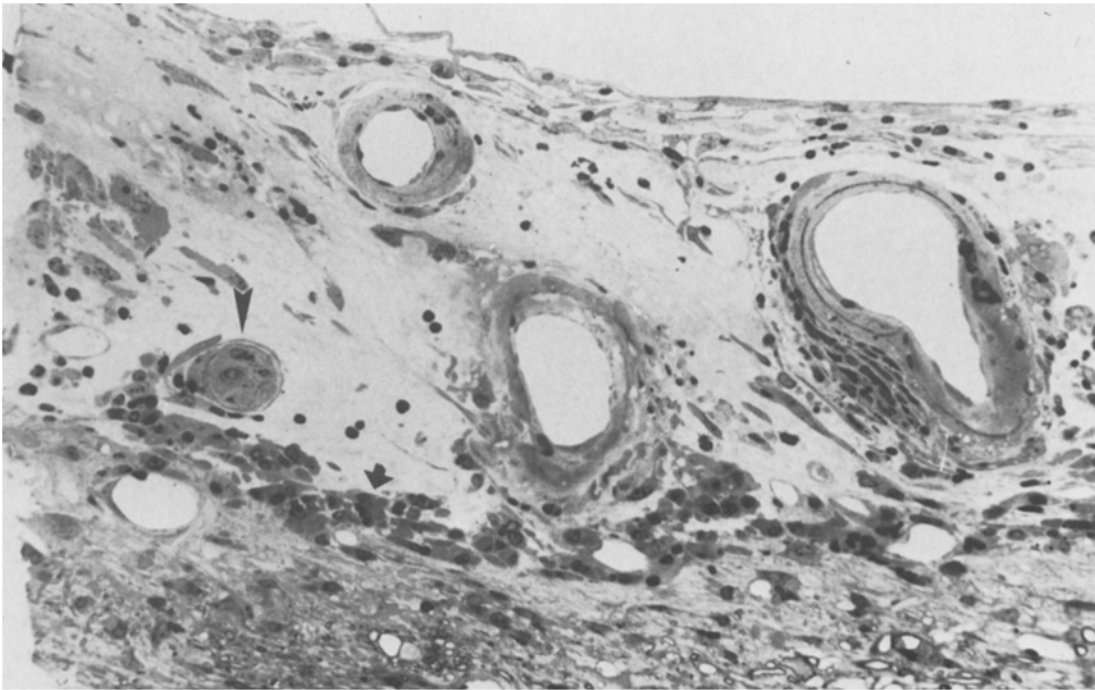


Fig. 3. In the leptomeninges three arteries show hyaline necrosis of vessel walls, fragmentation of elastic layer and intimal thickening. A capillary is occluded by a cellular thrombus (*arrowhead*). Infiltration of meninges by a few plasmacytes (*arrow*). 100 days p.i. Semithin section, toluidine blue, $\times 250$

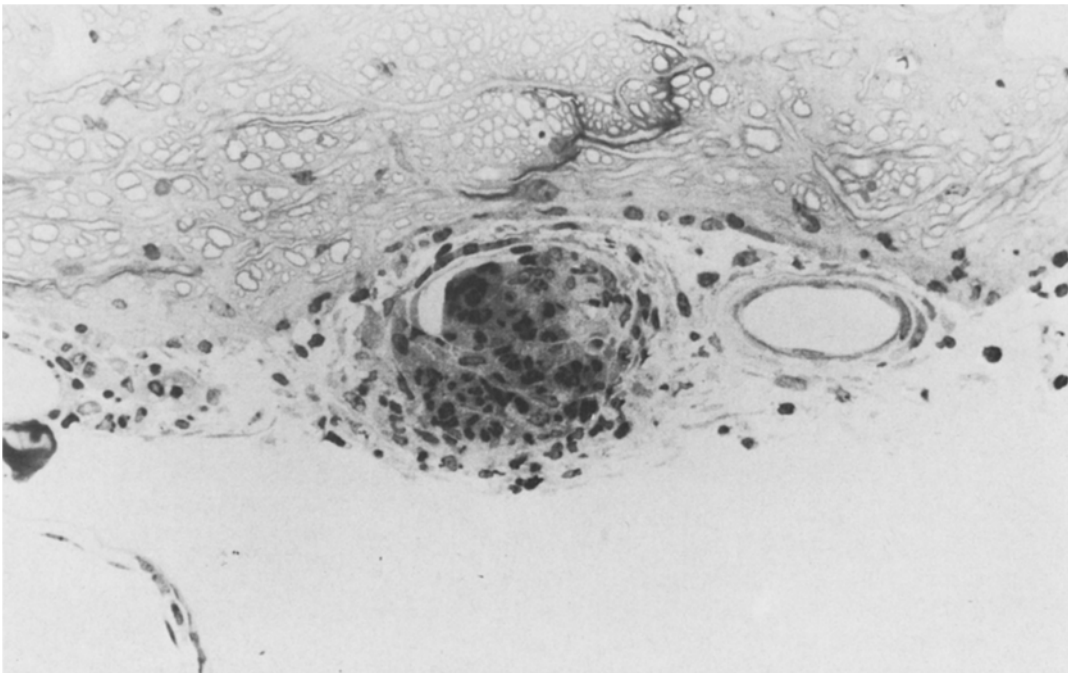


Fig. 4. Medulla. Inflammatory thrombus in a meningeal capillary, with partial recanalization. 43 days p.i. Semithin section, toluidine blue, $\times 250$

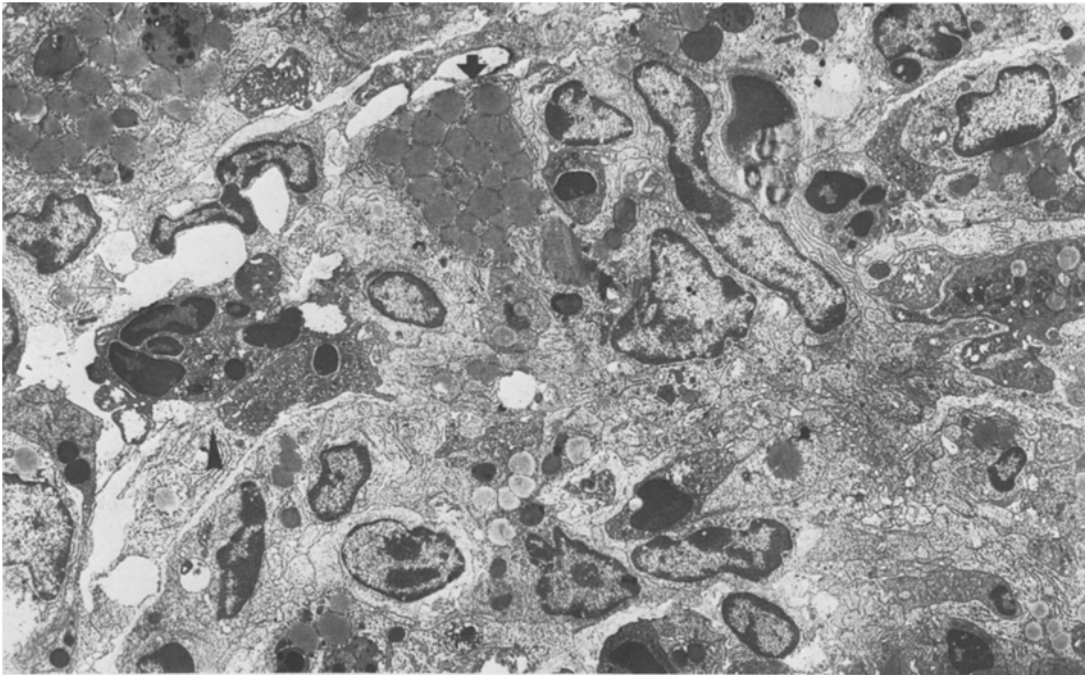


Fig. 5. Electron micrograph of thrombus of Fig. 4. Dense aggregate of plasmacytes, some with a dilated endoplasmic reticulum (*arrow*), polymorphonuclear leukocytes (*arrowhead*), and necrotic cells. $\times 4,000$

Effect of Cyclophosphamide and ^{89}Sr on Neuropathological Findings in Semisusceptible Mice

Cyclophosphamide Treatment. A group of 14 BAF1 mice were injected i.p. with MHV 3 (10^3 LD₅₀). Two died acutely and the 12 others were treated with cyclophosphamide as described in Material and Methods. Among the 12 infected and cyclophosphamide-treated mice, 10 survived and two died at 23 and 27 days p.i. Pathologically, the ependymal lesions and ventricular dilatation were identical to non-treated mice. Hyaline necrosis of the walls of meningeal arteries and thrombosis existed as in controls. In contrast, there was a marked diminution of the meningeal and perivascular inflammatory cell infiltration as compared to control mice which were infected by MHV 3 but were not treated with cyclophosphamide. There was no evidence of leukoencephalitis.

^{89}Sr Treatment. Treatment with ^{89}Sr resulted in acute liver necrosis with death between day 5 and 9 p.i. in the five semisusceptible mice tested. These mice showed a pattern of lesions similar to that observed in susceptible mice.

Neuropathologic Analysis of MHV 3 Infection in Susceptible and Resistant Mice

When six susceptible BALB/c mice were injected i.p. with MHV 3 (10^3 LD₅₀), they died of an acute hepatic

necrosis 5–8 days after MHV 3 infection, and no neuropathologic lesion was observed except a slight degree of meningeal infiltration. A group of 10 BALB/c mice was then infected with a low dose of virus (10 LD₅₀). Eight of these animals died acutely within 5–8 days, the other two survived. The neuropathologic lesions were identical to those observed in semisusceptible mice, i.e., meningitis, leukoencephalitis, ependymitis, ventricular dilatation, and vasculitis. If the dose of inoculated virus was further lowered (1 LD₅₀), neither acute nor chronic lesions developed in five injected animals.

To determine whether resistant mice could develop a chronic disease, three experiments were performed. First, three resistant A/J mice were injected in the same way as the semisusceptible animals. No clinical manifestations or neuropathologic abnormalities were observed. Secondly, 5 A/J strain mice were immunosuppressed with cyclophosphamide. After infection with MHV 3, the most profoundly immunosuppressed animals (two or three cyclophosphamide injections before MHV 3 infection) died acutely as previously shown (Willenborg et al. 1973); in the two surviving animals a slight meningeal infiltration and a perivascular infiltrate were observed on day 21 p.i. without any ependymal damage. In a third experimental group MHV 3 was injected directly into the brain of nine mice. Only minimal neuropathologic lesions were observed (a light microglial infiltration at the point of injection) without any ependymal or vascular change.

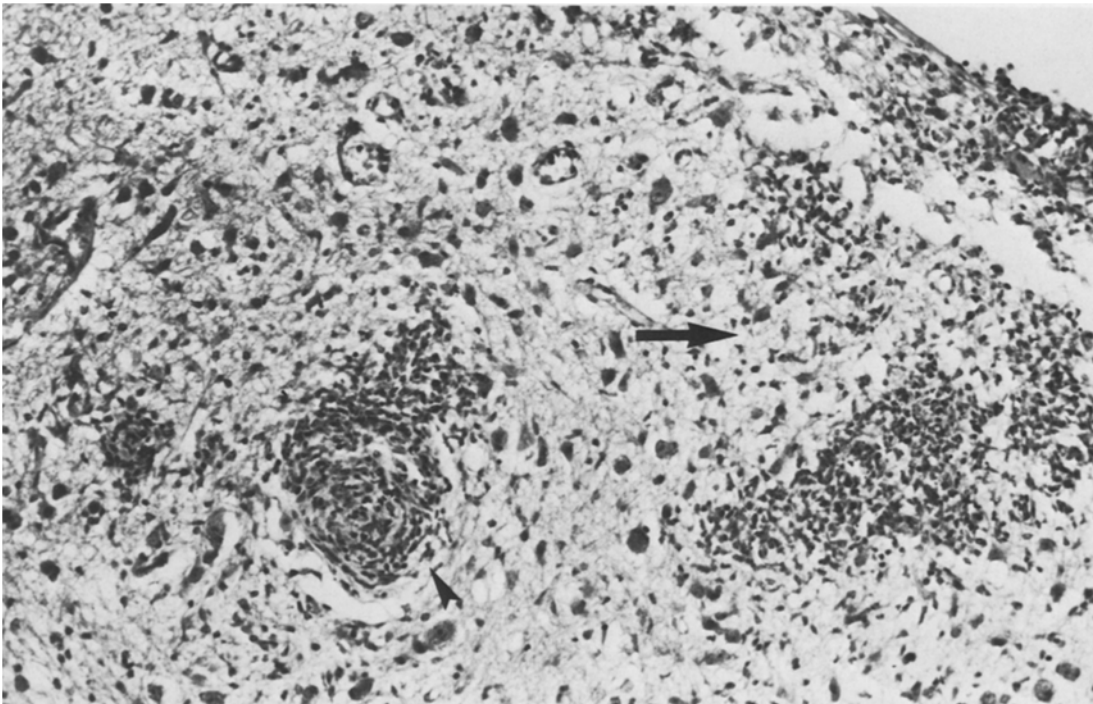


Fig. 6. Dorsolateral part of the pons. Occluded vessels (*arrowhead*) and focal aggregates of histiocytes in area of tissue necrosis (*arrow*). 78 days p.i. HE, $\times 200$

Discussion

Systemic infection of semisusceptible strains of mice with MHV 3 leads to a remarkable sequence of brain lesions, such as meningitis and leukoencephalitis to mention those appearing first. The diffuse meningeal infiltrate tends to disappear progressively within a few weeks without fibrotic changes. However, perivascular infiltrates remain, especially at the level of the brain stem.

The acute leukoencephalitis (Fig. 1a), which is more marked in C3H, is restricted to the central white matter of the cerebral hemisphere and is visible only during a limited period of time between days 7 and 14 p.i., leaving behind severe destructive lesions (Fig. 1b). This type of leukoencephalitis is different from white matter lesions produced by MHV 4, which consist of noninflammatory patchy demyelination (Waksman and Adams 1962; Lampert et al. 1973; Weiner 1973; Herndon et al. 1975; Haspel et al. 1978; Weiner and Stohlman 1978; Stohlman and Weiner 1981). The presence of glial nodules in the white matter and occasionally in the adjacent cortex, may be considered as an indication of a direct action of the virus on glial cells.

Inflammatory changes in the ependyma appeared approximately at day 14 and persisted for about 1 month (Fig. 2a). They resulted in widespread destruction of the ependymal lining (Fig. 2b). Viral particles were not

detected with the electron microscope in the ependymal cells, in contrast with the findings in other viral ependymitis (Nielsen and Baringer 1972; Wolinsky 1977).

Progressive hydrocephalus starting at about 3 weeks p.i. was probably a major factor in the death of the animals. Virus-induced experimental hydrocephalus has been attributed either to stenosis of the aqueduct produced by an ependymitis (Johnson et al. 1967; Johnson and Johnson 1968; Johnson 1975) or to a post infectious fibrosis of the meninges (Masters et al. 1977). In our animals aqueductal stenosis was not observed (at least until the 130th day p.i.), and there was no meningeal fibrosis (arachnoid villi were not examined). Immunosuppression of semisusceptible animals with cyclophosphamide did not prevent the appearance of hydrocephalus; its most remarkable effect was the nearly complete suppression of the meningeal infiltrate. Fibrosis of the meninges can, therefore, probably be discounted as the cause of intraventricular hypertension and the mechanism of hydrocephalus remains unsettled. However, the parallelism between the intensity of ependymitis and hydrocephalus should be noted: both abnormalities were more important in BAF 1 mice than in C3H mice.

In contrast to the early, self-limiting, inflammatory lesions observed in the cerebral white matter and ependyma, vasculitis appeared late, after ependymitis had subsided, and increased progressively throughout

the life of the animals. These remarkable lesions consisted in hyaline necrosis of vessel walls and thromboses (Figs. 3, 4). Plasmocytes were remarkably numerous in the inflammatory thrombi (Fig. 5). Perivascular cuffings with lymphocytes and plasmocytes were even more abundant than in the early phases of the disease. Arterioles, capillaries, and venules were affected, essentially in the meninges surrounding the pons and medulla, deep in the subependymal region of the IVth ventricle, and within the dorsolateral parts of the brain stem, where small foci of ischemic necrosis related to vascular occlusions were observed (Fig. 6). It is not impossible that some of the parenchymal lesions could be ascribed to an encephalitic process; however, the presence of vascular occlusions and ischemic necrosis in these areas is unquestionable.

In man, particularly in the fetus, the possibility for a chronic viral infection to induce ischemic brain lesions after a long delay, through a slowly progressive thrombotic vasculitis, has not been sufficiently considered. Such a sequence of events is known, however, in congenital rubella, where degeneration of vessel walls leads to multifocal ischemic necrosis of the brain (Rorke and Spiro 1967; Singer et al. 1967; Rorke 1973) and similar lesions have been shown in experimental animals (Rorke et al. 1968). A rare condition, granulomatous angiitis has been related to varicella-zoster infection (Kolodny et al. 1968; Rosenblum and Hodfield 1972; Linnemann and Alvira 1980) and to other viral infections (Reyes et al. 1976) in man. Also, it is known that inflammatory perivascular infiltrates persist for many months in human poliomyelitis (Esiri 1980).

At the time vascular lesions develop, a low titer of virus can still be detected in the brain, as late as 6 months p.i. (Le Prevost et al. 1975b), and Dupuy et al. (1973) have demonstrated at that stage a severe non specific immunodepression (Dupuy et al. 1973). To investigate possible immune mediation in the generation of vascular lesions, we studied the effects of two immunomodulating regimen in semisusceptible mice: cyclophosphamide, which depresses T- and B-cell activities (Stockman et al. 1973) and ^{89}Sr , which abolishes selectively NK cell activity (Kumar et al. 1976; Tardieu et al. 1980). Cyclophosphamide did not prevent necrosis of vessel walls and thrombosis. ^{89}Sr treatment changed the pattern from semisusceptible to susceptible mice, dying of acute hepatic necrosis. To study further the effect of ^{89}Sr , preliminary experiments were performed in which mice were injected with MHV 3 1 day after the second injection of ^{89}Sr , to avoid acute hepatic necrosis. The intensity of vasculitis in these mice and in controls was identical. These experiments suggest that T, B, and NK-cells do not play a prominent

role in the induction of vascular lesions. However, there is as yet no clear evidence in favor of a direct action of the virus on the vessels, and further research is needed into the pathogenesis of the thrombotic vasculitis following MHV 3 infection.

The same neurologic disease can occur in fully susceptible mice infected with a low dose of virus, but attempts to induce this disease in genetically resistant mice have been unsuccessful, even following immunosuppression or intracranial inoculation. These findings suggest that host cells in the brain from fully susceptible and semisusceptible strains are equally able to support viral replication and are equally susceptible to give rise to destructive lesions. The absence of disease in resistant mice may be related to an inability of host cells to either bind or replicate MHV 3. It is also possible that other means of immunosuppression may alter this genetic resistance.

References

- Allison AC (1965) Genetic factors in resistance against virus infection. *Arch Gesamte Virusforsch* 17:280–293
- Dupuy JM, Le Prevost C, Levy-Leblond E, Virelizier J (1973) Persistent virus infection with neurological involvement in mice infected with MHV 3. *Fed Proc* 32:4179–4187
- Dupuy JM, Levy-Leblond E, Le Prevost C (1975) Immunopathology of mouse hepatitis virus type 3 infection. II. Effect of immunosuppression in resistant mice. *J Immunol* 114:226–230
- Esiri MM (1980) Poliomyelitis: immunoglobulin-containing cells in the central nervous system in acute and convalescent phases of the human disease. *Clin Exp Immunol* 40:42–48
- Haspel MV, Lampert PW, Oldstone MBA (1978) Temperature-sensitive mutants of mouse hepatitis virus produce a high incidence of demyelination. *Proc Natl Acad Sci* 15:4033–4036
- Herndon RM, Griffin DE, Melormick U, Weiner LP (1975) MHV-induced recurrent demyelination. A preliminary report. *Arch Neurol* 32:32–35
- Hirsch MS, Zisman B, Allison AC (1970) Macrophages and age-dependent resistance to herpes simplex virus in mice. *J Immunol* 104:1160–1165
- Johnson RT (1964) The pathogenesis of herpes virus encephalitis. I. Virus pathways to the nervous system of suckling mice demonstrated by fluorescent antibody staining. *J Exp Med* 119:343–358
- Johnson RT, Johnson KP, Edmonds CJ (1967) Virus induced hydrocephalus: development of aqueductal stenosis in hamster after mumps infection. *Science* 157:1066–1067
- Johnson RT, Johnson KP (1968) Hydrocephalus following viral infections: the pathology of aqueductal stenosis developing after experimental mumps virus infection. *J Neuropathol Exp Neurol* 27:591–603
- Johnson RT (1975) Hydrocephalus and viral infections. *Develop Med Child Neurol* 17:807–816
- Kolodny EH, Rebeiz JJ, Caviness VS, Richardson EP (1968) Granulomatous angiitis of the central nervous system. *Arch Neurol* 19:510–524
- Kumar V, Bennett M, Eckner RJ (1976) Mechanism of genetic resistance to Friend leukemia virus in mice. I. Role of ^{89}Sr -sensitive effector cells responsible for rejection of bone marrow allografts. *J Exp Med* 139:1093–1109

- Lampert PW, Sims JK, Kniazeff AJ (1973) Mechanism of demyelination in JHM virus encephalomyelitis. Electron-microscopic studies. *Acta Neuropathol (Berl)* 24:76–85
- Le Prevost C, Levy-Leblond E, Virelizier JL, Dupuy JM (1975a) Immunopathology of mouse hepatitis virus type 3 infection. I. Role of humoral and cell-mediated immunity in resistance mechanisms. *J Immunol* 114:221–225
- Le Prevost C, Virelizier JL, Dupuy JM (1975b) Immunopathology of mouse hepatitis virus type 3 infection. III. Clinical and virologic observations of a persistent viral infection. *J Immunol* 115:640–643
- Levy-Leblond E, Oth D, Dupuy JM (1979) Genetic study of mouse sensitivity to HMV 3 infection: influence of the H-2 complex. *J Immunol* 122:1359–1362
- Linnemann CC, Alvira MM (1980) Pathogenesis of varicella-zoster angitis in the CNS. *Arch Neurol* 37:239–240
- Masters C, Alpers M, Kakulas B (1977) Pathogenesis of reovirus type I hydrocephalus in mice. Significance of aqueductal change. *Arch Neurol* 34:18–28
- Nielsen SL, Baringer JR (1972) Reovirus-induced aqueductal stenosis in hamsters. Phase contrast and electron-microscopic studies. *Lab Invest* 27:531–537
- Reyes MG, Fresco R, Chokroverty S, Salud EQ (1976) Virus-like particles in granulomatous angitis of the central nervous system. *Neurology* 26:797–799
- Rorke LB, Spiro AJ (1967) Cerebral lesions in congenital rubella syndrome. *J Pediatr* 70:243–255
- Rorke LB, Fabiyi A, Elizan TS, Sever JL (1968) Experimental cerebrovascular lesions in congenital and neonatal rubella-virus infections of ferrets. *Lancet* 1:153–154
- Rorke LB (1973) Nervous system lesions in the congenital rubella syndrome. *Arch Otolaryngol* 98:249–251
- Rosenblum WI, Hodfield MG (1972) Granulomatous angitis of the nervous system in cases of herpes zoster and lymphosarcoma. *Neurology* 22:348–354
- Singer DB, Rudolph PJ, Rosenberg HS, Rawls WF, Boniuk M (1967) Pathology of the congenital rubella syndrome. *J Pediatr* 71:665–675
- Stockman GD, Heim LR, South MA, Trentin JJ (1973) Differential effects of cyclophosphamide on the B- and T-cell compartments of adult mice. *J Immunol* 110:277–282
- Stohlman SA, Weiner LP (1981) Chronic central nervous system demyelination in mice after JHM virus infection. *Neurology* 31:38–44
- Tardieu M, Hery C, Dupuy JM (1980) Neonatal susceptibility to MHV 3 infection in mice. II. Role of natural effector marrow cells in transfer of resistance. *J Immunol* 124:418–423
- Virelizier JL, Dayan AD, Allison AC (1975) Neuropathological effects of persistent infection of mice by mouse hepatitis virus. *Infect Immun* 12:1127–1140
- Waksman BH, Adams RD (1962) Infectious leukoencephalitis. A critical comparison of certain experimental and naturally-occurring viral leukoencephalitis with experimental allergic encephalomyelitis. *J Neuropathol Exp Neurol* 21:491–518
- Weiner LP (1973) Pathogenesis of demyelination induced by a mouse hepatitis virus (JHM virus). *Arch Neurol* 28:298–303
- Weiner HL, Drayna D, Averill DR, Fields BN (1977) Molecular basis of reovirus virulence: role of the S 1 gene. *Proc Natl Acad Sci (USA)* 74:5744–5748
- Weiner LP, Stohlman SA (1978) Viral models of demyelination. *Neurology* 28:111–114
- Willenborg DO, Shah KV, Bang FB (1973) Effect of cyclophosphamide on the genetic resistance of C₃H mice to mouse hepatitis virus. *Proc Soc Exp Biol Med* 142:762–766
- Wolinsky JS (1977) Mumps virus-induced hydrocephalus in hamsters. Ultrastructure of the chronic infection. *Lab Invest* 37:229–236
- Wolinsky JS, Stroop WG (1978) Virulence and persistence of three prototype strains of mumps virus in newborn hamster. *Arch Virol* 57:355–359

Received July 12, 1982/Accepted September 14, 1982