

Case report

Incarceration of the hepatic lobe in incisional hernia: A case report



Huseyin Eken^{a,*}, Arda Isik^a, Sercan Buyukakincak^b, Ismayil Yilmaz^a, Deniz Firat^a, Orhan Cimen^a

^a Department of General Surgery, Erzincan University, Erzincan, Turkey

^b Department of General Surgery, Hackalibaba State Hospital, Trabzon, Turkey

HIGHLIGHTS

- Incisional hernias are common type of hernia.
- Left liver lobe may be incarcerated into the hernia sac.
- Surgeon should be careful not to damage it.

ARTICLE INFO

Article history:

Received 4 March 2015
Received in revised form
14 April 2015
Accepted 31 May 2015

Keywords:

Incisional hernia
Liver incarceration
Abdominal wall

ABSTRACT

Introduction: Incisional hernias are abnormal peritoneal outward pouch-like protrusions that develop due to defects that arise as a result of the disruption of the fascia's continuity after abdominal surgery. **Presentation of case:** A 77-year-old female patient presented to the emergency department of our hospital with complaints of abdominal swelling, abdominal pain, nausea and vomiting. The patient was recommended for surgery. It was decided that the primary fascia closure and onlay patch was the most appropriate approach.

Discussion: When the defect in the abdominal wall grows, the functionality of the related abdominal wall is disrupted thereby eliminating the dynamic structure of the abdominal wall. Incisional hernias lead to a significant number of job losses and morbidity and negatively affect quality of life. Moreover, the formations in the hernia pouch might lead to higher risk of strangulation and dysfunction.

Conclusion: Subcutaneous herniation of the left lobe of the liver passing through the abdominal wall is a very rare condition.

© 2015 The Authors. Published by Elsevier Ltd on behalf of IJS Publishing Group Limited. This is an open access article under the CC BY-NC-ND license (<http://creativecommons.org/licenses/by-nc-nd/4.0/>).

1. Introduction

Incisional hernias are abnormal peritoneal outward pouch-like protrusions that develop due to defects that arise as a result of the disruption of the fascia's continuity after abdominal surgery. Incisional hernias are one of the common problems seen after the abdominal surgery with incidence rates ranging from 2 to 11% according to different sources(3). Abdominal surgery related incisional hernias leads to significant job loss and morbidity, as well as negatively affecting quality of life. Therefore, due to high prevalence and morbidity, incisional hernias continue to be one of the most important complications of abdominal surgery. Subcutaneous herniation of the left lobe of the liver passing through the

abdominal wall is a very rare condition and there is only one case in the literature [1]. In this case report, we present a case of incarcerated incisional hernia that involves the left liver lobe and associated acute liver failure. The aim of this study is to show that hernia sac may contain solid organs.

2. Case report

A 77-year-old female patient presented to the emergency department of our hospital with complaints of abdominal swelling, abdominal pain, nausea and vomiting. The patient's medical history revealed that 15 years ago she underwent two surgeries due to gastric perforation and umbilical hernia and has been diagnosed with hypertension for 10 years.

The physical examination showed a median incision scar above and below the abdomen and a palpable lump in the upper part of this incision. The liver was palpated in this herniated region; the

* Corresponding author.

E-mail address: huseyineken80@hotmail.com (H. Eken).

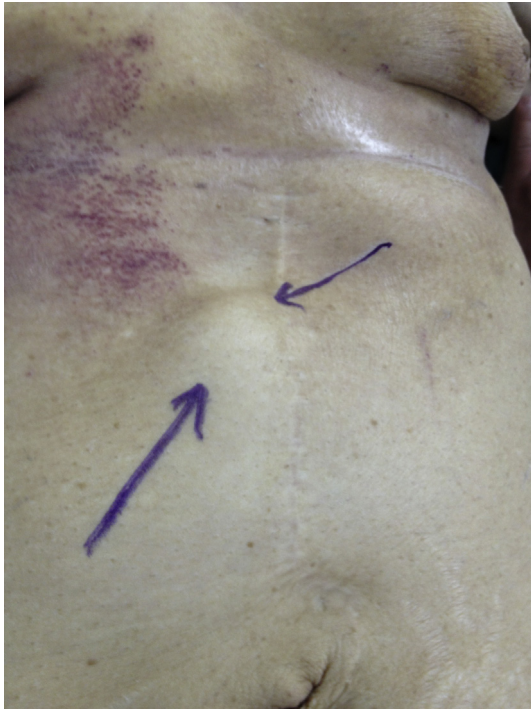


Fig. 1. Preoperative view.

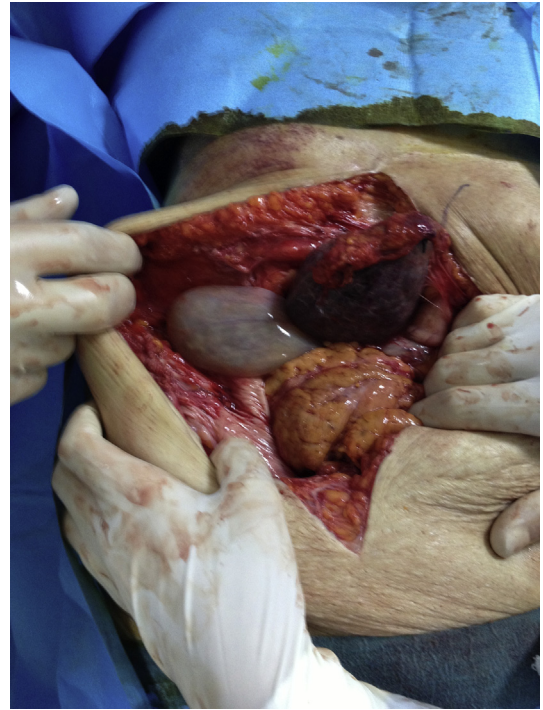

Fig. 3. Intraoperative view.

skin was thinner and there was sensitivity in this region (Fig. 1). There was no rebound pain or guarding. Bowel sounds were normoactive. The patient was lethargic and had a decreased response to stimuli. The neurological examination revealed a flapping tremor and stage 2 encephalopathy. Laboratory test results were as follows: hemoglobin (Hb): 13.8 g/dl, hematocrit (htc): 40, leukocytes: 17000/mm³, glucose: 120 mg/dl, blood urea nitrogen (BUN): 20 mg dl, creatinine: 0.9 mg/dl, aspartate aminotransferase (AST): 225 U/ml, alanine aminotransferase (ALT): 288/ml, amylase: 77 U/ml, Alkaline phosphatase: 75 IU/l, international normalized ratio (INR): 1.6, and total bilirubin: 3 mg/dl.

The patient underwent abdominal computed tomography (CT), which showed a fascial defect of 8.5 cm in diameter in the area of

the incision. The left lobe of the liver and an intestinal segment was observed inside this fascial defect (Fig. 2).

The patient was recommended for surgery. It was decided that the primary fascia closure and online patch was the most appropriate approach.

The complaints of patient and biochemical parameters of hepatic markers regressed after the surgery. She had discharged from the hospital on 7th postoperative day. She will be followed up at 1 and 6th months of discharge.

2.1. Surgical technique

The abdomen was entered through an old incision site. The left

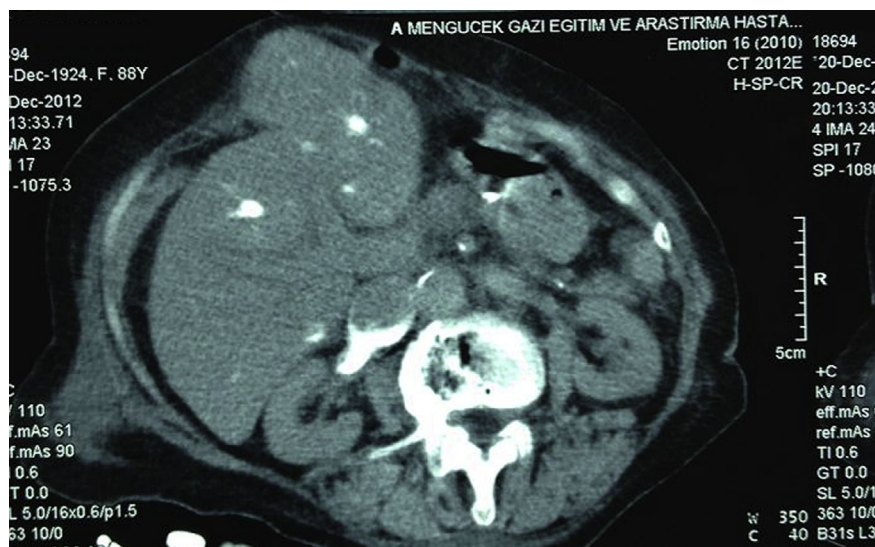

Fig. 2. ct of patient.

lobe of the liver that was incarcerated (Fig. 3) was returned to the abdomen. The tissue under the skin was detached and the edges of the fascia were exposed. The primary fascia closure was performed and an approximately 20 × 25 cm patch was placed on the fascia (Fig. 4). The hemovac drain was placed on the mesh and subcutaneous tissue and skin tissue were appropriately closed.

3. Discussion

Incisional hernias are abnormal peritoneal outward pouch-like protrusions that develop due to defects that arise as a result of the disruption of the fascia's continuity after abdominal surgery. The incidence of incisional hernias following an abdominal surgery has been reported to be 10% [2]. Etiological factors in the development of incisional hernias can be classified into controllable and uncontrollable. Controllable etiologic factors include: obesity, shape of incision, suture material used and wound infection. On the other hand, uncontrollable etiologic factors include: the patient's age, general body weakness and other chronic diseases [3–5]. The patient presented in this case report was elderly and obese and had a chronic disease. Basic principles of a good incision as indicated by Maingot are easy accessibility, expandability and reliability. Despite being more time consuming and having higher bleeding tendency, transverse incisions have lesser risk of incisional hernia compared to the vertical incisions [6]. This risk factor was present in our patient.

We decided to take an abdominal CT scan to appropriately determine the hernia's contents and because the patient's liver function tests were elevated. Ghahremani et al. [7] also reported using CT to determine the hernia's location, size and content in all of their patients with incisional hernia.

A small number of cases of incisional hernia containing liver segments have been reported [8,9]. Protrusion can be seen in cases where the liver grows diffusely or with space-occupying lesions. In chronic cases conservative treatment options may be effective but as in our case as the patient has acute abdomen, we had to operate the patient(1). In the operation as the left liver lobe may be under the skin, the skin was gently cutted not to cause damage to the liver and the liver lobe was enrolled with hot sponge for 5 min to increase vitality.

Acute liver failure is a clinical condition characterized by coagulopathy and encephalopathy and is associated with rapid deterioration of liver enzymes. The presence and stage of encephalopathy is the most important prognostic factor [10,11].

Elevated liver enzymes are associated with hepatic necrosis. As acute liver failure progresses, the INR is prolonged, bilirubin is elevated and encephalopathy progresses. Despite the advanced treatment systems the mortality associated with acute liver failure can be up to 80% [12]. In our case, the INR was >1.5 and stage two encephalopathy was detected; therefore we followed the patient postoperatively for signs of fulminant hepatic failure.

3.1. Conclusion

In this case report, we presented a rare case of the subcutaneous protrusion of the left liver lobe's medial segment through the fascial defect in the incisional hernia. The protruded liver had

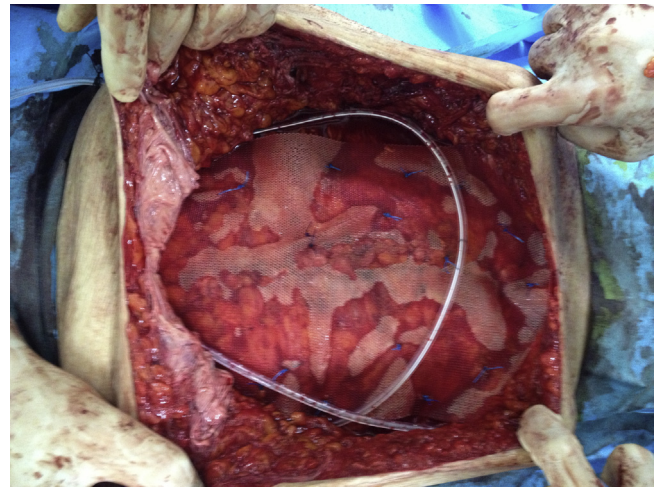


Fig. 4. Intraoperative view.

created painful symptoms on the incisional hernia. We suggest that when performing operations on incisional hernias it should be kept in mind that the left liver lobe may be under the skin and therefore one should be careful not to damage it. Moreover, we believe that a multidisciplinary approach such as radiology, vascular surgery and hematology required in the postoperative period in such cases.

Conflict of interest

There is no conflict of interest.

References

- [1] I. Abci, Z. Karabulut, H. Lakadamyali, H.O. Eldem, Incarceration of the left hepatic lobe in incisional hernia: a case report, *Ulus. Travma Acil Cerrahi Derg.* 11 (2005) 169–171.
- [2] J.E. Skandalakis, G.L. Colborn, T.A. Weidman, et al., *Skandalakis' Surgical Anatomy*, Mc Graw-Hill, New York, 2004. Bölüm 9.
- [3] Sayek İ.S. Baskı, *Bariş Tıp kitapevi*, Ankara, 2004, p. 1518.
- [4] Elie Yahchouchy Chouillard, Tamer Aura, Olivier Picone, Jean-Charles Etienne, *Abe Fingerhut Incisional Hernias I. Related Risk Factors*, vol. 1, Digestive Surgery Department, Centre Hospitalier Intercommunal, Poissy, France, 2003.
- [5] A. İşik, Y. Deniz Firat, K. Peker, I. Sayar, O. İdiz, M. Soyuturk, I. Demiryılmaz, I. Yılmaz, How could such a wide piece of tree root pass through the narrow pyloric orifice? An extremely rare case, *Am. J. Case Rep.* 15 (2014) 284–287.
- [6] R. Pollak, L. Nyhus, Herniler, in: *Maingot's Abdominal Operasyonlar*, Nobel Tıp Kitabevi, İstanbul, 1989, p. 247.
- [7] G.G. Ghahremani, M.A. Jimenez, M. Rosenfeld, et al., CT diagnosis of occult incisional hernias, *AJR Am. J. Roentgenol.* 148 (1) (1987) 139–142.
- [8] J.C. Neel, P.A. Mousseau, J. Leborgne, et al., Abdominal intercostal hernia. Report of four cases, *Sem. Hop.* 54 (21–24) (1978) 743–746.
- [9] T. Centorino, A. Ciccolo, A. Versaci, et al., Intercostal incisional hernia: case report, *G. Chir.* 19 (11–12) (1998) 445–447.
- [10] J.G. O'Grady, G.J. Alexander, K.M. Hayllar, R. Williams, Early indicators of prognosis in fulminant hepatic failure, *Gastroenterology* 97 (1989) 439–445.
- [11] D. Gotthardt, Fulminant hepatic failure: etiology and indications for liver transplantation, *Nephrol. Dial. Transpl.* 22 (Suppl. 8) (2007) viii5–viii8, <http://dx.doi.org/10.1093/ndt/gfm650>.
- [12] G. Ostapowicz, R.J. Fontana, F.V. Schioldt, et al., Results of a prospective study of acute liver failure at 17 tertiary care centers in the United States, *Ann. Intern. Med.* 137 (2002) 947–954.