


A case of lupus erythematosus profundus with severe ulceration that responded to tumor necrosis factor-alpha--blocking agents

Daiki Nakagomi^{1,2} 

¹Department of Rheumatology, University of Yamanashi Hospital, Yamanashi, Japan

²Department of Rheumatology, Shimoshizu Hospital, National Hospital Organization, Chiba, Japan

A 61-year-old woman developed a malar rash, arthritis, and nephrotic syndrome 40 years ago. At that time, although renal biopsy was not performed, she was positive for anti-double-stranded deoxyribonucleic acid (anti-dsDNA) antibodies and anti-nuclear antibodies (ANA) and, therefore, she was eventually diagnosed with systemic lupus erythematosus (SLE). She was treated with 80 mg/day of prednisolone monotherapy. As SLE became less active, the dosage of prednisolone was tapered to 12.5 mg every other day. When the patient reached 59-year-old, she developed atrophic and scaly erythema on her lower legs, and she was clinically diagnosed with discoid lupus erythematosus (DLE). Two years later, scaly erythema eventually progressed to severe ulcerations (Figure 1a). Aside from these, there were no other significant physical findings. The patient did not have cytopenia or hypocomplementemia. C-reactive protein and urinalysis results were also normal. At this point, she was negative for ANA, anti-dsDNA antibodies, and any other antibody profiles, including anti-scleroderma-70 and anti-phospholipid antibodies. Based on a published article of lupus erythematosus

profundus (LEP) in patients with DLE1 and the fact that this condition led to cutaneous atrophy and ulceration, a diagnosis of LEP with severe ulceration was made. Therefore, the patient received prednisolone at a dose of 40 mg/day and tacrolimus at a dose of 3 mg/day. However, the ulcers were refractory to treatment, despite treatment adherence for two months. Accordingly, we added etanercept at a dose of 50 mg/week. One week after the first subcutaneous injection of etanercept, ulcerations showed onset of granulation and epithelialization. After two months, ulcerations completely epithelialized leaving behind an atrophic scar (Figure 1b). At this point, we tapered the dose of prednisolone to 5 mg, while continuing etanercept. For almost two years now, the recurrence of LEP and DLE has not occurred. Moreover, the patient has no infections currently.

This is the first case of LEP with severe ulcerations that responded well to etanercept. Lupus erythematosus profundus occurs in 2 to 5% of patients with DLE or SLE. In addition, ulceration has been reported to occur in 6 to 28% of

Received: April 22, 2021 **Accepted:** September 03, 2021 **Published online:** December 24, 2021

Correspondence: Daiki Nakagomi, MD, PhD. Department of Rheumatology, University of Yamanashi, 409-3898 Yamanashi, Japan.
Tel: +81-55-273-1111 e-mail: dnakagomi@hotmail.co.jp

Citation:

Nakagomi D. A case of lupus erythematosus profundus with severe ulceration that responded to tumor necrosis factor-alpha--blocking agents. Arch Rheumatol 2022;37(2):313-314.

©2022 Turkish League Against Rheumatism. All rights reserved.

This is an open access article under the terms of the Creative Commons Attribution-NonCommercial License, which permits use, distribution and reproduction in any medium, provided the original work is properly cited and is not used for commercial purposes (<http://creativecommons.org/licenses/by-nc/4.0/>).

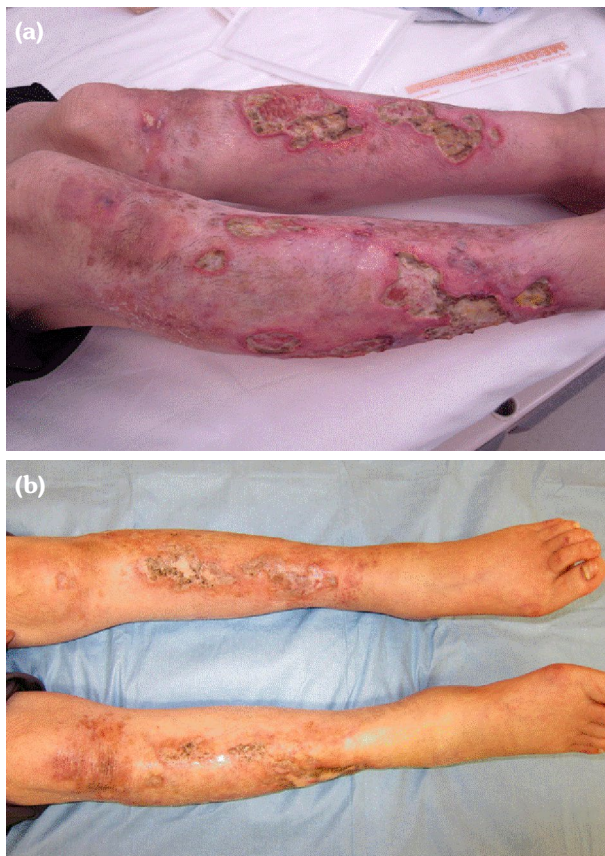

Figure 1. (a) Deep ulcerations dominated on lower leg. (b) An atrophic scar after therapy with etanercept.

patients with LEP.^{1,2} Recently, reports have shown that LEP-related ulcerations can be controlled with cyclosporine or tacrolimus.³ However, this patient did not respond to tacrolimus. Regarding tumor necrosis factor-alpha (TNF- α) blockade, a report showed that LEP could be controlled with infliximab⁴ and that TNF- α -blocking therapy was potentially useful in SLE treatment.⁵ In SLE, keratinocytes are regarded as a major source of TNF- α .⁶ High levels of TNF- α lead to the activation of B, T, and dendritic cells, promoting inflammation. Moreover, excessive TNF- α expression delays wound healing due to α -smooth muscle actin expression suppression.⁷

The level of TNF- α is high in the serum and skin lesions of patients with SLE; hence, TNF- α blockade averts these mechanisms and explains the effectiveness of etanercept. In conclusion, TNF- α inhibitors are likely efficacious in patients with severe cutaneous lupus erythematosus.

Patient Consent for Publication: A written informed consent was obtained from the patient for the publication of this case report.

Data Sharing Statement: The data that support the findings of this study are available from the corresponding author upon reasonable request.

Conflict of Interest: The author declared no conflicts of interest with respect to the authorship and/or publication of this article.

Funding: The author received no financial support for the research and/or authorship of this article.

REFERENCES

1. Callen JP. Management of skin disease in patients with lupus erythematosus. *Best Pract Res Clin Rheumatol* 2002;16:245-64.
2. Arai S, Katsuoka K. Clinical entity of Lupus erythematosus panniculitis/lupus erythematosus profundus. *Autoimmun Rev* 2009;8:449-52.
3. Ueda T, Eto H, Katsuoka K, Takeuchi Y. Lupus erythematosus panniculitis treated with tacrolimus. *Eur J Dermatol* 2012;22:260-1.
4. Günther C, Aringer M, Lochno M, Kämmerer E, Bauer A, Wozel G, et al. TNF-alpha blockade with infliximab in a patient with lupus erythematosus profundus. *Acta Derm Venereol* 2012;92:401-3.
5. Aringer M, Graninger WB, Steiner G, Smolen JS. Safety and efficacy of tumor necrosis factor alpha blockade in systemic lupus erythematosus: An open-label study. *Arthritis Rheum* 2004;50:3161-9.
6. Yu C, Chang C, Zhang J. Immunologic and genetic considerations of cutaneous lupus erythematosus: A comprehensive review. *J Autoimmun* 2013;41:34-45.
7. Goldberg MT, Han YP, Yan C, Shaw MC, Garner WL. TNF-alpha suppresses alpha-smooth muscle actin expression in human dermal fibroblasts: An implication for abnormal wound healing. *J Invest Dermatol* 2007;127:2645-55.