

Possible Causes for Failure of Endodontic Surgery – A Retrospective Series of 20 Resurgery Cases

 Frank C SETZER,  Meghan J HARLEY,  Julia Y CHEUNG,  Bekir KARABUCAK

ABSTRACT

Objective: This study aimed to evaluate unsuccessful endodontic surgery cases for possible causes for treatment failure and evaluate if a nonsurgical retreatment (NSRTX) approach could have been a better alternative to resurgery.

Methods: Analyses of clinical and cone-beam computed tomography (CBCT) images, periapical radiographs, and chart documentation determined study parameters. Preoperative factors were age, sex, tooth type, signs and/or symptoms, presence of periapical radiolucency, previous root canal treatment, timeline since previous endodontic surgery, presence of posts, cores, and restorations. The intra-operative factors were microsurgical classification, previous techniques, and current techniques utilized. Postoperative factors were signs and/or symptoms, time to follow-up, and healing status. The accessibility of the root canal system and the quality of the existing root filling were used to evaluate NSRTX as an alternative to resurgery.

Results: A total of 1073 surgical cases from 2011-2019 were reviewed. In 14 patients, 20 cases matched the inclusion criteria and allowed for data extraction. The mean time since the previous surgery was 2.9 ± 2.1 years, with a mean follow-up of 9.1 ± 5.8 months after the resurgery. Possible reasons for failure identified were: insufficient root-end filling (leaking, off-axis preparation, lack of depth, overfill) $n=12/20$, 60.0%; missed anatomy (main and lateral canals, isthmus) $n=9/20$, 45.0%; incomplete resection $n=6/20$, 30.0%. In 18/20 cases (90.0%), resurgery appeared to be indicated for 2/20 cases (10.0%). Therefore, NSRTX may have been a potential alternative.

Conclusion: Further evidence for possible causes of failure of endodontic surgery was provided, which were primarily iatrogenic. The evaluation of CBCT and high magnification intra-operative images proved beneficial for identifying critical issues for all investigated cases.

Keywords: Apicoectomy [E06.397.102], Cone-Beam computed tomography [E01.370.350.825.810.810.399], endodontics [E06.397], root canal preparation [E06.397.778.889], retrograde obturation, [E06.397.778.778.684]

Please cite this article as: Setzer FC, Harley MJ, Cheung JY, Karabucak B. Possible Causes for Failure of Endodontic Surgery – A Retrospective Series of 20 Resurgery Cases. *Eur Endod J* 2021; 6: 235-41

From the Department of Endodontics (F.C.S. ✉ fsetzer@upenn.edu, M.J.H., J.Y.C., B.K.), School of Dental Medicine, University of Pennsylvania, Philadelphia, USA

Received 08 February 2021,
Accepted 15 May 2021

Published online: 16 August 2021
DOI 10.14744/eej.2021.14238

This work is licensed under a Creative Commons Attribution-NonCommercial 4.0 International License.



HIGHLIGHTS

- A series of unsuccessful endodontic surgery cases were evaluated for possible causes for treatment failure.
- Cone Beam Computer Tomography (CBCT), periapical radiographs and chart documentation were analysed.
- The majority of possible reasons for failure were related to insufficient root-end fillings, followed by missed anatomy and incomplete resection.

INTRODUCTION

Endodontic root-end surgery is indicated for the treatment of persistent apical periodontitis after NSRTX or, sometimes, initial endodontic therapy (1). Various surgical techniques were introduced to make the procedure safer, easier to perform, and more predictable (2). Traditional root-end surgery (TRS) included access and root-end resection with surgical burs and amalgam as root-end filling material (3, 4). Modern root-end surgery is described as endodontic microsurgery (EMS) (5). EMS is defined by the use of the dental operating microscope, which provides high magnification and direct illumination (6). EMS utilises ultrasonic

root-end preparation, which allows root-end cavity preparation aligned with the root canal (6). Furthermore, EMS involves biocompatible materials and stable root-end filling materials for better healing processes than amalgam or other cements historically used for retrograde fillings (7).

The outcome of endodontic surgery has improved over time. A cumulative success rate of 59.0% was demonstrated for TRS (8). The success rates for both contemporary root-end surgery (CRS; modern techniques without the use of high magnification), and EMS (modern techniques with the use of high magnification) have significantly increased to a range of 88.1-94.4% (9-11). The biological reason for the failure of endodontic surgery is the inability to address the causes of apical periodontitis. In the majority of situations, this is the continued presence of intra- and/or extra-radicular infection (1). Decision-making between nonsurgical retreatment of a surgical case, also known as resurgery, largely depends on whether the clinical reason for failure is identified or remains unknown.

NSRTX was suggested as the first choice of treatment if the suspected cause of failure was related to an insufficient root filling or coronal leakage, and if the root canal system was considered accessible for reinstrumentation (12). Mente et al. (13) published a prospective case series where 25 failed surgical cases were treated by NSRTX and filled with an orthograde apical MTA plug. The success rate was 100% for anterior teeth and 80% for posterior teeth. Apart from NSRT, there are several options to address unsuccessful surgical cases. If failure is associated with one particular root, crown resection [hemisection, trisection, and premolarization (bicuspidization)] or root resection [root amputation or any root resection at the level of the cemento-enamel junction] may be considered (14), as well as intentional replantation (15); resurgery; or extraction (16). A systematic review of endodontic resurgery reported a weighted pooled success rate of 36%. However, the included studies primarily used TRS (17). A recent retrospective study compared initial EMS with endodontic micro-resurgery, with no statistically significant differences in outcome after 5 years between initial (91.6%) and micro-resurgery (87.6%) (18).

There is still limited information on the reasons for the failure of initial endodontic surgery. The evaluation of failed surgical cases by resurgery enables direct inspection of the previous surgical site, thereby providing further insight into the cause for failure. Kratchman (15) described the absence or incorrect placement of a root-end filling as the most common cause of failure of an initial surgical procedure. One prospective clinical study (12) demonstrated that for 54 cases, the possible causes for treatment failure included the absence of a root-end filling, incorrect root-end preparation, a missed or leaking canal, and an unfilled isthmus area. However, the authors did not include cone-beam computed tomography (CBCT) in the evaluation for possible causes for treatment failure.

This study's primary aim was to evaluate possible causes of failure of initial endodontic surgery, including the assessment of three-dimensional CBCT images acquired before resurgery. The secondary aim was to evaluate if NSRTX af-

ter previous surgery, as described by Mente et al. (13), could have been a technical possibility as an alternative to the resurgery, based on the combined information in the dental history and clinical evaluation, two-dimensional and three-dimensional imaging obtained before the surgical procedure, and the intra-operative findings as evident from clinical images.

MATERIALS AND METHODS

Case selection and inclusion/exclusion criteria

Data was collected from patients of the Department of Endodontics of the University of Pennsylvania (IRB approval #834029; August 26th, 2019). The clinical database included patients who had undergone endodontic microsurgery between 2011 and 2019. All records were reviewed for the following inclusion and exclusion criteria. Inclusion criteria: [1] History of previous surgical retreatment, indicated by patient's records or according to the patient's own reports, with radiographic signs of prior root resection and/or root-end filling; [2] Endodontic micro-resurgery performed within the Department of Endodontics, including complete documentation of pre-operative diagnosis and symptoms, surgical proceedings, preoperative and postoperative radiographs, and follow-up history; [3] Cone-beam computed tomography (CBCT) imaging before the endodontic micro-resurgery procedure. Exclusion criteria: [1] Teeth with a history of dental trauma, vertical root fracture or furcal/mid-root perforations during initial endodontic treatment; [2] The microsurgery involved any complete crown resection or root resection (14).

Surgical procedure

All resurgery procedures were performed at the Department of Endodontics and followed the endodontic microsurgical guidelines and principles outlined by Kim and Kratchman (5). Surgical procedures were conducted after a pulpal diagnosis of previously endodontically treated with a history of endodontic surgery and a periapical diagnosis of either symptomatic or asymptomatic apical periodontitis or chronic or acute apical abscess. A preoperative limited field-of-view (4x4 cm, voxel size=0.125 mm) CBCT was acquired (Veraviewepocs 3D R100; Morita, Irvine, CA, USA). After informed consent was obtained, patients received local anaesthesia with Lidocaine 2%,1:50.000 adrenaline for buccal infiltration, and, if applicable, Lidocaine 2%,1:100.000 adrenaline for infra-alveolar nerve blocks. With the exception of surgical flap elevation and wound closure, all surgical steps were performed using a dental operating microscope (ProERGO, Zeiss, Dublin, CA, USA). After flap elevation, osteotomy was performed, and the previous surgical procedure was inspected under high magnification. A second inspection was carried out after recontouring the previously resected root surface and staining with methylene blue. If applicable, possible reasons for the failure of the previous surgical procedure were documented by clinical images and/or notes. Root-end preparation was performed using ultrasonic tips (JetTip, B&L BioTech, Fairfax, VA; KiS Tip, Obtura Spartan®, Algonquin, IL, Fairfax, VA, USA), and inspected under magnification. Bioceramic root-end fillings were placed (Endosequence Root Repair Material, Bras-

seler, Savannah, GA, Fairfax, VA, USA; Algonquin, IL, USA) and inspected. Wounds were closed with monofilament sutures (5.0 Supramid nylon sutures; SJackson Inc, Alexandria, VA, Savannah, GA, USA). Periapical radiographs were taken. After postoperative instructions, patients received a prescription for nonsteroidal anti-inflammatory pain medication, an antibacterial mouth rinse, and antibiotics if medically indicated. Sutures were removed 3–5 days after surgery.

Data extraction

Existing CBCTs, periapical radiographs (PA), and clinical information were collected and evaluated. Preoperative factors included age, sex, tooth type (anterior, premolar, and molar), preoperative signs and/or symptoms (pain (symptomatic; asymptomatic), swelling, sinus tracts, drainage, tenderness to percussion and/or palpation), presence of periapical radiolucency on radiographic images (absent: lamina dura intact and uninterrupted; present: with or without a demarcated, well-defined border), the status of existing root canal filling (sufficient adequate length, no voids; insufficient: underfill, voids), time since previous endodontic surgery, presence of posts or build-ups restricting access to the root canal system (e.g. metal post or amalgam core), and type of restoration (direct restoration, full coronal coverage). Intraoperative factors included the extent of the lesion (microsurgical classification A-F according to Kim and Kratchman (5)), previous root-end filling material (none, amalgam, mineral trioxide aggregate (MTA), bioceramic putty (Root Repair Material, RRM), other), and techniques utilized (TRS, CRS, EMS, other (resection only, no root-end filling)). Postoperative factors were obtained from clinical and radiographic information at follow-up evaluations, including signs or symptoms (as above), time of follow-up (<6 months; 6 to <12 months; ≥12 months) and individual healing status according to the classification by Molven et al. (19) for teeth with 6 or more months of follow-up (complete healing; incomplete healing; uncertain healing; unsatisfactory healing).

Data assessment

The presence of preoperative periapical radiolucencies (PAs and CBCT) and at follow-up (PAs) were assessed by two calibrated, individual reviewers (BK, FS). Cohen's κ -coefficient was recorded with disagreements resolved by joint discussion. In addition, the possible causes of failure of the previous surgery were determined by joint review of pre-operative PAs, CBCT, intra-operative images of inspection of the previous surgery and the re-resected root surface at high magnification (16–24x) with and without methylene blue staining, as well as chart documentation. The possible causes of failure were recorded as missed anatomy (main canal; lateral canal and/or isthmus), incomplete resection, and/or insufficient root-end filling (no root-end filling; leaking (gap between previous root-end filling and dentine or obvious leakage after methylene blue staining as observed on clinical images); off-axis root-end preparation; inadequate depth (root-end filling materials <3 mm on radiographic images); overfill (root-end filling material in excess and/or beyond root structure); other (e.g., root fracture)). If several possible causes for failure were observed, all were recorded.

To assess whether a nonsurgical approach was a technical possibility and potential alternative to resurgery, all cases were scored as either favourable or unfavourable for NSRTX, following previously described criteria (1). Favourable for NSRTX was defined by a combination of [1] insufficient existing root canal filling (NSRTX has a high likelihood of improving the existing root filling) and [2] absence of posts or obstructive cores (root canal system accessible by coronal approach without risk for rendering the tooth non-restorable). Unfavourable for NSRTX was defined as a combination of [1] sufficient existing root canal filling (the higher likelihood that reason for failure is unrelated to intra-radicular causes) and [2] presence of posts or obstructive cores (that may require aggressive dentine removal during NSRTX).

RESULTS

A total of 1,073 surgical cases with preoperative CBCTs were reviewed. Of these, 20 cases fit the inclusion criteria. Data extraction was performed for 20 cases in 14 patients, including 7 male and 7 female. The age of the patients at the time of resurgery ranged from 25–68 (53.1 ± 15.7) years. Fig. 1 details a representative example for endodontic micro-resurgery.

Case series and possible causes of failure

The mean time from previous surgery to micro-resurgery was 2.9 ± 2.1 years, with a mean follow-up period of 9.1 ± 5.8 months after resurgery. Details on age distribution, tooth type, preoperative symptoms and periapical radiolucencies; microsurgery classification; type of previous surgery; possible causes of failure, and follow-up time are listed in Table 1. The κ -coefficient for the detection of pre-surgery radiographic lesions was 1.0 (PA and CBCT assessment). The most common possible causes of failure were insufficient root-end filling (lack of depth $n=1$, Fig. 1a; leaking $n=5$, Fig. 1b; off-axis preparation $n=5$; overfill $n=1$); missed anatomy (main Canal $n=6$, Fig. 2ab, 4b; lateral canal $n=2$, Fig. 3ab; Isthmus $n=1$); and incomplete resection $n=6$, Fig. 4a. Type of restoration pre-resurgery; the presence of post and/or obstructive cores; status of existing root canal filling; and the previous root-end filling material are detailed per tooth group in Table 2. Pre-operatively and at follow-up, all teeth had mobility 0-I; however, a mandibular anterior with microsurgical classification F had been splinted. Of the teeth with the latest follow-up between 6–12 months ($n=8$), 5 were classified as “complete healing”, 1 as “incomplete healing”, and 2 as “unsatisfactory healing”. Of the teeth with the follow-up of 12 months or longer, 5 were classified as “complete healing”, 1 as “incomplete healing”, and 2 as “unsatisfactory healing”. κ -coefficient for the healing classifications was 0.86 (PA assessment).

Non-surgical retreatment as potential alternative

At the time of decision-making for resurgery, 7/20 cases demonstrated insufficient existing root canal fillings, and 7/20 had no posts or obstructive cores, allowing for adequate access to the root canal system via a coronal approach (Table 2). Two cases (2/20), one maxillary first molar, and one mandibular lateral incisor presented with the combination of both variables, “insufficient existing root canal filling” and “no posts or obstructive cores”. Therefore, these two cases were considered

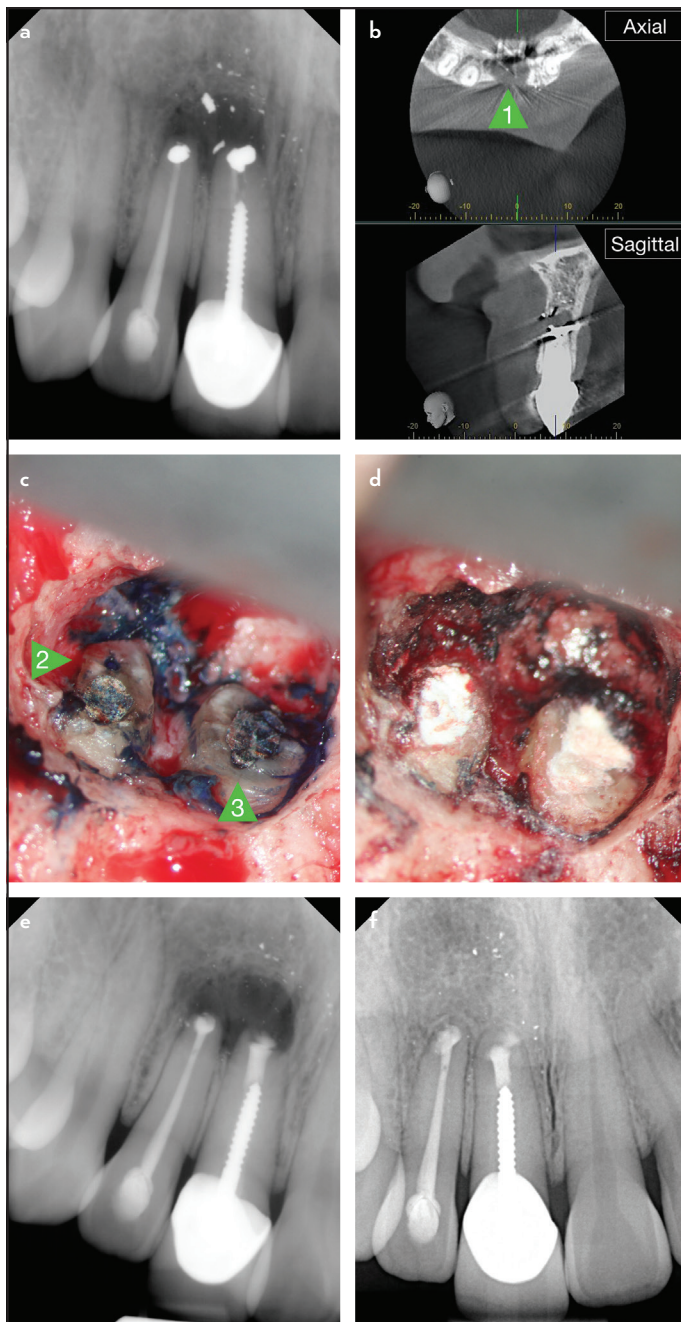


Figure 1. Representative example for endodontic micro-resurgery. (a) Preoperative radiograph, more than 5 years after the initial endodontic surgery. Traditional Root-end Surgery, retrograde fillings with amalgam, lack of preparation depth. (b) Preoperative CBCT, axial and sagittal views. Arrow [1]: buccal fenestration. Note the artifacts from the metal crown, large post and metallic root-end filling in sagittal view. (c) Intra-operative photograph at high magnification (24x) after removing granulation tissues, staining with methylene blue. Arrow [2]: Incomplete resection of the lingual portion of root on the lateral incisor. Arrow [3]: Leakage of amalgam root-end filling. (d) Intra-operative picture at high magnification (24x) after new root-end filling with RRM. (e) Postoperative radiograph. (f) Follow-up radiograph 12 months after resurgery. Note bone fill in periradicular area. Courtesy Dr. Josh Steffen

“favourable for non-surgical retreatment” before resurgery, and NSRTX could have been a reasonable alternative based on a previous investigation (13).

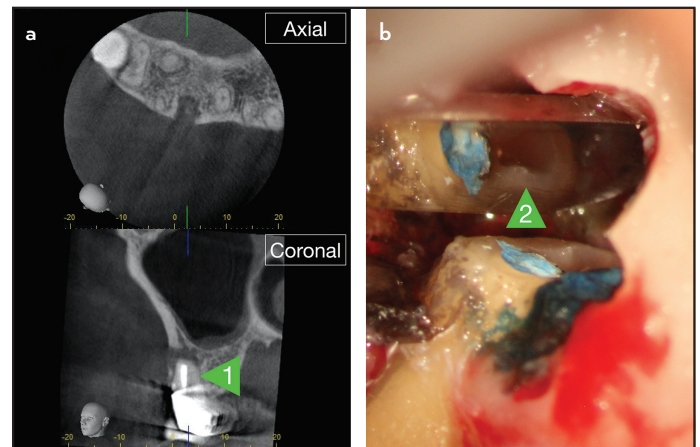


Figure 2. Representative example for possible causes of failure. (a) Preoperative CBCT, axial and coronal views. First right maxillary molar. Arrow [1]: missed main canal: second mesiobuccal canal (MB2). (b) Corresponding intra-operative image at high magnification (24x) after root resection and staining with methylene blue. Arrow [2]: MB2, view in a micro-mirror. Note the previous root filling in MB1, partial isthmus and calcified MB2. Courtesy Dr. Stephanie Chen

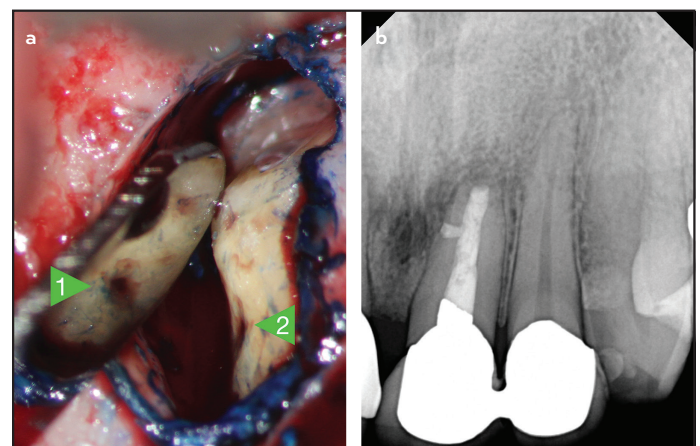


Figure 3. Representative example for possible causes of failure. (a) Intra-operative image at high magnification (24x) after removing granulation tissues, staining with methylene blue. Arrow [1]: missed lateral canal in central left maxillary incisor, view in a micro mirror. Arrow [2]: Identical missed lateral canal, direct view. (b) Corresponding follow-up radiograph 6 months after resurgery. Note bone fill in lateral periradicular area. Courtesy Dr. Ya-Hsin Yu

DISCUSSION

The emphasis of most studies on endodontic resurgery has been on the outcome of the procedure. Studies that did not employ high magnification reported less success of resurgery compared to initial endodontic surgery (20, 21). The use of microsurgical techniques demonstrated no significant difference between initial and resurgery (12). Saunders reviewed the possible reasons for the failure of initial surgical procedures (22). They discussed microbial issues, affected by difficulties to clean a root canal system due to coronal impediments or by coronal leakage (23); anatomical aberrations, such as isthmuses (24); infected missed or lateral canals; and iatrogenic damage to the tooth or the surrounding tissues (25).

TABLE 1. Distribution of cases

Variables	Groups	n
Age (years) (n=20 teeth)	<30	4
	30-39	3
	40-49	4
	50-59	2
	>59	7
Sex (n=14 patients)	Male	7
	Female	7
Tooth Type (n=20)	Maxillary, anterior	10
	Premolar	3
	Molar	3
	Mandibular, anterior	3
	Premolar	0
	Molar	1
Symptomatic (n=12, more than one symptom possible)	Pain	12
	Percussion or palpation	12
	Sinus tract	2
	Swelling	2
	Drainage	1
	None	8
	Asymptomatic (n=8)	None
Periapical radiolucency (PA, CBCT)	Present	20
	Absent	0
Microsurgery classification (n=20)	A	0
	B	14
	C	3
	D	0
	E	0
	F	3
Type of previous surgery	EMS	16
	TRS	4
Possible cause of failure (more than one possible)	Insufficient root-end filling	12
	Leaking	5
	Off-axis preparation	5
	Inadequate depth	1
	Overfill	1
	Missed anatomy	9
	Main canal	6
	Lateral canal	2
	Isthmus	1
	Incomplete resection	6
Follow-up time (n=20)	<6 months	4
	6 to <12 months	8
	≥12 months	8

PA: Periapical radiographs, CBCT: Cone-beam computed tomography, EMS: Endodontic microsurgery, TRS: Traditional root-end surgery

Iatrogenic damage to the tooth during the initial surgery may include an incorrect resection angle, incomplete removal of the root end, and perforation of the root due to an off-axis retrograde preparation (22). Song et al. (12) determined that no root-end filling and incorrect root-end preparation were the most common causes of failure, followed by missing or leaky canals and unidentified isthmuses. The authors utilised a high magnification inspection of the resected root surface to identify possible reasons for the failure of previous surgeries (12). Increased acuity of the observer using high magnification was predicted by Peterson & Gutmann (17) in their meta-analysis on endodontic resurgery. Improved outcomes with high magnification were proven for endodontic micro-resurgery (22) and initial endodontic surgery (11). In contrast to Song et al. (12), who did not use CBCT, the present case series added

pre-operative CBCT imaging to analyse failed initial endodontic surgery. CBCT imaging aids in identifying missed canals (26) and improves the accuracy of periapical lesion detection (27). In this study, CBCT also allowed for a better evaluation of the axial orientation of the existing root-end filling.

The results of this investigation agree with previous studies (12, 13) that iatrogenic errors during the initial surgery are a common possible cause of failure. In contrast to Song et al. (12), who included a category of "unknown" failures, in this study at least one possible cause of failure was demonstrated for every case evaluated. No case remained with unknown reasons for failure. The inclusion of preoperative CBCT in the evaluation may have contributed to these findings. It is also noteworthy to mention that different from Song et al. (12), we

TABLE 2. Distribution according to tooth type

Variables	n	Maxilla			Mandible		
		Anterior (n=10)	Premolar (n=3)	Molar (n=3)	Anterior (n=3)	Premolar (n=0)	Molar (n=1)
Restoration pre-resurgery (n=20)							
Filling	4	2	-	1	1	-	-
Full coronal coverage	16	8	3	2	2	-	1
Post and/or amalgam core (n=20)							
Present	13	8	3	1	-	-	1
Absent	7	2	-	2	3	-	-
Status of existing root canal filling (n=20)							
Sufficient	13	7	3	1	2	-	-
Insufficient	7	3	-	2	1	-	1
Previous root-end filling material (n=20)							
Amalgam	4	3	-	1	-	-	-
MTA	2	-	1	-	1	-	-
RRM	14	7	2	2	2	-	1

MTA: Mineral trioxide aggregate, RRM: Root repair material

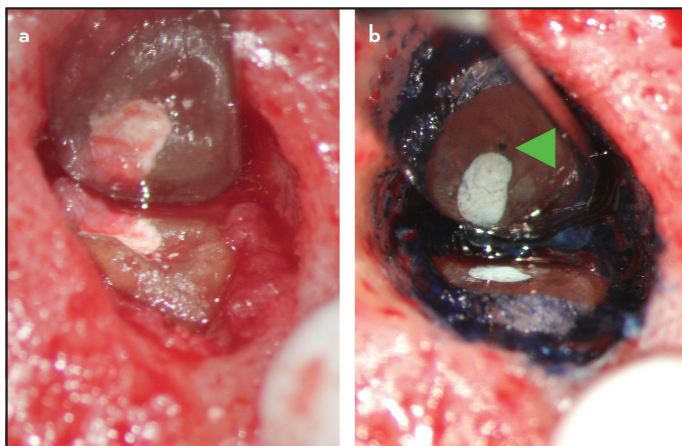


Figure 4. Representative example for possible causes of failure. (a) Intra-operative image at high magnification (24x) after initial removal of granulation tissues. Incomplete root resection of a second left maxillary premolar. (b) Corresponding intra-operative image after root recontouring and staining with methylene blue. Arrow: Missed lingual canal during the initial surgery, view in a micro-mirror. Courtesy Dr. Karla Sermeño

chose to combine unprepared “main canals” or “lateral canals” and “isthmuses” under the category “missed anatomy”, rather than to list, e.g. “missed canals” separately. We also combined “leaking” root-end fillings, “off-axis preparations”, “inadequate depth”, and “overfill” under “insufficient root-end fillings”, to pay respect to the commonalities of these findings. Nevertheless, all of these, together with incomplete resections, imply iatrogenic operator errors. All 20 cases evaluated in this series demonstrated at least one possible cause of failure; no case remained with unknown reasons for failure. The inclusion of preoperative CBCT in the evaluation may have contributed to these findings. It is a limitation of this investigation that only possible causes for failure of teeth undergoing resurgery could be examined. Teeth with a history of failed endodontic surgery that were extracted could not be evaluated. However, this study provides useful information for the clinician provid-

ing resurgery. Some possible causes for failure, such as missed canals in combination with previously placed insufficient root-end fillings, were only revealed by steps of the resurgery procedure, such as further resection or renewed retrograde instrumentation.

This case series was not part of a clinical trial on outcome and did not aim to report the procedures' success rate. Periapical healing was only included as a status report for cases with at least six months follow-up. Ideally, at least a one-year follow-up should be obtained for endodontic surgery (28, 29). After one year, most cases diagnosed as completely healed remained successful (28, 29). Cases classified as “incomplete healing” were eventually classified as “complete healing” or remained “incomplete healing” (30), and also largely remained in this category after long-term follow-up of 8-12 years (30). However, “uncertain healing” requires additional follow-up (29).

A limitation of this retrospective study may have been that no transillumination procedures were performed to investigate the resected root surfaces. The standard protocol in our institution utilizes methylene blue staining followed by inspection of a resected root surface at high magnification (24x)(5). Undetected micro-cracks or other dentinal defects resulting from the previous ultrasonic root-end preparation may have added to the potential causes of root-end surgery failure. Transillumination can detect micro-cracks in-vivo (31) and ex-vivo (32). LED transilluminators proved to be superior for dentinal defect detection (33). However, of all crack assessment techniques, the best discrimination between cracked and non-cracked roots could be obtained by a combination of methylene blue staining plus transillumination (34).

Lastly, for most of the cases evaluated, a sound decision-making process seemed to have been implemented. As discussed in the results, only for 2 cases a non-surgical retreatment approach would have been feasible or advised due to the limitations of restricted coronal access and insufficient root canal fillings. However, in the anterior case, the adjacent tooth

had to undergo surgery, so surgical retreatment was in part due to efficiency and reduced the number of visits for the patient.

CONCLUSION

This case series provided further evidence for the possible causes for the failure of endodontic surgery, aiding clinicians in their preparation and treatment during endodontic resurgery. The inclusion of CBCT in the postoperative analyses allowed for identifying at least one possible cause of failure for each evaluated case.

Disclosures

Conflict of interest: The authors deny any conflict of interest.

Ethics Committee Approval: This study was approved by Institutional Review Board of the University of Pennsylvania, #834029; August 26th, 2019.

Peer-review: Externally peer-reviewed.

Financial Disclosure: The work was supported by the University of Pennsylvania Department of Endodontics Research fund.

Authorship contributions: Concept – F.C.S., M.J.H., B.K.; Design – F.C.S., M.J.H.; Supervision – F.C.S., B.K.; Funding – B.K.; Materials – B.K.; Data collection &/or processing – F.C.S., M.J.H., J.Y.C., B.K.; Analysis and/or interpretation – F.C.S., M.J.H., J.Y.C.; Literature search – F.C.S., M.J.H.; Writing – F.C.S., M.J.H., J.Y.C., B.K.; Critical Review – F.C.S., M.J.H., J.Y.C., B.K.

REFERENCES

- Karabucak B, Setzer F. Criteria for the ideal treatment option for failed endodontics: surgical or nonsurgical? *Compend Contin Educ Dent* 2007; 28(7):391–7.
- Friedman S. Outcome of endodontic surgery: a meta-analysis of the literature—part 1: comparison of traditional root-end surgery and endodontic microsurgery. *J Endod* 2011; 37(5):577–8; author reply 578–80.
- Dorn SO, Gartner AH. Retrograde filling materials: a retrospective success-failure study of amalgam, EBA, and IRM. *J Endod* 1990; 16(8):391–3.
- Harty FJ, Parkins BJ, Wengraf AM. The success rate of apicectomy. A retrospective study of 1,016 cases. *Br Dent J* 1970; 129(9):407–13.
- Kim S, Kratchman S. Modern endodontic surgery concepts and practice: a review. *J Endod* 2006; 32(7):601–23.
- Sultan M, Pitt Ford TR. Ultrasonic preparation and obturation of root-end cavities. *Int Endod J* 1995; 28(5):231–8.
- Rubinstein R. Magnification and illumination in apical surgery. *Endod Topics* 2006; 11(1):56–77.
- Setzer FC, Shah SB, Kohli MR, Karabucak B, Kim S. Outcome of endodontic surgery: a meta-analysis of the literature—part 1: Comparison of traditional root-end surgery and endodontic microsurgery. *J Endod* 2010; 36(11):1757–65.
- Tsisis I, Rosen E, Taschieri S, Telishevsky Strauss Y, Ceresoli V, et al. Outcomes of surgical endodontic treatment performed by a modern technique: an updated meta-analysis of the literature. *J Endod* 2013; 39(3):332–9.
- Kohli MR, Berenji H, Setzer FC, Lee SM, Karabucak B. Outcome of endodontic surgery: a meta-analysis of the literature—part 3: comparison of endodontic microsurgical techniques with 2 different root-end filling materials. *J Endod* 2018; 44(6):923–31.
- Setzer FC, Kohli MR, Shah SB, Karabucak B, Kim S. Outcome of endodontic surgery: a meta-analysis of the literature—Part 2: Comparison of endodontic microsurgical techniques with and without the use of higher magnification. *J Endod* 2012; 38(1):1–10.
- Song M, Jung IY, Lee SJ, Lee CY, Kim E. Prognostic factors for clinical outcomes in endodontic microsurgery: a retrospective study. *J Endod* 2011; 37(7):927–33.
- Mente J, Leo M, Michel A, Gehrig H, Saure D, Pfefferle T. Outcome of orthograde retreatment after failed apicoectomy: use of a mineral trioxide aggregate apical plug. *J Endod* 2015; 41(5):613–20.
- Setzer FC, Shou H, Kulwattanaporn P, Kohli MR, Karabucak B. outcome of crown and root resection: a systematic review and meta-analysis of the literature. *J Endod* 2019; 45(1):6–19.
- Kratchman S. Intentional replantation. *Dent Clin North Am* 1997; 41(3):603–17.
- Rud J, Andreasen JO, Jensen JE. A follow-up study of 1,000 cases treated by endodontic surgery. *Int J Oral Surg* 1972; 1(4):215–28.
- Peterson J, Gutmann JL. The outcome of endodontic resurgery: a systematic review. *Int Endod J* 2001; 34(3):169–75.
- Kim D, Kim S, Song M, Kang DR, Kohli MR, Kim E. Outcome of endodontic micro-resurgery: a retrospective study based on propensity score-matched survival analysis. *J Endod* 2018; 44(11):1632–40.
- Molven O, Halse A, Grung B. Observer strategy and the radiographic classification of healing after endodontic surgery. *Int J Oral Maxillofac Surg* 1987; 16(4):432–9.
- Saunders WP. A prospective clinical study of periradicular surgery using mineral trioxide aggregate as a root-end filling. *J Endod* 2008; 34(6):660–5.
- Gagliani MM, Gorni FG, Strohmenger L. Periapical resurgery versus periapical surgery: a 5-year longitudinal comparison. *Int Endod J* 2005; 38(5):320–7.
- Saunders WP. Considerations in the revision of previous surgical procedures. *Endod Topics* 2005; 11(1):206–18.
- Saunders WP, Saunders EM. Coronal leakage as a cause of failure in root-canal therapy: a review. *Endod Dent Traumatol* 1994; 10(3):105–8.
- Hsu YY, Kim S. The resected root surface. The issue of canal isthmuses. *Dent Clin North Am* 1997; 41(3):529–40.
- Gilheany PA, Figdor D, Tyas MJ. Apical dentin permeability and microleakage associated with root end resection and retrograde filling. *J Endod* 1994; 20(1):22–6.
- Karabucak B, Bunes A, Chehoud C, Kohli MR, Setzer F. Prevalence of apical periodontitis in endodontically treated premolars and molars with untreated canal: a cone-beam computed tomography study. *J Endod* 2016; 42(4):538–41.
- Leonardi Dutra K, Haas L, Porporatti AL, Flores-Mir C, Nascimento Santos J, Mezzomo LA, et al. Diagnostic accuracy of cone-beam computed tomography and conventional radiography on apical periodontitis: a systematic review and meta-analysis. *J Endod* 2016; 42(3):356–64.
- Zuolo ML, Ferreira MO, Gutmann JL. Prognosis in periradicular surgery: a clinical prospective study. *Int Endod J* 2000; 33(2):91–8.
- Halse A, Molven O, Grung B. Follow-up after periapical surgery: the value of the one-year control. *Endod Dent Traumatol* 1991; 7(6):246–50.
- Molven O, Halse A, Grung B. Incomplete healing (scar tissue) after periapical surgery—radiographic findings 8 to 12 years after treatment. *J Endod* 1996; 22(5):264–8.
- Tawil PZ. Periapical Microsurgery: Can ultrasonic root-end preparations clinically create or propagate dentinal defects? *J Endod* 2016; 42(10):1472–5.
- Coelho MS, Card SJ, Tawil PZ. Visualization enhancement of dentinal defects by using light-emitting diode transillumination. *J Endod* 2016; 42(7):1110–3.
- Arnarsdottir EK, Karunanayake GA, Pettit NE, Phillips C, Saemundsson SR, Tawil PZ. Periapical microsurgery: assessment of different types of light-emitting diode transilluminators in detection of dentinal defects. *J Endod* 2020; 46(2):252–7.
- Wright HM Jr, Loushine RJ, Weller RN, Kimbrough WF, Waller J, Pashley DH. Identification of resected root-end dentinal cracks: a comparative study of transillumination and dyes. *J Endod* 2004; 30(10):712–5.