

Apogeotropic variant of horizontal semicircular canal benign paroxysmal positional vertigo: Where are the particles?

Bernardo Faria Ramos,¹ Renato Cal,² Camila Martins Brock,³ Pedro Luiz Mangabeira Albernaz,⁴ Francisco Zuma e Maia³

¹Department of Otorhinolaryngology, Espirito Santo Federal University, Vitória; ²Department of Otorhinolaryngology, Pará Federal University, Belém; ³Department of Otorhinolaryngology, Pontifical Catholic University of Rio Grande do Sul, Porto Alegre; ⁴Federal University of São Paulo, São Paulo, Brazil

Abstract

The apogeotropic variant of horizontal semicircular canal benign paroxysmal positional vertigo (HC-BPPV) is attributed to free floating particles in the anterior arm of the lateral semicircular canal – particles attached to the cupula facing the canal or particles attached to the cupula facing the utricle. Zuma e Maia described a new treatment for both canalithiasis of the anterior arm of the horizontal semicircular canal (HC) and cupulolithiasis of the HC. Seventeen patients with apogeotropic HC-BPPV were enrolled and treated with Zuma's Maneuver. During the repositioning of the particles to the utricle, we observed the direction of the nystagmus evoked in each step of this maneuver in order to know where the otoliths were probably located. Eight patients were diagnosed with canalithiasis of the anterior arm, six patients with cupulolithiasis with the particles facing the canal and three patients with cupulolithiasis with the particles facing the utricle. Our data suggest that we can assume where the otoliths are probably located by observing the pattern of the nystagmus evoked in

each step of the Zuma's Maneuver in patients with apogeotropic HC-BPPV.

Introduction

The apogeotropic variant of horizontal semicircular canal benign paroxysmal positional vertigo (HC-BPPV) is attributed to free floating particles in the anterior arm of the horizontal semicircular canal (HC) – particles attached to the cupula facing the canal or particles attached to the cupula facing the utricle.¹⁻³ It is characterized by horizontal nystagmus beating to the opposite side of the head turn in the supine roll test.

The diagnosis of the affected side is critical for the successful treatment.⁴ An important clinical sign to identify the affected side in HC-BPPV, is the intensity of the nystagmus evoked by the supine head roll test or McClure-Pagnini test. The McClure-Pagnini test is performed by turning the head about 90° to each side in supine position. Since it is performed on the yaw plane, it should be more correct to call it the head yaw test (HYT) while supine.^{5,6} The nystagmus beats with more intensity towards the affected ear, according to Ewald's second law, which postulates that the response to an excitatory stimulus is always more intense than the one following an inhibitory stimulus. In the apogeotropic HC-BPPV,^{6,7} the particles will move away from the ampulla during the HYT to the affected ear, resulting in an ampulofugal inhibitory endolymphatic current, causing a nystagmus beating to the unaffected ear. Turning the head to the healthy side, the particles will move towards the ampulla, resulting in an ampulopetal excitatory endolymphatic current, causing a nystagmus beating toward the affected ear. Hence, in the apogeotropic HC-BPPV the affected side is the one in which the nystagmus is less intense.

Another clinical tool to identify the impaired side is to observe the direction of the nystagmus in the Seated Supine Positioning Test (SSPT).^{8,9} In this test, the patient is briskly brought from seated position to the supine position. When the patient lies in the supine position, having the head flexed 30°, the HC is on a vertical plane and the particles are pushed downwards. In the apogeotropic HC-BPPV it results in an ampulopetal excitatory endolymphatic current, therefore the nystagmus beats toward the affected side.

Patients with apogeotropic HC-BPPV may be presented with a spontaneous nystagmus. This sign was previously described as a pseudo-spontaneous nystagmus (PSN) by Asprella Libonati.⁴ The differential diagnosis between a spontaneous nystagmus and a PSN may be achieved with the Head Pitch Test in the sitting position. In this test, the PSN disappears with the head bent 30° forward, reverses direction with the head bent 60° forward and

Correspondence: Bernardo Faria Ramos, Department of Otorhinolaryngology, Espirito Santo Federal University, Av. Saturnino de Brito 256, Vitória-ES. 29050-385, Brazil.
E-mail: bernardoframos@gmail.com

Key words: Apogeotropic horizontal canal benign paroxysmal positional vertigo; Vertigo; Repositioning maneuver.

Contributions: the authors contributed equally.

Conflict of interest: the authors declare no potential conflict of interest.

Conference presentation: part of this paper was presented at the *Reunião de Fundacion Iberoamericana de Neuro-otologia (FINO)*, June 7-9, 2019, Cancun, Mexico.

Received for publication: 25 June 2019.

Revision received: 2 August 2019.

Accepted for publication: 17 August 2019.

This work is licensed under a Creative Commons Attribution NonCommercial 4.0 License (CC BY-NC 4.0).

©Copyright: the Author(s), 2019
Licensee PAGEPress, Italy
Audiology Research 2019;9:228
doi:10.4081/audiores.2019.228

increases intensity with head extension 30° backwards.

Zuma e Maia¹⁰ described a new treatment strategy to both canalithiasis of the anterior arm of the HC or cupulolithiasis of the HC with high success rates. In this study, we observed that the patients showed different pattern of nystagmus in the first three steps of this maneuver. The purpose of the study was to evaluate our patients with apogeotropic HC-BPPV and the dynamics of nystagmus during the repositioning of the particles in order to know where the otoliths were probably located.

Materials and Methods

A retrospective study was conducted on 17 consecutive patients who were diagnosed with an apogeotropic HC-BPPV without a history of trauma or concomitant neuro-otologic disease. BPPV was diagnosed when a bidirectional apogeotropic horizontal nystagmus was demonstrated in the supine head roll test or McClure-Pagnini test and the characteristic horizontal nystagmus toward one side was observed in the SSPT^{8,9} using a Video Frenzel goggle. We excluded from the study patients that did not show the characteristic of the nystagmus required to the diagnose of a HC-BPPV or that were not successfully treated with the Zuma's Maneuver.

All patients were treated with Zuma's Maneuver (Figure 1).^{10,11} This maneuver is performed with patients in the sitting position. First, the patient is asked to quickly lie down on the affected side (step I) and is held in this position for 3 minutes. Then, the patient's head is rotated 90° toward the ceiling (step II) and held in this position for another 3 minutes. After 3 minutes, the patient moves the body into dorsal decubitus and the head is turned 90° toward the unaffected side (step III) and held in this position for another 3 minutes. Finally, the patient's head is tilted slightly

forward (step IV), followed by a slow return of the patient to the sitting position (step V).¹⁰

The pattern of the nystagmus evoked in step I, II and III during this maneuver was observed with Video-Frenzel goggles without fixation.

Zuma's Maneuver

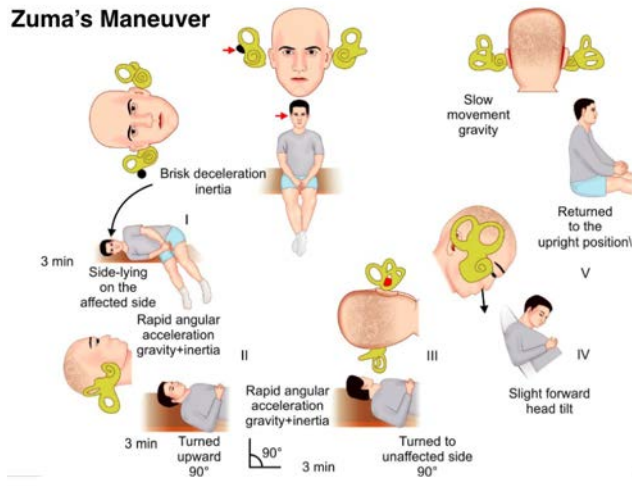


Figure 1. The Zuma's Maneuver is performed with patients in the sitting position. First, the patient is asked to quickly lie down on the affected side (step I) and is held in this position for 3 minutes. Then, the patient's head is rotated 90° toward the ceiling (step II) and held in this position for another 3 minutes. After 3 minutes, the patient moves the body into dorsal decubitus and the head is turned 90° toward the unaffected side (step III) and held in this position for another 3 minutes. Finally, the patient's head is tilted slightly forward (step IV), followed by a slow return of the patient to the sitting position (step V). *Data modified from Zuma e Maia 2016¹⁰ and MacDougall and Rogers.¹¹*

Anterior Arm

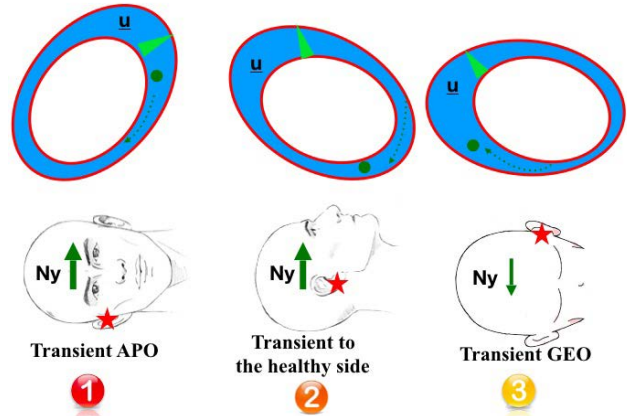


Figure 2. Otoliths located on the anterior arm of the horizontal semicircular canal. Since the particles are free floating in the canal, there is a short duration nystagmus in step I. As the particles are moving away from the ampulla in step I, II and III the nystagmus beats toward the unaffected ear. u, utricle; Ny, nystagmus; APO, apogeotropic nystagmus; GEO, geotropic nystagmus.

Cupula Canal

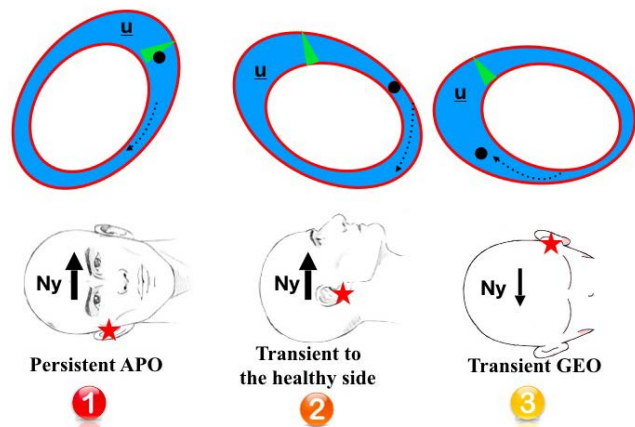


Figure 3. Otoliths located on the canal side of the cupula. Since the particles are attached to the cupula, there is a long duration nystagmus in step I. As the particles are moving away from the ampulla in step I, II and III the nystagmus beats toward the unaffected ear. In step II and III there is a transient nystagmus due to the transformation from cupulolithiasis to canalolithiasis. u, utricle; Ny, nystagmus; APO, apogeotropic nystagmus; GEO, geotropic nystagmus.

Results

Of the 17 patients affected by apogeotropic variant of HC-BPPV, 7 were male and 10 were female, age range 33-78 years. Seven patients were diagnosed with right HC-BPPV and 10 patients with left HC-BPPV. All patients demonstrated a nystagmus beating to the uppermost ear with less intensity turning the head to the affected side in the McClure-Pagnini test and a nystagmus beating to the affected side in the SSPT.

Eight patients showed an apogeotropic transient nystagmus (duration <60 seconds) in step I of Zuma's Maneuver. This nystagmus remained transient and maintained the same direction in step II and III, suggesting that the otoliths were located on the anterior arm of the HC (Figure 2). Six patients showed an apogeotropic persistent nystagmus (duration >60 seconds) in step I. This nystagmus became transient, due to the transformation from cupulolithiasis to canalolithiasis), and maintained the same direction in step II and III of the maneuver, suggesting that the otoliths were located on the canal side of the cupula (Figure 3). Three patients showed an apogeotropic persistent nystagmus in step I. This nystagmus changed direction and remained persistent in step II. In step III it maintained the same direction and became transient, due to the transformation from cupulolithiasis to canalolithiasis), suggesting that the otoliths were located on the utricular side of the cupula (Figure 4).

Subjects' characteristics, the affected side, the location of the otoliths and the nystagmus evoked during the Zuma's Maneuver of each patient is presented in Table 1.

Discussion

The present study suggests that we can assume where the particles are located in patients diagnosed with apogeotropic HC-BPPV using the Zuma's Maneuver.

When the otoliths were located on the anterior arm of the HC

we observed a transient apogeotropic nystagmus in step I, that maintained the same direction in step II and III of the maneuver. In step I, since the particles were free floating in the canal, there was a short duration nystagmus that lasted for less than 60 seconds. As the particles were moving away from the ampulla in step I, II and III these patients maintained a nystagmus beating toward the unaffected ear (Figure 2).

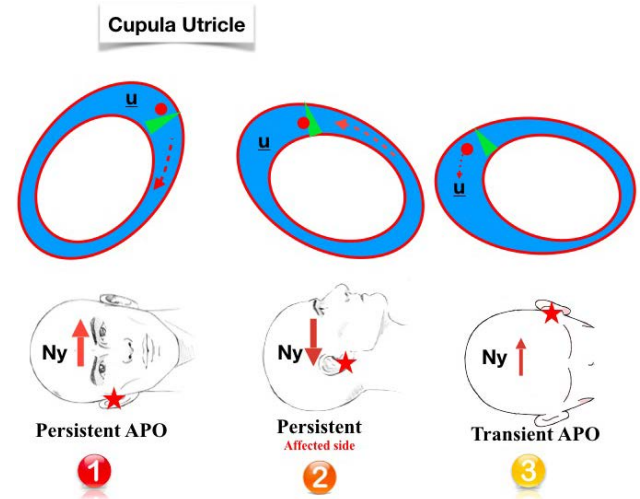


Figure 4. Otoliths located on the utricular side of the cupula. Since the particles are attached to the cupula in step I and II there is a long duration nystagmus. In step I, the particles deflect the cupula in the direction away from the ampulla causing a nystagmus beating toward the unaffected ear. In step II, the particles deflect the cupula in the ampulla's direction changing the nystagmus direction toward the affected side. In step III, the particles detach from the cupula and moved toward the ampulla, therefore there is a transient nystagmus beating toward the affected side. u, utricle; Ny, nystagmus; APO, apogeotropic nystagmus.

Table 1. Subjects' characteristics, affected side, location of the otoliths and the nystagmus pattern evoked during the Zuma's Maneuver.

| Patients | Age | Gender | Affected side | Group | Step 1 | Step 2 | Step 3 |
|----------|-----|--------|---------------|-------|--------|--------|--------|
| 1 | 68 | F | L | 1 | R, t | R, t | R, t |
| 2 | 55 | F | L | 3 | R, p | L, p | L, t |
| 3 | 70 | M | R | 2 | L, p | L, t | L, t |
| 4 | 67 | F | R | 2 | L, p | L, t | L, t |
| 5 | 69 | F | L | 2 | R, p | R, t | R, t |
| 6 | 54 | F | R | 2 | L, p | L, t | L, t |
| 7 | 65 | F | L | 2 | R, p | R, t | R, t |
| 8 | 77 | M | R | 2 | L, p | L, t | L, t |
| 9 | 54 | F | L | 3 | R, p | L, p | L, t |
| 10 | 33 | M | R | 1 | L, t | L, t | L, t |
| 11 | 37 | F | L | 1 | R, t | R, t | R, t |
| 12 | 64 | F | L | 1 | R, t | R, t | R, t |
| 13 | 53 | M | R | 3 | L, p | R, p | R, t |
| 14 | 78 | M | R | 1 | L, t | L, t | L, t |
| 15 | 71 | M | L | 1 | R, t | R, t | R, t |
| 16 | 70 | F | L | 1 | R, t | R, t | R, t |
| 17 | 54 | M | L | 1 | R, t | R, t | R, t |

Group 1, particles located on the anterior arm of the horizontal semicircular canal; Group 2, particles located on the canal side of the cupula; Group 3, particles located on the utricular side of the cupula. F, female; M, male; L, left; R, right; t, transient; p, persistent.

When the otoliths were located on the cupula facing the canal we observed a persistent apogeotropic nystagmus in step I. Since the particles were attached to the cupula, there was a long duration nystagmus that lasted for more than 60 seconds. As the particles were moving away from the ampulla in step I, II and III these patients maintained a nystagmus beating toward the unaffected ear. In step II and III there was a transient nystagmus due to the transformation from cupulolithiasis to canalolithiasis (Figure 3).

When the otoliths were located on the cupula facing the utricle we observed an apogeotropic nystagmus in step I that changed direction in step II. Since the particles were attached to the cupula in step I and II there was a long duration nystagmus that lasted for more than 60 seconds. In step I, the particles make the cupula heavier, deflecting it in direction away from the ampulla, resulting in an ampullofugal inhibitory endolymphatic current and causing a nystagmus beating toward the unaffected ear. In step II, since the cupula of the HC is inclined outwards, the particles make the cupula heavier to the other side, deflecting it in the ampulla's direction, resulting in an ampullopetal excitatory endolymphatic current and changing the nystagmus direction toward the affected side. In step III the particles were detached from the cupula and moved toward the ampulla, resulting in a transient nystagmus beating toward the affected side (Figure 4).

Kim *et al.*¹² proposed a repositioning maneuver that could identify the side of the cupula where the otoliths are attached and treat both types of HC cupulolithiasis. It starts with the patient in supine position, then the patient's head is turned 135° to the lesion side (1st position). Next, patient's head is turned 45° to the healthy side (2nd position, lateral decubitus to lesion side). Then, the patient's head is turned 90° to the healthy side (3rd position, supine position). For the 4th position, the patient's head is turned 90° to the healthy side (4th position, lateral decubitus to the healthy side). For the 5th position, the patient's head is rotated 90° in the same direction (5th position, prone position), and slowly the patient is brought back to sitting position without neck extension.

The 3rd position of Kim's Maneuver is comparable to step II of Zuma's Maneuver (supine position after lesion side head lateral decubitus) showing the same pattern of nystagmus in patients with apogeotropic variant of HC-BPPV. In these positioning patients with particles located in the anterior arm or in the canal side of the cupula show a nystagmus beating toward the healthy side, while patients with otoliths on the utricular side of the cupula show a nystagmus beating toward the affected side.

There are some limitations of this study mostly related to the small sample of patients enrolled. The frequency of each type of apogeotropic variant of HC-BPPV, however, can be discussed.

A previous study¹³ suggests that the utricular type of cupulolithiasis may be more frequent than canal type of cupulolithiasis and canalolithiasis in the anterior arm of the HC. When the otoconias are located on the canal side of the cupula and on the anterior arm of the HC, there is a long pathway through the posterior arm and the isthmus portion of the HC in order to return to the utricle. On the other hand, when the otoliths are on the utricular side of the cupula, the pathway to the utricle is very short, which could lead to spontaneous remission of symptoms. We assume that is the reason why lower patients in this study were affected by utricular side cupulolithiasis. In addition to this, according to a study about physio-mathematical models of BPPV,¹⁴ greater number of otoconias

are necessary to cause vestibular symptoms in cupulolithiasis compared to canalolithiasis, which can explain the higher frequency of patients with canalolithiasis in our study.

Conclusions

Our data suggest that we can assume where the otoliths are probably located by observing the pattern of the nystagmus evoked in each step of the Zuma's Maneuver in patients with apogeotropic HC-BPPV.

References

- Schubert MC. Stop the world – I want to get off. Vestibular SIG Newsletter. BPPV Special Ed 2013;17.
- Baloh RW, Yue Q, Jacobson KM, Honrubia V. Persistent direction-changing positional nystagmus: another variant of benign positional nystagmus? Neurology 1995;45:1297-301.
- Steddin S, Ing D, Brandt T. Horizontal canal benign paroxysmal positioning vertigo (h-BPPV transition of canalolithiasis to cupulo-lithiasis. Ann Neurol 1996;40:918-22.
- Asprella Libonati G. Pseudo-spontaneous nystagmus: a new sign to diagnose the affected side in lateral semicircular canal benign paroxysmal positional vertigo. Acta Otorhinolaryngol Ital 2008;28:73-8.
- Pagnini P, Nuti D, Vannucchi P. Benign paroxysmal vertigo of the horizontal canal. ORL J Otorhinolaryngol Relat Spec 1989;51:161-70.
- Nuti D, Vannucchi P, Pagnini P. Benign paroxysmal positional vertigo of the horizontal canal: a form of canalolithiasis with variable clinical features. J Vestib Res 1996;6:173-84.
- Pagnini P, Vannucchi P, Nuti D. Le nystagmus apogéotrope dans la vertige paroxystique positionnel bénin du canal sémi-circulaire horizontal: une canalolithiase. Rev d'ONO 1994;31:17-9.
- Asprella Libonati G. Diagnostic and treatment strategy of the lateral semicircular canal canalolithiasis. Acta Otorhinolaryngol Ital 2005;25:277-83.
- Nuti D, Vannucchi P, Pagnini P. Lateral canal BPPV: Which is the affected side? Audiol Med 2005;3:16-20.
- Zuma e Maia FC. New treatment strategy for apogeotropic horizontal canal benign paroxysmal positional vertigo. Audiol Res 2016;6:163.
- MacDougall H, Rogers S. AVOR – Angular Vestibulo-Ocular Reflex. Available from: http://www.psych.usyd.edu.au/HumanFactors/?page_id=2160
- Kim SH, Jo SW, Chung WK, et al. A cupulolith repositioning maneuver in the treatment of horizontal canal cupulolithiasis. Auris Nasus Larynx 2012;39:163-8.
- Shim DB, Ko KM, Lee JH, et al. Natural history of horizontal canal benign paroxysmal positional vertigo is truly short. J Neurol 2015;262:74-80.
- House MG, Honrubia V. Theoretical models for the mechanisms of benign paroxysmal positional vertigo. Audiol Neurootol 2003;8:91-9.