

## CASE REPORT

# A patient with RET D631Y mutation present with pheochromocytoma

Jung Min Kim 

Department of Internal Medicine, Sanggye Paik Hospital, Inje University College of Medicine, Seoul, Korea

**Correspondence**

Jung Min Kim, Department of Internal Medicine, Sanggye Paik Hospital, Inje University College of Medicine, Dongil-ro 1342, Nowon-gu, Seoul, Korea.  
Email: jmkim.benaiah@gmail.com

**Abstract**

Patients with MEN2A with RET D631Y mutation most commonly present with pheochromocytomas. MTC is a less common part of the syndrome. Therefore, MEN2A caused by the RET D631Y mutation would be a benign nature.

**KEYWORDS**

Medullary thyroid carcinoma, Multiple endocrine neoplasia type 2A, Pheochromocytoma, RET D631Y mutation

## 1 | INTRODUCTION

A RET D631Y mutation is rare in patients with multiple endocrine neoplasia type 2A (MEN2A). Patients with MEN2A with RET D631Y mutation most commonly present with pheochromocytomas. Medullary thyroid carcinoma is a less common part of the syndrome. We describe a family with MEN2A by the RET D631Y mutation.

In 1993, the rearranged during transfection (RET) proto-oncogene germ-line mutation was discovered in multiple endocrine neoplasia type 2A (MEN2A).<sup>1</sup> The RET proto-oncogene encodes a receptor tyrosine kinase. The RET consists of the extracellular domain and the intracellular domain. The intracellular domain features the intracellular juxtamembrane segment and the tyrosine kinase domains. The extracellular domain features four repeats of cadherin-like domains and one cysteine-rich domain. RET kinase has important roles in neuronal populations of the central nervous system, parasympathetic enteric neurons of the myenteric plexus, and submucosal plexus.

An activating germline mutation in the RET proto-oncogene results in MEN2A.<sup>2</sup> MEN2A, a rare autosomal dominant endocrine disorder, has several features such as, medullary thyroid carcinoma (MTC), pheochromocytoma, and/or primary hyperparathyroidism (HPT).<sup>3</sup> More than

90% of carriers with an RET mutation will develop MTC and 25% ~ 80% will develop pheochromocytoma according to age.<sup>1,3</sup>

RET mutations are divided into three risk levels according to the penetrance, aggressiveness, and latency of MTC.<sup>3</sup> In the highest-risk category, patients with MEN2B should undergo thyroidectomy in their first year of life. In the high-risk category, thyroidectomy should be performed at the age of 5 years. In the moderate category, prophylactic thyroidectomy is performed based on the increasing trend of serum levels of calcitonin rather than genotype.

Mutations in RET codon 631 are very rare and associated with MEN2A in which there is an aspartic acid to tyrosine amino acid substitution at codon 631 in exon 11. In contrast, a half of the patients with the D631Y mutation presented with pheochromocytoma and 30% with MTC.<sup>4,5</sup> This mutation has been categorized as the American Thyroid Association (ATA) moderate risk.<sup>3</sup>

We here report a case of a 35-year-old man with pheochromocytoma and the RET proto-oncogene mutation at codon 631.

This study was conducted in accordance with the Declaration of Helsinki (as revised in 2013). The study participants gave consent to have their data published.

This is an open access article under the terms of the Creative Commons Attribution-NonCommercial-NoDerivs License, which permits use and distribution in any medium, provided the original work is properly cited, the use is non-commercial and no modifications or adaptations are made.

© 2021 The Authors. *Clinical Case Reports* published by John Wiley & Sons Ltd.

## 2 | CASE PRESENTATION OF THE INDEX PATIENT

A 35-year-old man presented with bilateral adrenal nodules on abdomen computed tomography (CT) for health screenings. He did not present with headache, sweating, and dizziness. He had sometimes high blood pressure but normal on 24 hr blood pressure checks. He had never been diagnosed as other diseases.

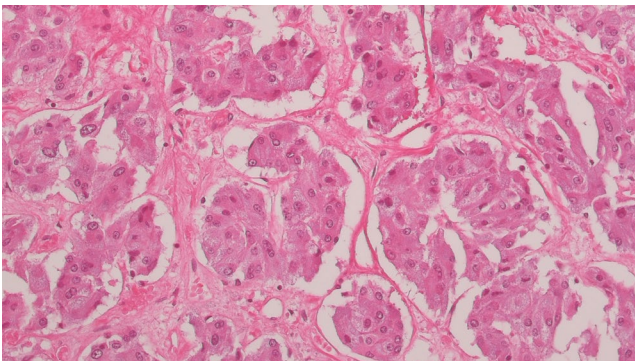
The urinary metanephrine and vanillylmandelic acid (VMA) excretions were 4.4 mg/day (normal,  $\leq 0.8$ ) and 11.8 mg/day (normal, 0 ~ 8.0), respectively, in the samples collected for 24 hours. The serum calcitonin level was 4.3 pg/mL (normal,  $< 11.8$ ), the serum intact PTH level was 33.26 pg/mL (normal, 15.0 ~ 65.0), and the serum carcinoembryonic antigen (CEA) level was not checked. Abdominal CT showed heterogeneously enhanced bilateral adrenal masses with clear margins (right side size, 4.2 cm; left side size, 2 cm).  $^{123}\text{I}$ -meta-iodobenzylguanidine (MIBG) scintigraphy was not performed.

He underwent surgery for bilateral adrenalectomy. The pathologic examination revealed bilateral pheochromocytoma (Figure 1).

The genetic mutation analysis developed, and its performance characteristics determined by the department of Laboratory medicine & Genetics, Samsung Medical Center, was performed using direct sequencing (total 6 exons: 10, 11, 13, 14, 15, 16) on genomic DNA extracted from the peripheral blood leukocytes. He was found to have a germline mutation in the RET gene, D631Y (Table 1).

He underwent prophylactic total thyroidectomy. The pathologic examination did not reveal any abnormality of both thyroid glands.

The patient's father underwent unilateral adrenalectomy when he was 64-year-old. We suggested that he could have pheochromocytoma, but have not been confirmed.



**FIGURE 1** Photomicrograph of hematoxylin-eosin-stained tumor tissue at  $\times 200$  magnification revealing a nested growth pattern and a well-vascularized stroma

**TABLE 1** RET proto-oncogene mutation analysis. The sequence GAC encoding Asp is changed to the sequence TAC encoding Tyr in codon 631 of the RET proto-oncogene

Exon	Chromosome	cDNA change	Amino acid change
11	43	c.1891G>T	p. Asp631Tyr

The patient's 6-year-old daughter was positive for the RET D631Y mutation. However, she had no evidence of pheochromocytoma, MTC, or hyperparathyroidism.

## 3 | DISCUSSION

The RET D631Y mutation is rare and classified as moderate risk of aggressive MTC by American Thyroid Association.<sup>3</sup>

We analyzed previous case reports about the RET D631Y mutation (Table 2). There were two families' reports for Caucasian. Ospina et al reported a 24-year-old man had the RET D631Y mutation, unilateral pheochromocytoma, no MTC, and no HPT. Of twelve members tested the RET mutation analysis of his family, 10 members were carrier. Four members had unilateral pheochromocytoma and no MTC. One member, the oldest 79-year-old woman, had 0.3 cm-sized MTC. None of them had HPT.<sup>6</sup> Elston et al reported a 43-year-old woman underwent right adrenalectomy because of right pheochromocytoma, and three years later, left pheochromocytoma was found. Sixteen years later, she had the RET D631Y mutation. At that time, her calcitonin level was normal. Twenty-six years later, her calcitonin level elevated. She, however, refused left adrenalectomy and prophylactic total thyroidectomy. Of thirteen members tested the RET mutation analysis of her family, 7 members were carrier. Three members had unilateral pheochromocytoma. One of them had 0.1 cm-sized MTC and HPT. Another of them had C-cell hyperplasia.

There were three families' reports for Korean. Bae et al reported two families had RET D631Y mutation.<sup>4</sup> A 46-year-old woman had bilateral pheochromocytoma and 0.3 cm-sized MTC. Her iPTH level was normal. Of ten members tested the RET mutation analysis of her family, 7 members were carrier. Two members had bilateral pheochromocytoma, and two had unilateral pheochromocytoma. One of them had 0.4 cm-sized MTC. One member without pheochromocytoma had MTC. None of them had HPT. A 54-year-old woman had bilateral pheochromocytoma and 1.2 cm-sized MTC. Of eighteen members tested the RET mutation analysis of her family, 4 members were carrier.<sup>4</sup>

Kim et al reported a 60-year-old woman had bilateral pheochromocytoma and 4 cm-sized MTC.<sup>7</sup> Of five members

**TABLE 2** Summary of each family of Caucasian and Korean with MEN2A caused by RET D631Y mutation

		Index (age, sex)	Number of carrier/ number of tested family members	pheochromocytoma (bilateral)	MTC	HPT	reference
Caucasian	1	24/M	10/12	4 (0)	1	0	Ospina et al <sup>6</sup>
	2	43/F	7/13	3 (1)	1	0	Elston et al <sup>5</sup>
Korean	3	46/F	7/10	4 (2)	3	0	Bae et al <sup>4</sup>
	4	54/F	4/18	2 (2)	1	0	Bae et al <sup>4</sup>
	5	60/F	2/5	1 (1)	1	0	Kim et al <sup>7</sup>
	6	35/M	2/2	1 (1)	0	0	This case

Abbreviations: HPT, primary hyperparathyroidism; MTC, medullary thyroid carcinoma.

tested the RET mutation analysis of her family, 2 members were carrier. Further investigation was not done.<sup>7</sup>

MEN2A accounts for 95% of all types of MEN. MTC occurs almost 100%, and pheochromocytoma occurs at 50%. HPT occurs in 10%-20%. MEN2B shows MTC and pheochromocytoma similar to type 2A, but does not have HPT and shows other extra-endocrine features.<sup>8</sup> In most data, pheochromocytoma is diagnosed at the same time as MTC or after diagnosis. However, according to a report by Imai et al, when 144 MEN2 patients were analyzed, 17% of patients with pheochromocytoma were diagnosed before MTC.<sup>9</sup> In a French study, 15% of patients were diagnosed with pheochromocytoma before diagnosis of MTC.<sup>10</sup> In the case of the RET D631Y mutation, pheochromocytoma was usually diagnosed before the diagnosis of MTC. All the papers we reviewed showed that index patient's pheochromocytoma was diagnosed first before the diagnosis of MTC.<sup>4-7</sup>

The penetrance of pheochromocytoma in MEN2 and the age at diagnosis of pheochromocytoma seem to vary depending on the RET mutation. In the case of codon 634, 883, and 918, the penetrance also seems to be high.<sup>11</sup> These codons are also known to have high risk of aggressive MTC.<sup>3</sup> However, malignant pheochromocytoma is known to be rare in less than 5%.<sup>10</sup> After all, it is MTC that determines mortality in MEN2, so it is most important to discover and treat MTC.

The RET D631Y mutation is rare but seems to be relatively benign. It is characterized by the fact that most clinical features started with pheochromocytoma. Most of the cases diagnosed with MTC appear to be after their 30s, except for the 62-year-old patient diagnosed with 4 cm-sized MTC, who had headache and palpitation, so first was diagnosed as bilateral pheochromocytoma. After that, MTC was diagnosed.<sup>7</sup> MTC was rare or found as small size. Because it seems to be that it was first discovered with pheochromocytoma, later MTC was diagnosed by elevated serum calcitonin or stimulated calcitonin through screening of family members.

## ACKNOWLEDGMENTS

Published with written consent of the patient.

## CONFLICT OF INTEREST

None declared.

## AUTHOR CONTRIBUTIONS

Jung Min Kim: prepared, wrote, and proofread the manuscript.

## DATA AVAILABILITY STATEMENT

All data relevant to the study are included in the article.

## ORCID

Jung Min Kim  <https://orcid.org/0000-0002-1848-3747>

## REFERENCES

- Salvatore D, Santoro M, Schlumberger M. The importance of the RET gene in thyroid cancer and therapeutic implications. *Nat Rev Endocrinol*. 2021;17(5):296-306.
- Mulligan LM, Kwok JBJ, Healey CS, et al. Germ-line mutations of the RET proto-oncogene in multiple endocrine neoplasia type 2A. *Nature*. 1993;363(6428):458-460. <http://dx.doi.org/10.1038/363458a0>
- Wells SA Jr, Asa SL, Dralle H, et al. Revised American Thyroid Association guidelines for the management of medullary thyroid carcinoma. *Thyroid*. 2015;25(6):567-610. <http://dx.doi.org/10.1089/thy.2014.0335>
- Bae SJ, Kim DJ, Kim JY, et al. A rare extracellular D631Y germ-line mutation of the RET proto-oncogene in two Korean families with multiple endocrine neoplasia 2A. *Thyroid*. 2006;16(6):609-614. <http://dx.doi.org/10.1089/thy.2006.16.609>
- Elston MS, Meyer-Rochow GY, Holdaway I, Conaglen JV. Patients with RET D631Y mutations most commonly present with pheochromocytoma and not medullary thyroid carcinoma. *Horm Metab Res*. 2012;44(5):339-342.
- Ospina NS, Maraka S, Donegan D, Morris JC. Clinical Features of a Family with Multiple Endocrine Neoplasia Type 2A Caused by the D631Y RET Mutation. *Thyroid*. 2017;27(10):1332-1334. <http://dx.doi.org/10.1089/thy.2016.0536>
- Kim JH, Jeon EK, Kim KH, et al. Two cases of RET proto-oncogene mutation in multiple endocrine neoplasia type 2a. *Korean J Intern Med*. 2007;73:S994-S1002. <https://www.ekjm.org/current/index.php?vol=73&no=3>
- Hofstra RM, Landsvater RM, Ceccherini I, et al. A mutation in the RET proto-oncogene associated with multiple endocrine

- neoplasia type 2B and sporadic medullary thyroid carcinoma. *Nature*. 1994;367(6461):375-376. <http://dx.doi.org/10.1038/367375a0>
9. Imai T, Uchino S, Okamoto T, et al. High penetrance of pheochromocytoma in multiple endocrine neoplasia 2 caused by germ line RET codon 634 mutation in Japanese patients. *Eur J Endocrinol*. 2013;168(5):683-687. <http://dx.doi.org/10.1530/eje-12-1106>
  10. Castinetti F, Qi XP, Walz MK, et al. Outcomes of adrenal-sparing surgery or total adrenalectomy in pheochromocytoma associated with multiple endocrine neoplasia type 2: an international retrospective population-based study. *Lancet Oncol*. 2014;15(6):648-655. [http://dx.doi.org/10.1016/s1470-2045\(14\)70154-8](http://dx.doi.org/10.1016/s1470-2045(14)70154-8)
  11. Vincent A, David T, Carole G, et al. MEN2-related pheochromocytoma: current state of knowledge, specific characteristics in MEN2B, and perspectives. *Endocrine*. 2020;69(3):496-503. <http://dx.doi.org/10.1007/s12020-020-02332-2>

**How to cite this article:** Kim JM. A patient with RET D631Y mutation present with pheochromocytoma. *Clin Case Rep*. 2021;9:e04423. <https://doi.org/10.1002/ccr3.4423>