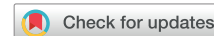

# Is it feasible to perform permanent left bundle branch area pacing, guided only by an electroanatomical mapping system? Proposal of a zero-fluoroscopy approach



Giovanni Coluccia, MD, Michele Accogli, MD, Vincenzo Panico, RN, Cesario Sergi, RN, Alessandro Guido, MD, Pietro Palmisano, MD

From the Cardiology Unit, “Card. G. Panico” Hospital, Tricase, Italy.

## Introduction

Left bundle branch area pacing (LBBAP) has emerged as a promising alternative of conduction system pacing, both for patients with conventional pacing indications and for candidates to cardiac resynchronization therapy.<sup>1</sup>

Radiation exposure represents one of the major concerns when dealing with a potentially complex procedure and specific patient categories, in which X-rays should be mandatorily reduced as much as possible, or even avoided.

To the best of our knowledge, only very few cases of LBBAP have been reported in the literature so far that have been performed under the guidance of an electroanatomical mapping system.<sup>2–5</sup> However, among the reported cases, the operators did not abolish fluoroscopy, using it in several of the procedure steps, with a non-negligible range of radiation time between 88 and 840 seconds<sup>2–4</sup>; or they avoided it, at the expense of using the additional imaging method of intracardiac echocardiography.<sup>5</sup>

Our aim was to test whether it is feasible and safe to carry out a procedure of dual-chamber pacemaker implantation, including permanent LBBAP, guided only by an electroanatomical mapping system, in such a way as to reduce to zero the fluoroscopy use for lead placement and fixation.

## Case report

An 84-year-old man was referred to our hospital for permanent pacemaker implantation, after recurrent traumatic unpredictable syncopal episodes and symptomatic high-grade paroxysmal atrioventricular blocks revealed by an implanted

**KEYWORDS** Left bundle branch area pacing; Zero-fluoroscopy; Conduction system pacing; Electroanatomical mapping system; Physiological pacing (Heart Rhythm Case Reports 2022;8:233–237)

**Funding Sources:** This research did not receive any specific grant from funding agencies in the public, commercial, or not-for-profit sectors. **Conflict of Interest:** The authors have no conflicts to disclose. **Address reprint requests and correspondence:** Dr Giovanni Coluccia, Cardiology Unit, “Card. Giovanni Panico” Hospital, Via S. Pio X, 73039 Tricase, Italy. E-mail address: [messapus@gmail.com](mailto:messapus@gmail.com).

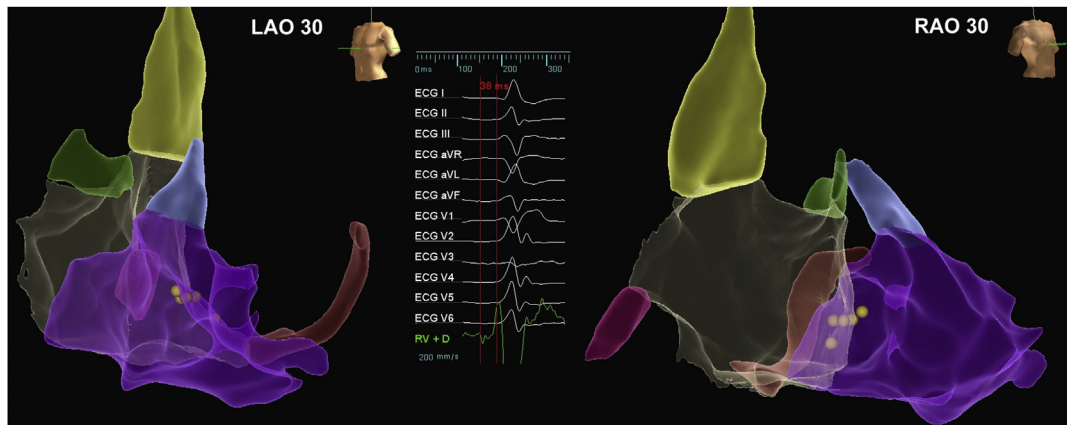
## KEY TEACHING POINTS

- Very few cases of left bundle branch area pacing performed under the guidance of an electroanatomical mapping system have been reported in the literature so far, but generally the operators did not abolish fluoroscopy, using it in several of the procedure steps, or they avoided it at the expense of using the additional imaging method of intracardiac echocardiography.
- Using an electroanatomical mapping system and a meticulous method allows to perform catheter deployments and fixations while completely avoiding X-rays and contrast angiography.
- A zero-fluoroscopy approach to left bundle branch area pacing is feasible and could represent a viable option in select patients requiring obligatory reduction or avoidance of ionizing radiation.

loop recorder. Baseline electrocardiogram presented sinus rhythm, normal PR interval, and complete right bundle branch block. On echocardiography, a mild left ventricular hypertrophy with mild systolic dysfunction (ejection fraction = 0.48) was seen. Laboratory tests showed unremarkable findings.

Given the expectedly high percentage of ventricular pacing required in the long term, in order to reduce the risk of pacing-induced cardiomyopathy, we planned to perform an LBBAP procedure and, after obtaining signed consent from the patient, we decided to carry it out under the guidance of the 3-dimensional mapping system EnSite Precision (Abbott Inc, St Paul, MN).

At our institution, there was an ongoing program of zero- or near-zero-fluoroscopy permanent cardiac pacing using this mapping system (with over 30 successful cases already



**Figure 1** Left (LAO, on the left panel) and right (RAO, on the right panel) anterior oblique projections of the electroanatomical map obtained with the diagnostic decapolar catheter, using the Abbott EnSite Precision mapping system (Abbott Inc, St Paul, MN). In the central panel, the His bundle potential is shown (green electrogram), together with baseline spontaneous QRS complex morphology. Yellow dots indicate His bundle cloud. Color-coded structures: yellow = superior vena cava; lilac = inferior vena cava; gray = right atrium; green = right atrial appendage; red = coronary sinus; purple = right ventricle; blue = right ventricular outflow tract.

performed); the operators performing the procedure had extensive experience in conduction system pacing (specifically, the primary operator had already performed over 50 cases of fluoroscopy-guided successful LBBAP implantations) and in zero-fluoroscopy catheter ablations.

After having obtained a double left subclavian vein access without using fluoroscopy and without ultrasound guidance, using only the classical surface anatomical landmarks, a steerable decapolar diagnostic catheter was introduced therein and used to recreate a gross anatomy of the superior and inferior venae cavae of the right atrium, including its appendage; of the coronary sinus; and of the right ventricle, including the very first portion of its outflow tract. Special care was applied to depict the area where His bundle potentials were found (Figure 1).

At this point, a SelectSecure 3830 lead, within a C315His delivery catheter (both from Medtronic, Minneapolis, MN), was advanced in the venous sheath and then visualized in the mapping system by means of unipolar cathode connection.

The 3830 lead and subsequently also the atrial lead were connected directly to the mapping system using a sterile cable with alligator clips; jump cables were used to further connect them to the pacing system analyzer and to the electrophysiology recording system (EMS-XL, Mennen Medical Ltd, Rehovot, Israel).

Always without fluoroscopy guidance, the 3830 lead was placed at the site of distal His bundle potential recording (HV interval = 38 ms) and then advanced 15 mm on the right ventricular side of the septum (according to the method described by Huang and associates<sup>6</sup>), where a paced QRS morphology with “W” pattern was present in lead V<sub>1</sub> (Figure 2A).

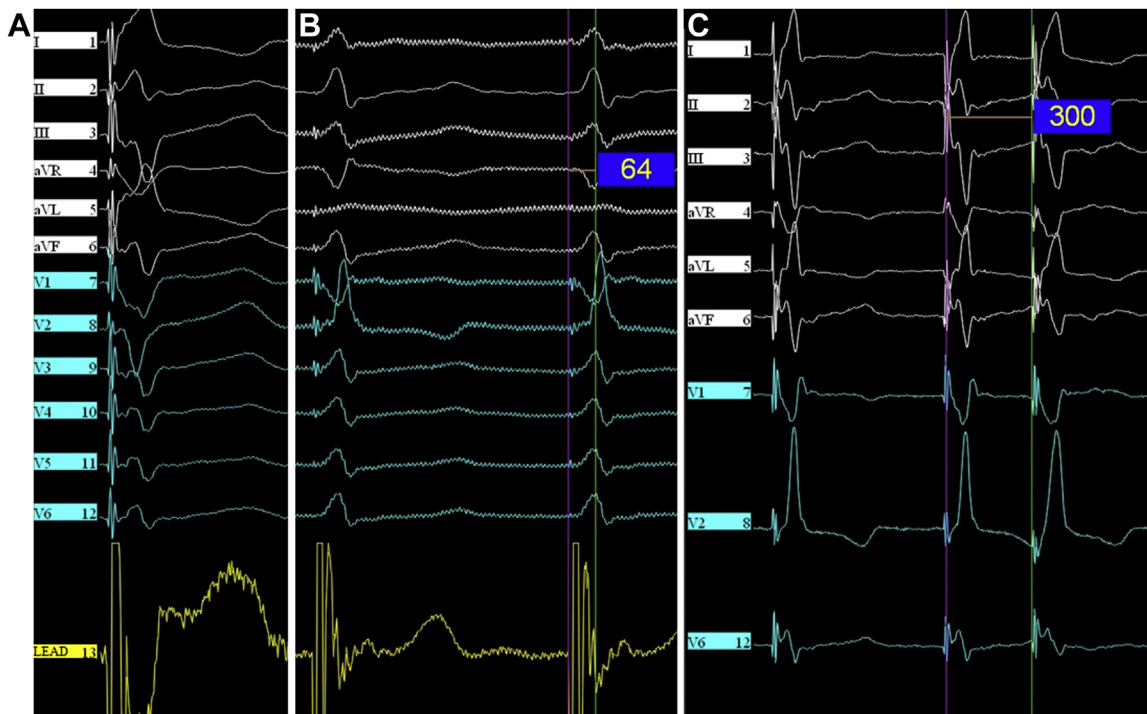
At this point, the delivery catheter was maintained rotated about 90 degrees counterclockwise, to perpendicularly approach the septum, and we started screwing the lead by means of subsequent rapid clockwise rotations. The lead advancement inside the septum was visualized in a cranial left anterior oblique projection within the mapping system,

using a continuous unipolar connection of the cathode and intermittently delivering pacing stimuli to verify the changes in paced QRS morphology (Supplemental Video). The continuous unipolar connection of the cathode during lead rotations was made possible by cutting away the alligator clip of the cathode cable and wrapping the resulting wires around the corresponding lead pin electrode in such a way as to obtain a kind of revolving adapter, as previously described by Jastrzębski and Moskal<sup>7</sup> (Supplemental Figure 1A).

Screwing was stopped once the unipolar-paced QRS showed a right bundle branch block morphology (Qr complex in lead V<sub>1</sub>), with a constantly short R-wave peak time in lead V<sub>6</sub> (64 ms), both with high and low outputs (capture threshold = 0.5 V at 0.4 ms pulse width) (Figure 2B). There, a small sharp potential, anticipating local ventriculogram, of about 15 ms was seen; R-wave amplitude was 8 mV and unipolar pacing impedance was 786 ohms. Unipolar pacing at high output from the lead anode produced ventricular capture, with a paced QRS morphology similar to that of the initial screwing point on the right ventricular surface of the septum. Programmed unipolar tip stimulation<sup>8</sup> was also performed and confirmed the nonselective left bundle branch capture obtained (effective refractory period of the left bundle branch = 300 ms) (Figure 2C). The mapping system allowed to measure a distance of 13 mm between the final lead-tip site and the site of initial screwing.

At this point, the delivery catheter was gently retracted to allow visualization of the lead in bipolar fashion, and then it was slit using a standard cutting knife, without incidents and without fluoroscopy. Electrical parameters remained stable after slitting, so the lead body was then slightly advanced to provide a supposed adequate slack, in such a way as to observe a residual extravascular portion that was comparable to that measured immediately after lead deployment.

Once the sleeve was sutured, the active-fixation atrial lead (CapSureFix Novus 4076-52 cm, Medtronic, Minneapolis, MN) was inserted and visualized in bipolar fashion within



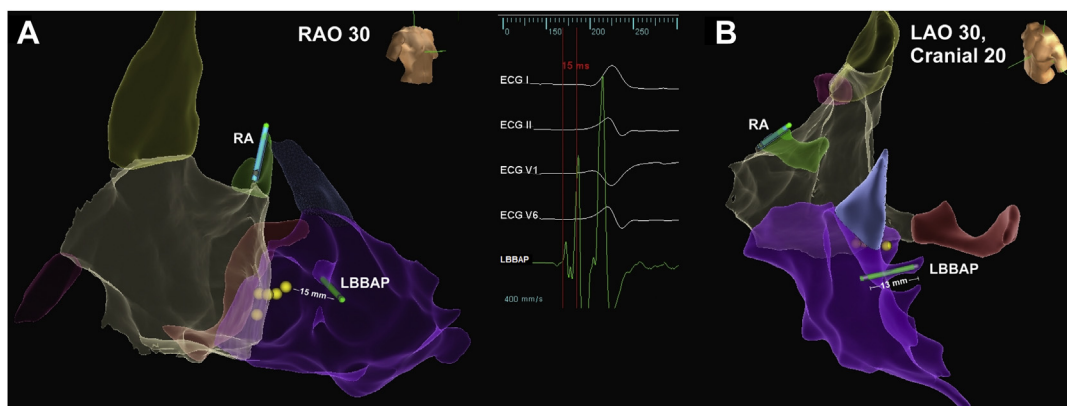
**Figure 2** A: Paced QRS morphology at the initial screwing point on the right ventricular surface of the septum; a “W” pattern in  $V_1$  is seen. B: Paced QRS morphology at the end of screwing, with nonselective left bundle branch capture; stimulus-to-R-wave peak time in lead  $V_6$  is 64 ms. C: Programmed unipolar tip stimulation of the left bundle branch area lead, showing an abrupt change in paced QRS morphology at the coupling interval of 300 ms, suggesting transition to left ventricular septal myocardial capture (thus confirming nonselective left bundle branch capture obtained).

the mapping system. A standard J-curve stylet was used to direct the lead tip inside the right atrial appendage, as previously identified during the electroanatomical mapping. Once acceptable electrical parameters were verified, the screw was extended by applying 15 clockwise rotations on the cathode pin of the lead (the manufacturer recommends fewer than 17 turns for that lead model, using a J-shaped stylet) and proper embedding inside the atrial myocardium was confirmed by both observing lead stability after stylet removal and measuring a diagnostic variation in bipolar pacing impedance values (from 2860 [before screwing] to 533 ohms), together

with good sensing and capture threshold values (2.8 mV and 0.5 V at 0.4 ms pulse width, respectively).

To obtain a presumably adequate slack, first the atrial lead was carefully retracted until the anode appeared at least at the same level of the tip, so that redundant lead loops could be reasonably excluded. At this point the lead body was readvanced in such a way as to obtain an appropriate, J-shaped slack, as presumed observing the subsequent variations in the anode position (Figure 3).

After atrial lead sleeve suture, before the catheters were connected to a dual-chamber pacemaker (Azure S DR;



**Figure 3** A, B: Right anterior oblique projection (RAO, A) and a cranial view of the left anterior oblique projection (LAO, B) of the electroanatomical map, showing the final positions of the implanted atrial and left bundle branch area pacing lead tips (RA and LBBAP, respectively), in bipolar visualization, together with the bipolar electrogram of the LBBAP lead, showing a small sharp potential anticipating local ventriculogram of 15 ms. Yellow dots indicate His bundle cloud. Color-coded structures: yellow = superior vena cava; lilac = inferior vena cava; gray = right atrium; green = right atrial appendage; red = coronary sinus; purple = right ventricle; blue = right ventricular outflow tract.

Medtronic, Minneapolis, MN), the patient was centered in the fluoroscopy field to acquire a single-shot (less than 1 s) X-ray evaluation of the leads' slacks (Supplemental Figure 1B). They appeared adequate for both leads, so the implant procedure was terminated, the leads were connected to the can, and the pocket was closed, with an overall procedure time of 100 minutes.

The patient was discharged the day after the procedure, without complications. At 3-months follow-up visit, the patient was doing well and did not report syncopal recurrences, and all pacemaker parameters were good and stable; a ventricular pacing percentage of 35% was noted, in AAI-DDD mode.

## Discussion

His bundle pacing and LBBAP represent approaches to deliver physiological pacing. In general, conduction system pacing procedures under fluoroscopic guidance entail a longer procedure time and higher fluoroscopy exposure, with respect to conventional right ventricular pacing. High fluoroscopy exposure may significantly increase the risk of cancer or genetic abnormality for both patients and implanters. The use of nonfluoroscopic 3-dimensional mapping systems has been proposed to facilitate the localization of the target regions and the identification of optimal pacing sites.

Case series and observational and case-control studies,<sup>9–13</sup> mainly regarding His bundle pacing, have shown that this approach allows to minimize procedure and fluoroscopy times compared to the conventional fluoroscopy-guided approach. In published experiences of His bundle pacing with the guidance of a mapping system, the use of fluoroscopy was dramatically reduced but not completely eliminated (with very few exceptions<sup>14</sup>), as minimal fluoroscopy was used in some phases of the procedure, such as the vein puncture, the lead screwing, the delivery catheter slitting, the implantation of others leads, and the adjustment of the tension and the final position of the implanted leads.<sup>9–13</sup>

In LBBAP, the mapping system allows to precisely choose the site of lead implantation by measuring the distance of the initial lead screwing point from the His bundle potential recording sites and also the depth of lead advancement from that point, inside the interventricular septum. The ability to have multiple and contemporary views of different projections makes it possible to follow every step of the leads' deployment in a precise and detailed way.

It is known that a potential limitation of the currently available technology is that lead slack cannot be directly visualized in the mapping system. However, it can be inferred by a careful comparative evaluation of the length of the lead body outside the pocket in the various phases of the procedure (as in the case of the LBBAP lead) or by an accurate assessment of changes in the position of the ring electrode during gentle manipulations of the lead body (as in the case of the atrial lead).

For the sake of safety, we performed a single-shot fluoroscopy evaluation of the leads before closing the pocket, to also have a direct visualization of their entire course, in addition to the simple assessment of lead tips in the virtual geometry, since it is known that an abnormal shape of lead slack can significantly influence pacing parameters. In our case, no subsequent change in lead slack was necessary, but we believe that only few seconds of fluoroscopy could be enough, in case of needed adjustments.

## Conclusion

The use of an electroanatomical mapping system and the method described allowed us to perform catheter deployments and fixations while completely avoiding the use of ionizing radiation and contrast angiography, suggesting that this approach is feasible and could represent a viable option in select patients requiring obligatory reduction or avoidance of ionizing radiation.

The additional costs of employing an electroanatomical mapping system entail financial implications in terms of reimbursements for pacemaker implantation, which are generally low, and thus currently represent an important limitation toward a widespread utilization of mapping systems in implantation procedures. Further focused investigation is necessary to better assess the cost-effectiveness of this approach.

## Appendix Supplementary data

Supplementary data associated with this article can be found in the online version at <https://doi.org/10.1016/j.hrcr.2021.12.019>.

## References

1. Ponnusamy SS, Arora V, Nambodiri N, Kumar V, Kapoor A, Vijayaraman P. Left bundle branch pacing: a comprehensive review. *J Cardiovasc Electrophysiol* 2020;31:2462–2473.
2. Vijayaraman P, Panikkath R, Mascarenhas V, Bauch TD. Left bundle branch pacing utilizing three dimensional mapping. *J Cardiovasc Electrophysiol* 2019;30:3050–3056.
3. Ponnusamy SS, Bopanna D, Kumar S. Electroanatomical mapping-guided low fluoroscopy left bundle branch pacing. *JACC Clin Electrophysiol* 2020;6:1045–1047.
4. Baman JR, Garg V, Kalluri AG, et al. Physiologic lead placement with electroanatomic mapping: a case series. *J Cardiovasc Electrophysiol* 2021.10.19; <https://doi.org/10.1111/jce.15266>.
5. Molina-Lerma M, Tercedor-Sánchez L, Álvarez M. Electroanatomic mapping and intracardiac echocardiography-guided approach for left-bundle branch area pacing with zero fluoroscopy. *CJC Open* 2020;2:705–707.
6. Huang W, Chen X, Su L, Wu S, Xia X, Vijayaraman P. A beginner's guide to permanent left bundle branch pacing. *Heart Rhythm* 2019;16:1791–1796.
7. Jastrzębski M, Moskal P. Reaching the left bundle branch pacing area within 36 heartbeats. *Kardiol Pol* 2021;79:587–588.
8. Jastrzębski M, Moskal P, Bednarek A, et al. Programmed deep septal stimulation: a novel maneuver for the diagnosis of left bundle branch capture during permanent pacing. *J Cardiovasc Electrophysiol* 2020;31:485–493.
9. Sharma PS, Huang HD, Trohman RG, Napierkowski A, Ellenbogen KA, Vijayaraman P. Low fluoroscopy permanent His bundle pacing using electroanatomic mapping: a feasibility study. *Circ Arrhythm Electrophysiol* 2019;12:e006967.
10. Kristensen J, Kronborg MB, Gerdes C, Nielsen JC. Electroanatomical mapping- and CT scan image integration-guided pacing lead implantation: a case series and review of the recent literature. *Heart Rhythm O2* 2020;1:341–350.

11. Orlov MV, Koulouridis I, Monin AJ, et al. Direct visualization of the His bundle pacing lead placement by 3-dimensional electroanatomic mapping: technique, anatomy, and practical considerations. *Circ Arrhythm Electrophysiol* 2019; 12:e006801.
12. Imnadze G, Vijayaraman P, Bante H, et al. Novel electroanatomical map for permanent His bundle pacing: the Mont Blanc approach - influence of the learning curve and procedural outcome. *Europace* 2020;22:1697–1702.
13. Hu Y, Ding L, Hua W, et al. Comparison between His-bundle pacing guided by Ensite NavX system and conventional fluoroscopy. *J Interv Card Electrophysiol* 2020;57:107–114.
14. Coluccia G, Accogli M, Guido A, et al. Concomitant His bundle pacing and atrio-ventricular junction ablation: feasibility of a three-dimensional mapping system-only-guided, zero-fluoroscopy approach. *J Cardiovasc Med (Hagerstown)* 2021; 22:e21–e23.