

A Digital Stereomicroscopic Study of the Radicular Wall Thickness of Two-Canal Mandibular Incisors

Sedigheh Khedmat¹, Sohayla Mohamadian², Fatemeh Dibaji³✉, Mohamad Javad Kharrazifard⁴

¹Professor, Dental Research Center, Dentistry Research Institute, Tehran University of Medical Sciences, Tehran, Iran; Department of Endodontics, Faculty of Dentistry, Tehran University of Medical Sciences, Tehran, Iran; Iranian Center for Endodontic Research, Tehran, Iran

²Undergraduate Student, School of Dentistry, International Campus of Tehran University of Medical Sciences, Tehran, Iran

³Assistant Professor, Department of Endodontics, School of Dentistry, International Campus of Tehran University of Medical Sciences, Tehran, Iran

⁴Epidemiologist, Dental Research Center, Dentistry Research Institute, Tehran University of Medical Sciences, Tehran, Iran

Abstract

Objectives: This study aimed to assess the radicular wall thickness in mandibular incisors with two canals and find the maximum and minimum thickness to prevent root canal treatment (RCT) procedural errors.

Materials and Methods: A total of 160 extracted mandibular incisors were selected and radiographed; out of which, 55 had two canals. Three parallel transverse sections were made in each tooth at 1mm below the cemento-enamel junction (CEJ), mid-root and 1 millimeter to the apex. Specimens were evaluated under a stereomicroscope and the thickness of radicular walls in each section was determined for the buccal, lingual and proximal surfaces. Data were statistically analyzed using Pearson's correlation coefficient test.

Results: The thickness of radicular wall decreased from the cervical towards the apex. In all three sections (cervical, mid-root and apical), the thickness of lingual wall was significantly greater than the buccal wall. Also, the thickness of buccal and lingual walls was significantly higher than that of the proximal walls.

Conclusion: The lingual radicular wall had the highest thickness in two-canal mandibular incisors. Therefore, in these teeth, the lingual canal is a better choice for post placement.

Key words: Root Canal; Dentin; Thickness; Tooth Root

Journal of Dentistry, Tehran University of Medical Sciences, Tehran, Iran (2015; Vol. 12, No. 7)

✉ Corresponding author:

F. Dibaji, Department of Endodontics, School of Dentistry, International Campus of Tehran University of Medical Sciences, Tehran, Iran

fmdibaji@gmail.com

Received: 27 January 2015

Accepted: 26 March 2015

INTRODUCTION

A successful Root Canal Treatment (RCT) highly depends on the knowledge of clinicians about the anatomy of the root canal system. Many of the failures are due to inadequate knowledge, not finding the second canal and not knowing the thickness of root canal walls and lead to procedural errors such as root perforation during instrumentation and vertical root fracture (VRF) during post space preparation [1,2].

Root canal form, external morphology of the root and root dentin thickness affect the location and direction of VRFs and increase their risk of occurrence [3,4]. Chen et al, [5] in a 5-year follow-up of root filled teeth reported that the prevalence of vertical root fracture was 32.1%.

Many researchers have investigated the anatomy of root canal system in the mandibular incisors regarding the number of root canals.

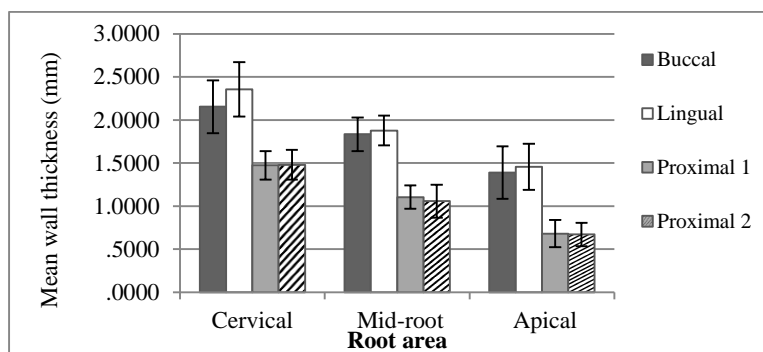


Fig. 1. The mean wall thickness at the buccal, lingual and proximal areas at three levels of the teeth. Bars represent standard deviations.

According to previous studies, the incidence of mandibular incisors with two canals varied from 27% to 50% [2,6-8].

Data regarding the thickness of radicular walls in mandibular incisors are scarce. In a study by Bellucci and Perrini, the thickness of radicular dentin and cementum was evaluated in the anterior and premolar teeth including the mandibular central incisors with a single canal. The highest thickness was reported in the lingual and the lowest in the proximal walls [9]. It is logical that in mandibular central incisors with two canals in only one root, the radicular wall thickness of each canal decreases. Canal preparation and post space preparation decrease the thickness of dentin and radicular walls. Caputo and Standlee suggested that at least one millimeter of root dentin should remain around the post to avoid the risk of root fracture [10].

There are no data about the thickness of radicular walls in the two-canal mandibular incisors especially in an Iranian population. This study aimed to assess the radicular wall thickness of two-canal mandibular incisors to determine the thickest and the thinnest areas and provide some information regarding the internal anatomy of the root canal system to prevent procedural errors.

MATERIALS AND METHODS

Due to the lack of a similar study, first a pilot study on 10 mandibular incisors with two canals was carried out.

A total of 160 extracted mandibular incisors were radiographed from the mesiodistal dimension; out of which, 55 teeth with two canals were selected according to the inclusion and exclusion criteria. These teeth had been extracted due to periodontal disease and age, gender and history of systemic disease in patients were not known. The teeth were free from caries and external resorption and did not have root curvature. The surfaces of the selected teeth were cleaned using Cavitron and hand scalers. The teeth were then immersed in 5.25% sodium hypochlorite solution for 30 minutes for disinfection and soft tissue elimination [7,11].

The teeth were stored in saline solution until the experiment. Buccal and lingual surfaces of the teeth were marked using durable markers of different colors.

The roots were measured using a millimeter-scale ruler and three areas were marked for sectioning. Three one millimeter-thick transverse sections were made of each root at one millimeter below the orifices, at mid-root and one millimeter to the apex in a parallel fashion and perpendicular to the long axis of the tooth. The teeth were mounted in cylindrical molds containing clear polyester resin (Acropars, Tehran, Iran) designed for hard tissue sectioning by high-speed cutting machine.

The sections were separated from the acrylic resin and individually immersed in saline solution.

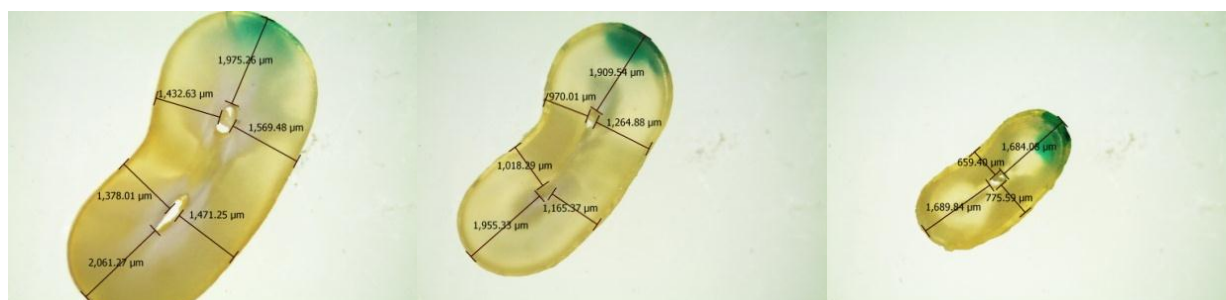


Fig. 2. Three transverse sections of cervical, mid-root and apical areas (type II)

The specimens were evaluated from the coronal side under a stereomicroscope (EZ4D, Leica, Germany) equipped with a 3D digital camera under $\times 12.5$ magnification. The images were assessed by the device software (LAS E2 software) with the ability to measure and analyze the specimens. Radicular wall thickness in the sections was measured from the innermost canal lumen surface to the outermost root surface in the buccal, lingual, and proximals (mesial and distal walls) and reported in hundredths of a millimeter.

Data were statistically analyzed using Pearson's correlation coefficient test for evaluating the correlation between the thicknesses of radicular walls at $P=0.05$ level of significance (two – tailed).

RESULTS

The obtained results are shown in Figure 1-4. Figure 1 summarizes the mean values and standard deviations. The radicular wall thickness decreased from the cervical towards the apical. The lingual wall thickness in cervical, mid-root and apical sections was significantly greater than that of the buccal wall ($P<0.001$). Also, in the cervical sections, the thickness of lingual wall was significantly greater than the proximal walls ($P=0.007$). At mid-root, the lingual ($P=0.016$) and the buccal ($P<0.001$) wall thicknesses were greater than that of the proximal walls.

In apical sections, the buccal and lingual wall thickness was significantly greater than that of the proximal walls ($P<0.001$).

The mean thickness of the lingual wall in all three sections was significantly greater than that of the buccal wall ($P<0.001$ for cervical, $P<0.001$ for mid-root and $P<0.001$ for apical sections). In the 55 two-canal teeth, the typing of root canals according to the Vertucci's classification was as follows: Type III (1-2-1): 43 teeth (78%), type V (1-2): five teeth (9.09%), type II (2-1): five teeth (9.09%), type IV (two separated canals): one tooth (1.81%) and type VI (2-1-2): one tooth (1.81%).

DISCUSSION

Limited data are available on the radicular wall thickness especially in mandibular incisors. Radicular wall thickness is highly influenced by the internal root canal anatomy. In teeth with more than one root canal, the wall thickness is decreased. Longevity and survival of endodontically treated teeth greatly depend on the thickness of the residual dentin in the radicular wall. Numerous researchers have investigated the direct correlation between the loss of tooth structure and risk of crown and root fracture [9]. This study aimed to measure the radicular wall thickness in the mandibular central and lateral incisors. Based on the anatomical findings and the study by Bellucci and Perrini, distinguishing between these two teeth and also between the mesial and distal surfaces in the extracted right and left teeth is extremely difficult [9-13]. The mandibular incisor crowns are symmetric and roots have a slight distal angulation especially in the lateral incisors.

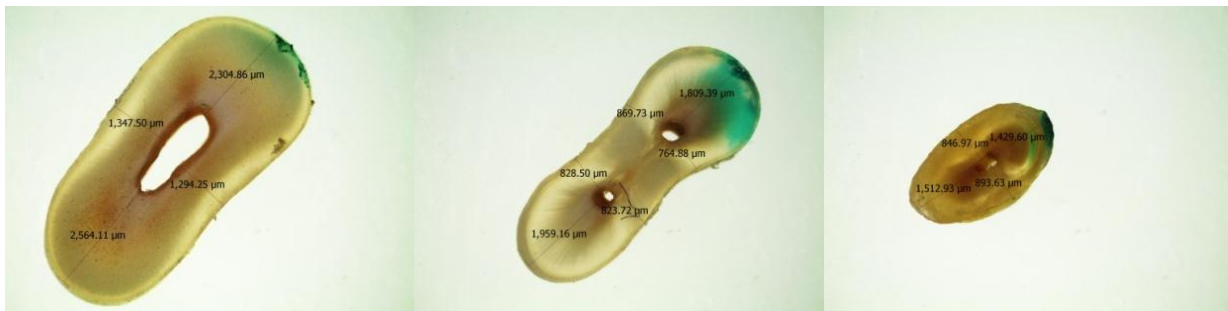


Fig. 3. Three transverse sections of cervical, mid-root and apical areas (type III)

The only characteristic distinguishing between the central and lateral incisors may be the slightly askew root of the lateral incisor causing the incisal edge to follow the dental arch curve. Also, the distoincisor angle of the lateral incisor is slightly rounded. Despite all these, distinguishing between these two teeth and the mesial and distal surfaces is difficult [9,12,13]. The purpose of this study was to assess the radicular wall thickness of two-canal mandibular incisors. Three transverse sections were made of each root at one millimeter below the orifices, mid-root and one millimeter to the apex. The cervical thickness of the root was assessed by sectioning at one millimeter below the orifices. The mid-root section was performed because radicular wall thickness decreases in this area especially when longitudinal grooves are present in the proximal surfaces.

These grooves have been reported to be present in the middle third of the radicular proximal faces [12,13]. The apical section was made at one millimeter to the apex as the end point of canal preparation, which is a critical region and over-preparation of this part results in apical perforation and over-filling. According to the results, the lingual wall thickness was greater than that of the buccal and proximal walls in all three sections (cervical, mid-root and apical). These findings are in accordance with the results of Bellucci and Perrini in the mandibular incisors with a single canal [9].

Previous studies have shown that the incidence of mandibular incisors with two canals (one in the buccal and another one in the lingual) varies from 27% to 50% [2,6-8]. Not finding the lingual canal or the second canal leads to endodontic treatment failure. In order to find this canal, the access cavity should be extended lingually in the cervical area. Canal preparation and post space preparation decrease the thickness of dentin and radicular walls [9,14]. Several biomechanical studies have suggested that at least one millimeter of dentin thickness is required around a post to prevent root fracture [10,15]. Therefore, in the mandibular incisors with two canals, the lingual canal is a better choice for post placement. During cleaning and shaping of the canal and post space preparation, care must be taken not to remove too much dentin and over-flaring should be avoided at the coronal one-third because it reduces the residual dentin thickness and increases the risk of VRF.

Based on our results and findings of Bellucci and Perrini [9], the lowest radicular wall thickness at all three sections was in the proximal walls increasing the risk of perforation at such areas.

In the apical segment, due to the low thickness of dentinal walls, preparation and shaping should be minimal and limited only to cleaning and elimination of bacteria and necrotic debris on the dentinal canal walls [14,16].




Fig. 4. Three transverse sections of cervical, mid-root and apical areas (type IV)

Thus, in order to achieve the best outcome of endodontic treatment, following the root canal anatomy and having adequate knowledge about the radicular wall thickness can be helpful especially when using intracanal rigid large-size rotary instruments [9].

CONCLUSION

This in-vitro study showed that in two-canal mandibular incisors the lingual wall thickness is higher than that of the buccal in cervical, mid-root and apical thirds. Therefore, in these teeth the lingual canal is a better choice for post placement.

ACKNOWLEDGMENTS

This research was supported by a grant from Dental Research Center, Tehran University of Medical Sciences and Health Services (no: 132/29683).

REFERENCES

- 1- Tabrizzadeh M, Reuben J, Khalesi M, Mousavinasab M, Ezabadi MG. Evaluation of radicular dentin thickness of danger zone in mandibular first molars. *J Dent (Tehran)*. 2010 Fall;7(4):196-9.
- 2- Scarlatescu S, Didilescu AC, Stratul SI, Rusu D, Grigore M, Greabu M, et al. Root canal morphology of mandibular central incisors in a South-Eastern Romanian population: Endodontic and periodontal implications. *TMJ*. 2010;60(4):280-3.
- 3- Lertchirakarn V, Palamara JE, Messer HH. Patterns of vertical root fracture: factors affecting stress distribution in the root canal. *J Endod*. 2003 Aug;29(8):523-8.
- 4- Sathorn C, Palamara JE, Palamara D, Messer HH. Effect of root canal size and external root surface morphology on fracture susceptibility and pattern: a finite element analysis. *J Endod*. 2005 Apr;31(4):288-92.
- 5- Chen SC, Chueh LH, Hsiao CK, Wu HP, Chiang CP. First untoward events and reasons for tooth extraction after nonsurgical endodontic treatment in Taiwan. *J Endod*. 2008 Jun;34(6):671-4.
- 6- Vertucci FJ. Root anatomy of the human permanent teeth. *Oral Surg Oral Med Oral Pathol*. 1984 Nov;58(5):589-99.
- 7- Kartal N, Yanikoğlu FC. Root canal morphology of mandibular incisors. *J Endod*. 1992 Nov;18(11):562-4.
- 8- Benjamin KA, Dowson J. Incidence of two root canals in human mandibular incisor teeth. *Oral Surg Oral Med Oral Pathol*. 1974 Jul;38(1):122-6.
- 9- Bellucci C, Perrini N. A study on the thickness of radicular dentine and cementum in anterior and premolar teeth. *Int Endod J*. 2002 Jul;35(7):594-606.
- 10- Caputo AA, Standlee JP. Pins and posts--why, when and how. *Dent Clin North Am*. 1976 Apr;20(2):299-311.
- 11- Shahravan A, Rekabi A, Shahabi H, Ashuri R, Mirzazadeh A, Rad M, et al. A

- digital stereomicroscopic study of the furcation wall thickness of mesiobuccal roots of maxillary first and second molars. *Iran Endod J.* 2010 Spring;5(2):88-92.
- 12- Rickne C Scheid, Julian B. Morphology of the permanent Incisors. In: *Woelfel's Dental Anatomy*, 7th ed. Lippincott Williams & Wilkins, 2007:166-7.
- 13- Geoffrey C. van Beek. The permanent Dentition. In: *Dental morphology: An illustrated guide*, 2nd ed., Elsevier, 1983:52-8.
- 14- Zuckerman O, Katz A, Pilo R, Tamse A, Fuss Z. Residual dentin thickness in mesial roots of mandibular molars prepared with Lightspeed rotary instruments and Gates-Glidden reamers. *Oral Surg Oral Med Oral Pathol Oral Radiol Endod.* 2003 Sep;96(3):351-5.
- 15- Gluskin AH, Radke RA, Frost SL, Watanabe LG. The mandibular incisor: rethinking guidelines for post and core design. *J Endod.* 1995 Jan;21(1):33-7.
- 16- Pilo R, Tamse A. Residual dentin thickness in mandibular premolars prepared with gates glidden and ParaPost drills. *J Prosthet Dent.* 2000 Jun;83(6):617-23.