

Received: 2015.07.15  
Accepted: 2015.09.03  
Published: 2016.01.04

ISSN 1941-5923  
© Am J Case Rep, 2016; 17: 1-5  
DOI: 10.12659/AJCR.895350

## A Rare Case of Toxic Myocarditis Caused by Bacterial Liver Abscess Mimicking Acute Myocardial Infarction

Authors' Contribution:  
Study Design A  
Data Collection B  
Statistical Analysis C  
Data Interpretation D  
Manuscript Preparation E  
Literature Search F  
Funds Collection G

EF **Yuhai Zou**  
B **Lin Lin**  
F **Hua Xiao**  
A **Dingcheng Xiang**

Department of Cardiology, Guangzhou General Hospital of Guangzhou Military Command, Guangzhou, Guangdong, P.R. China

**Corresponding Author:** Dingcheng Xiang, e-mail: Zouyuhai3@126.com  
**Conflict of interest:** None declared

**Patient:** Male, 66  
**Final Diagnosis:** Toxic myocarditis  
**Symptoms:** —  
**Medication:** —  
**Clinical Procedure:** Emergency  
**Specialty:** Cardiology

**Objective:** Rare disease





**Background:** Chills, high fever, right upper abdomen pain, and increased white blood cell count are the main and common clinical features of bacterial liver abscess. It is rare to see bacterial liver abscess present symptoms of myocardial injury first, and this can lead to misdiagnosis.

**Case Report:** We report a case of toxic myocarditis caused by bacterial liver abscess. The patient first presented with chest pain, ST segment elevation, and elevated TNI, which misled us to diagnose myocardial infarction, but the coronary artery had no stenosis or obstructive lesions after emergency coronary angiography. Then we modified the diagnosis to toxic myocarditis. Bacterial liver abscess was the proposed etiology after a series of auxiliary examinations. Finally, antibiotics and percutaneous liver puncture catheter drainage were used to improve the clinical outcome.

**Conclusions:** It is rare that patients with bacterial liver abscess first present symptoms of myocardial injury. Differential diagnosis between myocarditis and myocardial infarction should be careful, as myocarditis is a diagnosis of exclusion, and coronary angiography is necessary to confirm coronary disease. Percutaneous liver puncture catheter drainage can effectively cure bacterial liver abscess.

**MeSH Keywords:** Liver Abscess • Myocardial Infarction • Myocarditis

**Full-text PDF:** <http://www.amjcaserep.com/abstract/index/idArt/895350>

 1655  —  3  12



## Background

Myocarditis is an inflammatory disease of the myocardium. It is a common clinical disease. Patients with myocarditis often present symptoms of chest pain and transient ECG changes, and even life-threatening cardiogenic shock and ventricular arrhythmia. ECG presenting ST-segment elevation or depression can lead to misdiagnosis of acute coronary syndrome. Therefore, the differential diagnosis between myocarditis and myocardial infarction should be careful. Endomyocardial biopsy (EMB) is the diagnostic criterion standard for myocarditis and is often used to confirm the diagnosis and identify the type of inflammation, which indicate the definite treatments and suggests the prognosis, but EMB is not used frequently [1]. Myocarditis is a diagnosis of exclusion, and a series of auxiliary examinations, including coronary angiography, should be performed to confirm the definite diagnosis after excluding other diagnoses.

The etiology of myocarditis remains unclear; many factors, such as systemic diseases, infectious agents, toxins, and drugs, can cause the disease. Bacterial infection can cause myocarditis. Chills, high fever, elevated white blood cell, and elevated procalcitonin (PCT) are the common features of infection [2]. It is rare that chest pain, ST segment elevation, and elevated myocardium enzyme are the initial symptoms presenting in patients with bacterial infection. These symptoms can cause much confusion, leading to possible misdiagnosis and delay of definitive therapy. To address this issue, we present a clinical case of myocardial damage caused by bacterial liver abscess with symptoms of acute myocardium injury. Our aims were to conduct a comprehensive investigation of the relevant case reports, diagnosis, and treatment in the literature, to improve early diagnosis for timely initiation of clinical treatment of myocardial lesions and bacterial infection, and to improve the clinical outcomes.

## Case Report

On 14 January 2015, a 66-year-old man was admitted to the cardiology department for chest pain and transient fever for 2 days. The pain was in the back of sternum, with chest tightness, accompanied by palpitations and sweating. On admission to our department, his physical examination was unremarkable. His serum level of C-TnI had increased to 6.68 ng/mL, and his ECG showed sinus rhythm, and ST segments elevation on lead II, III and avF (Figure 1). The preliminary diagnosis of acute myocardial infarction with ST segments elevation on the inferior wall was established. An emergency coronary angiography was done, only to find that the coronary artery tree was unobstructed with no embolism or obvious stenosis, and further aortic angiography found the aorta was normal too (Figure 2). The diagnosis of acute myocardial

infarction was basically eliminated with the minor possibility of spontaneous recanalization. Myocarditis would be the right diagnosis, but the etiology was unknown. Further auxiliary examination were arranged to evaluate the patient's condition.

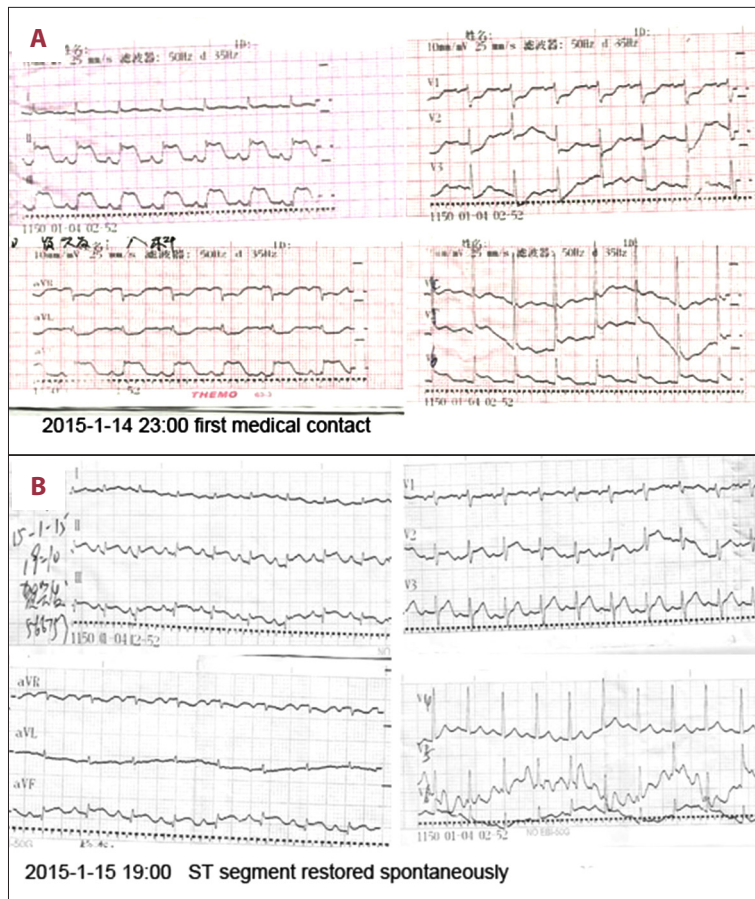
From 15 to 25 January, the patient presented slight chest tightness, shortness of breath, fatigue, low blood pressure, and body temperature remained as high as 38.5–39.5°C. Further examination showed a remarkably high serum level of PCT (>200 ng/mL), high white blood cell counts, and multiple organ dysfunction, with mild elevation of hepatic bilirubin and creatinine. Abdominal ultrasonography (Figure 3) and CT scan found a liver abscess but no liquefied matter, so we modified the diagnosis to "toxic myocarditis, liver abscess, multiple organ dysfunction, septic shock". Antibiotics imipenem and ornidazole and immunomodulatory therapy of gamma globulin was administrated against infection. Dopamine was used to stabilize the perfusion pressure. Hepatic and renal protection therapy and nutrition support were also tried, but the efficacy was not good.

On 26 January, recheck abdominal ultrasonography and CT scan found that the liver abscess has been liquefied. We immediately performed percutaneous liver puncture catheter drainage, and the pyogenic fluids were coffee-like and ropey. The pathogen was identified as *Klebsiella pneumoniae* via bacterial culture of pyogenic fluids.

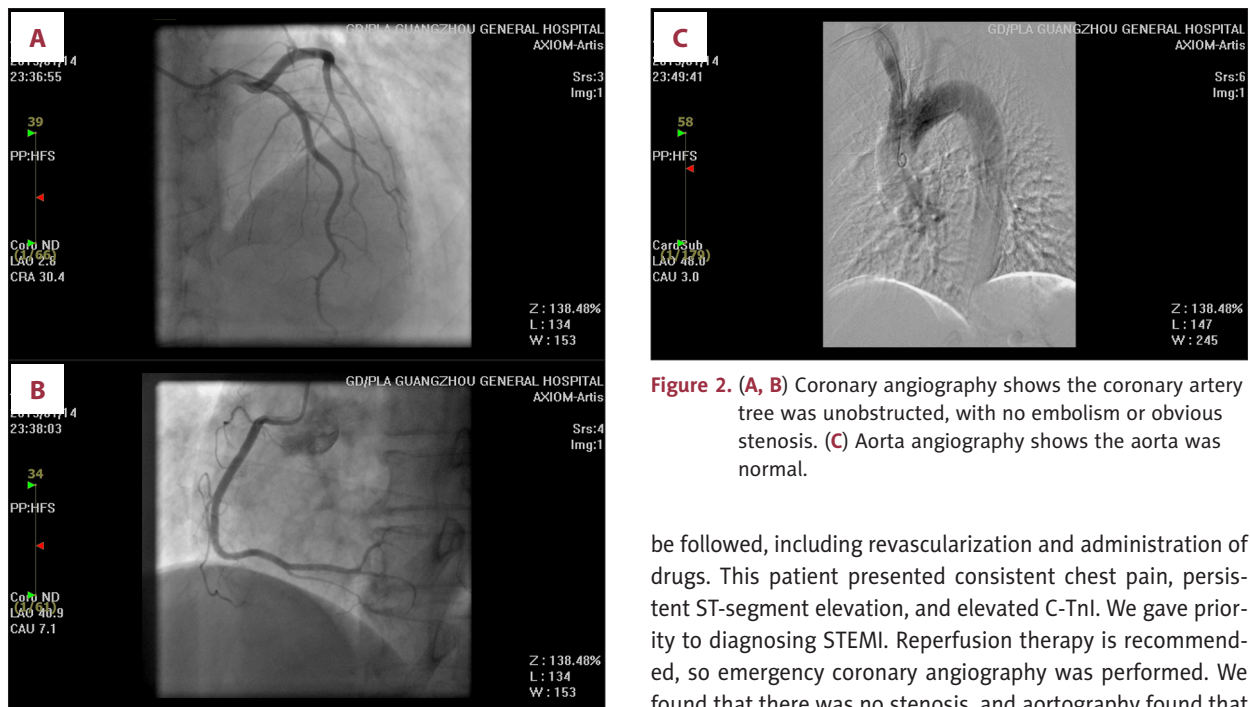
From 26 January to 5 February, the second day after drainage, the patient felt much better, and body temperature dropped to and remained within normal range. The blood pressure was normal when we stopped using dopamine. Recheck of PCT and white blood cell counts showed a decreasing infection. These treatments were continued until 5 February. Abdominal ultrasonography was performed again. We found that the liver abscess had been absorbed completely, and then the drainage tube was removed. On February 6, the patient was healthy enough to be discharged from the hospital. At 1-month follow-up, the patient had no discomfort.

## Discussion

Acute ST segment elevation myocardial infarction (STEMI) is a disease causing great morbidity. Timely implementation of reperfusion therapy is the key issue in the management of STEMI, since the greatest benefit gained from reperfusion therapy occurs within the first 2–3 hours of symptom onset, so time limitation of FMC to balloon is very important. Diagnosis of STEMI is based on clinical manifestations, dynamic changes of ECG, and elevated myocardial enzyme level [3,4]. If they match the diagnostic standard, STEMI should be considered. Timely implementation of therapy process management of STEMI should

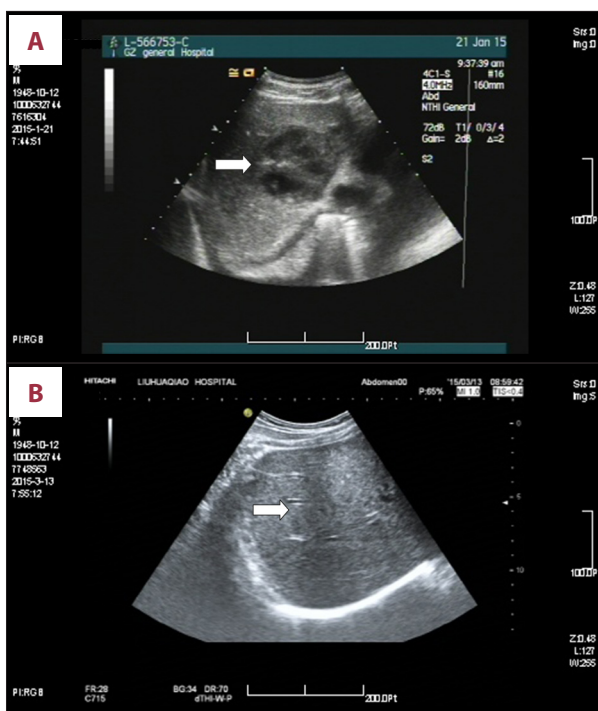


**Figure 1.** The dynamic changes of ECG: ST segments changes on leads II, III, and aVF.



**Figure 2.** (A, B) Coronary angiography shows the coronary artery tree was unobstructed, with no embolism or obvious stenosis. (C) Aorta angiography shows the aorta was normal.

be followed, including revascularization and administration of drugs. This patient presented consistent chest pain, persistent ST-segment elevation, and elevated C-Tni. We gave priority to diagnosing STEMI. Reperfusion therapy is recommended, so emergency coronary angiography was performed. We found that there was no stenosis, and aortography found that the aorta was normal. We thought that STEMI might be the wrong diagnosis. For patients with acute coronary syndrome



**Figure 3.** (A) Adominal ultrasonography found an abscess in the liver. (B) The liver abscess was absorbed completely after percutaneous liver puncture catheter drainage.

and culprit-free angiograms, Kawecki et al. recommend that cardiac magnetic resonance should be arranged if available, which would be helpful in distinguishing acute myocardial infarction from myocarditis [5,6].

Myocarditis is an inflammatory disease of the myocardium. Myocarditis is a common but challenging diagnosis, because the clinic manifestation presents in a different way and the etiology is hard to determine. Although EMB is the diagnostic criterion standard, EMB is not routinely performed. ESC is proposed as the diagnostic criteria for clinically suspected myocarditis in 2013 [1]. Myocarditis is a diagnosis of exclusion, and coronary angiography is necessary to define coronary disease. STEMI could be excluded after coronary angiography. Although EMB, the criterion standard, was not used, myocarditis could be the right diagnosis, but the etiology was uncertain because the most common causes of myocarditis are viral and bacterial infections. Additional examinations were performed to find the most likely etiology. The second day after admission, the patient had high fever, increased white blood cell count, and elevated procalcitonin. All of the clues suggested that the myocarditis was due to bacterial infection. Finally, we found a liver abscess that could be the cause of the myocarditis after CT scan and abdominal ultrasonography. The pathogen was determined to be *Klebsiella pneumoniae* through bacterial culture of pyogenic fluids, so toxic myocarditis caused by bacterial liver abscess was diagnosed. The optimal treatment approach

remains unclear. Immunoglobulin therapy should be considered for fulminant myocarditis [7].

Bacterial liver abscess is one of the most severe diseases in surgery. It is rare to see direct infection in the liver. The main and common causes of bacterial liver abscess are biliary tract diseases and bloodstream infection in the portal vein system. The most common bacteria are *Escherichia coli* and *Staphylococcus aureus*. Anaerobic bacteria are also common. Chills, high fever, right upper abdomen pain, and increased white blood cell count are the main clinical features of bacterial liver abscesses. It is rare that this patient presented primary symptoms of acute myocardial injury, which led us to misdiagnose STEMI or acute aortic syndrome. Ng CT [8] once reported a case of acute myocardial infarction accompany with fish bone-induced hepatic abscess. The hepatic abscess was finally resolved with conservative antimicrobial therapy in view of the fact that the patient was on dual antiplatelet agents. We treated the patient with conservative antimicrobial therapy and immunoglobulin therapy first, but the efficacy was not good. Percutaneous liver puncture catheter drainage was performed to improve the outcome.

Bacterial liver abscesses develop rapidly; if the diagnosis and treatment are not correct and timely, patient can die due to septicemia and infection shock. Liver abscess treatment can rely on systemic antibiotics and immunomodulatory therapy at the early stage or before liquefaction of the abscess, but it is difficult for antibiotics to enter the abscess cavity after abscess cavity formation or obvious abscess wall thickening. Drainage of the abscess should be considered. At present, the main choices are percutaneous liver puncture catheter drainage or transabdominal incision and drainage treatment [9]. Percutaneous liver puncture catheter drainage is recommended as the first choice. It is as effective as transabdominal incision and drainage treatment, and is safer and less painful. When facing such a big abscess with thick pyogenic fluids, the drainage effect of percutaneous liver puncture catheter drainage is sufficient. Transabdominal incision and drainage treatment should be performed as soon as possible [10–12]. The patient was finally diagnosed as having a bacterial liver abscess. We treated the patient with the antibiotics imipenem and ornidazole, and gamma globulin immunomodulatory therapy at the beginning, but he did not improve. Percutaneous liver puncture catheter drainage was performed after the abscess cavity formed. The clinical effect was obvious. Body temperature dropped to and remained within normal range. Blood pressure was normal. Recheck of PCT and white blood cell counts showed decreasing infection. At 1-month follow-up, abdominal ultrasonography found that the liver abscess was absorbed completely, and the patient was cured without obvious complications.

## Conclusions

Acute myocarditis is an inflammatory disease of the myocardium. The etiology of myocarditis remains undetermined, and many factors, such as systemic diseases, infectious agents, toxins, and drugs, can cause the disease. EMB is the diagnostic criterion standard, but EMB is used infrequently. Myocarditis should be diagnosed after excluding other diseases, including coronary disease. When ST segment elevates because of

myocarditis, it could lead to a misdiagnosis of STEMI. To exclude coronary disease, coronary angiography is recommended. Once myocarditis is diagnosed, the etiology should be identified as soon as possible. Toxin myocarditis caused by bacteria should be highly suspected. Auxiliary examination should be performed to find the infectious lesions and identify the pathogen, and then definitive therapy can be conducted as early as possible to improve the prognosis.

## References:

1. Caforio AL, Pankuweit S, Arbustini E et al: Current state of knowledge on aetiology, diagnosis, management, and therapy of myocarditis: a position statement of the European Society of Cardiology Working Group on Myocardial and Pericardial Diseases. *Eur Heart J*, 2013; 34 (33): 2636–48, 2648a–48d
2. Reddy G, Chatterjee A, Brott BC: Transdiaphragmatic rupture of hepatic abscess producing purulent pericarditis and pericardial tamponade. *Circulation*, 2015; 131(1): e1–2
3. StephanWindecker, Kolh P, Alfonso F et al: 2014 ESC/EACTS guidelines on myocardial revascularization. *Rev Esp Cardiol (Engl Ed)*, 2015; 68(2): 144
4. Dauerman HL, Bates ER, Kontos MC et al: Nationwide analysis of patients with ST-segment-elevation myocardial infarction transferred for primary percutaneous intervention: findings from the american heart association mission: Lifeline program. *Circ Cardiovasc Interv*, 2015; 8(5). e002450
5. Kawecki D, Morawiec B, Monney P et al: Diagnostic contribution of cardiac Magnetic Resonance in patients with acute coronary syndrome and culprit-free angiograms. *Med Sci Monit*, 2015; 21: 171–80
6. Wassmuth R, Schulz-Menger J: Cardiac magnetic resonance in acute myocarditis and dilated cardiomyopathy. *Med Sci Monit*, 2009; 15(5): RA111–15
7. Nalli C, Couture C, Bernier M et al: A rare case of fulminant myocarditis successfully treated with immunoglobulin therapy. *Am J Case Rep*, 2010; 11: 166–68
8. Ng CT, Htoo A, Tan SY: Fish bone-induced hepatic abscess: medical treatment. *Singapore Med J*, 2011; 52(3): e56–58
9. Liu CH, Gervais DA, Hahn PF et al: Percutaneous hepatic abscess drainage: do multiple abscesses or multiloculated abscesses preclude drainage or affect outcome. *Vasc Interv Radiol*, 2009; 20(8): 1059–65
10. Ahmed S, Chia CL, Junnarkar SP et al: Percutaneous drainage for giant pyogenic liver abscess-is it safe and sufficient? *Am J Surg*, 2015 [Epub ahead of print]
11. Dulku G, Mohan G, Samuelson S et al: Percutaneous aspiration versus catheter drainage of liver abscess: A retrospective review. *Australas Med J*, 2015; 8(1): 7–18
12. Trangbæk RM, Arnesen RB, Støckel M: [Laparoscopy-guided liver abscess drainage of multiple large formations]. *Ugeskr Laeger*, 2015; 177(3): pii: V07140421 [in Danish]